

Case Report

Whether can Posner-Schlossman syndrome be treated through a physiotherapy, ciliary muscle training method?

Wei Zhou¹, Xiaoyan Zhang^{2,*}

¹Department of Pharmaceutical Analysis, School of Pharmacy, Guizhou Medical University, Guiyang 550025, China; ²Department of Pharmacology, School of Basic Medical Sciences, Guizhou Medical University, Guiyang 550025, China

ABSTRACT

A new physiotherapy named Ciliary Muscle Training method and one successful case had been reported first for treatment of Posner-Schlossman Syndrome (PSS), also known as Glaucomatocyclitic Crisis. When a person observed a back and forth moving object, the ciliary muscle would involuntarily do sometimes tense and sometimes relaxant exercise which can relieve the tensile state of the ciliary muscle of patients suffering PSS disease. Through this period of continued treatment, this ciliary muscle training method can improve the health status of the ciliary muscle and finally achieve the purpose of curing PSS disease. In this successful case, the patient's feedback result was very good after receiving our suggested ciliary muscle training method as an attempt to treat PSS, ill right eye of this PSS patient showed normal appearance without any differences from the other normal eye, his vision test values of naked eye were both 4.9 under nearly 200 degrees of myopia. High intraocular pressure (IOP) was mitigated, measured IOP value was in the normal (≤ 21 mmHg) and comfortable state without PSS relapse until now. Therefore, ciliary muscle training method could be a potential clinical treatment approach to PSS disease.

Keywords ciliary muscle training method, Posner-schlossman syndrome, glaucomatocyclitic crisis, Keratic precipitates

We hereby reported a new therapeutical concept — Ciliary Muscle Training method as a physiotherapy for treatment of Posner-Schlossman Syndrome (PSS) in the first time and one successful PSS case under this renewing treatment concept. As you known, PSS as a kind of stubborn illness, an inflammatory disease in corpus ciliare, an immune self-limiting eye disease was also named Glaucomatocyclitic Crisis (Posner et al., 1948; Shazly et al., 2011; Takusagawa et al., 2011), with developing recurrent episodes of high pressure inside the eye accompanied by mild inflammation, opening anterior chamber of the eye and a small amount of white keratic precipitates (KPs). The underlying cause of PSS was unknown. During the onset of the disease, topical application of corticosteroid eye drops or non-steroidal anti-inflammatory drugs (NSAIDs) was to control inflammation development by reducing the inflammatory component—prostaglandins, high intraocular pressure (IOP) as an obvious side symptom arised when the normal drainage mechanism of fluid from the eye became compromised, requiring antiglaucoma drugs such as oral carbonic anhydrase inhibitors for lowering IOP in the initial stages of the attack (Fig. 1), the combination of NSAIDs and antiglaucoma drugs also avoids potential IOP elevations caused by steroids in steroid-responsive patients. Repeated episodes of elevated intraocular pressure can cause long-term sequelae such as glaucoma. A visual field test of the side or peripheral vision may be performed after the acute episode has been controlled

to determine if any damage has been done to the optic nerve because of the high eye pressures, intermittent high IOP of PSS almost didn't damage the optic nerve. Occasionally PSS may be mistaken for angle closure glaucoma (a non-uveitic condition characterized by a sudden increase in eye pressure due to blockage of fluid drainage (Green, 2007; <http://www.zgsyyy.cn/shownews.asp?ArticleID=6293>). Blood-aqueous barrier is a natural physiological barrier, which would cause poor medication effect. The surgery treatment as currently another effective method (Campana et al., 2015; Shimizu et al., 2014), similar to curing primary glaucoma, also can't prevent PSS's recurrence, PSS disease should be closely observed and long-term follow-up.

So, was there other more suitable therapeutic method for PSS? Doctor Wenru Zhao from National Rehabilitation Hospital (China) first invented ciliary muscle training method for curing Chinese juvenile myopia in the past few decades (http://www.rehabi.com.cn/ch/reader/view_abstract.aspx?file_no=20080219&flag=1, <http://www.pmph.com/books/18381.shtml>), the cure rate of juvenile myopia was 49% in ciliary muscle training group and 98% myopic subjects felt a certain degree of curative effect. This therapeutic concept aroused our deep thinking: whether can PSS be treated through this ciliary muscle training method? There really existed exercise therapy for curing and resisting disease invasion in our real life. Of course, this principle also applied to the situation we had here, the object being observed was done a slow rhythmic back and forth movement in a certain period, when a person observed this moving object with his eyes, his ciliary muscle responsible for regulation of eye flexor system would involuntarily do sometimes tense and sometimes relaxant exercise which can relieve the state of tension or spasm of the ciliary muscle in the disease state. After the patient could persistently adhere to the

*Correspondence: Xiaoyan Zhang

E-mail: drxyzhang@126.com

Received September 21, 2015; **Accepted** November 16, 2015;

Published November 30, 2015

doi: <http://dx.doi.org/10.5667/tang.2015.0028>

© 2015 by Association of Humanitas Medicine

This is an open access article under the CC BY-NC license.

(<http://creativecommons.org/licenses/by-nc/3.0/>)

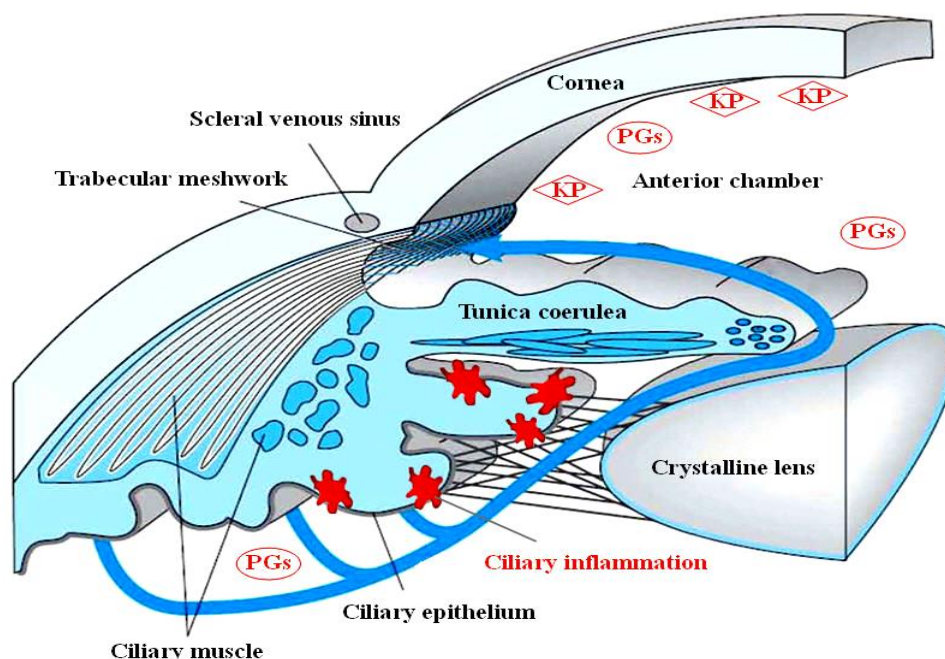


Fig.1 Schematic diagram of aqueous humor circulation and high IOP caused by ciliary inflammation of PSS.

above-mentioned exercise and tense adjustment for a certain time, the therapeutic effect would be significant. Ciliary muscle training method can improve the health status of the ciliary muscle, and ultimately achieved the purpose of curing PSS disease. In our friends, there was accidentally a young male patient who had diagnosed as PSS, suffered PSS with 4 to 5 times of relapse/year for 16 years since his late adolescence. He did not report any systemic disorders and several common viral venereal diseases. And familial diseases such as glaucoma or corneal dystrophy were also denied. Slit lamp examination showed four main mutton-fat KPs in the right eye. No specific iris abnormalities were noted, and the posterior segment was also unremarkable. Gonioscopy revealed open-angle without any peripheral anterior synechiae. Standard achromatic automated perimetry (SAP) showed no field defect.

According to his narration about encountered PSS recurrence, a most perceivable symptom to other people was a certain degree of hyperemia in the logades of his right eye, a markedly-elevated IOP about 35 mm Hg and consequent temporary vision descent hidden to others. But his suffering symptoms mentioned-above always lasted for one to two weeks, and then automatically relieved and disappeared later without medications during the recurrence period. The patient also would be very upset during this time, he had tried the best to therapy this disease by classical chemotherapy such as dexamethasone, timolol/dorzolamide, tobramycin & dexamethasone eye drops (tobradex), traditional Chinese medicine such as peripateticism pill, Longdan Xiegan decoction, Xiaocaihu decoction, medicated wine, eye cold compress and physical exercise in turn, but all ended in failure while PSS relapsed again. In this case, I gave our suggestion to him as an attempt under assistance of Ou Ou eye protection device (<http://www.ooyby.com/>). Unexpectedly, his feedback result was very good since he accepted our advised ciliary muscle training method for PSS treatment for 8 weeks, the ill right eye showed normal appearance without any difference from the other one normal eye, his vision test values of naked eye result were 4.8 (right) / 4.9 (left) using standard visual acuity chart, whose both eyes suffered nearly 200 degrees of myopia, the IOP had constantly been remained 21 (right) / 18

(left) mm Hg in the normal and comfortable state without blurred vision and PSS relapse so far, slit lamp examination still showed mutton-fat KPs in the right eye. This patient would like insist on this new curative method for PSS treatment later, we would also pay close attention to changes in his condition in the future.

We believed this successful case of curing stubborn PSS was a good case, this paper was aimed to report to ophthalmologists and related experts for much wider range of clinical applications of this physiotherapy, ciliary muscle training method, which can help patients who were always suffering from PSS disease.

ACKNOWLEDGEMENTS

We were very grateful to Doctor Wenru Zhao for giving us the academic guidance of ciliary muscle training method. This work was supported by National Innovation and Entrepreneurship Training Project for College Students, China (Grant No. 201410660004), "Western Light" Visiting Scholar Fund of Organization Department of the CPC Central Committee, China (2014~2015), Doctoral Fund of Guizhou Medical University (Grant No. J[2014]006, 2013-03).

CONFLICT OF INTEREST

The authors have no conflicting financial interests.

REFERENCES

- Campana F, Caramello G, Dallorto L, Rolle T. Long-term efficacy of deep sclerectomy in Posner-Schlossman syndrome. *BMJ Case Rep*. 2015. [Epub ahead of print]
- Green RJ. Posner-Schlossman syndrome (glaucomatocyclitic crisis). *Clin Exp Optom*. 2007;90:53-56.

Posner A, Schlossman A. Syndrome of unilateral recurrent attacks of glaucoma with cyclitic symptoms. Arch Ophthal. 1948;39:517-535.

Shazly TA, Aljajeh M, Latina MA. Posner-Schlossman Glaucomatocyclitic Crisis. Semin Ophthalmol. 2011;26:282-284.

Shimizu A, Maruyama K, Yokoyama Y, Tsuda S, Ryu M, Nakazawa T. Characteristics of uveitic glaucoma and evaluation of its surgical treatment. Clin Ophthalmol. 2014;8:2383-2389.

Takusagawa HL, Liu Y, Wiggs JL. Infectious Theories of Posner-Schlossman Syndrome. Int Ophthalmol Clin. 2011;51:105-115.