

## 세포교정영양요법(OCNT)를 이용한 흑색 극세포증 환자 사례 연구

김숙현 약학박사

경기도 부천시 부일로571번길 54(소사동) 우리성모약국

## A Case Study on Patients with Acanthosis Nigricans Receiving Ortho-Cellular Nutrition Therapy (OCNT)

Doctor of Pharmacy, Sook-hyun Kim

Woori St. Mary's Pharmacy, 54, Buil-ro 571beon-gil, Bucheon-si, Gyeonggi-do, Republic of Korea (Sosa-dong)

## ABSTRACT

**Objective:** A case report on the improvement of patients with acanthosis nigricans by Ortho-Cellular Nutrition Therapy (OCNT).

**Methods:** A 23-year-old Korean male who has begun to have the symptoms of acanthosis nigricans two years ago has been experiencing more severe symptoms in the past year.

**Results:** Skin pigmentation and lichenification symptoms improved after Ortho-Cellular Nutrition Therapy (OCNT).

**Conclusion:** Ortho-Cellular Nutrition Therapy (OCNT) is effective in relieving the symptoms of patients with acanthosis nigricans.

**Keywords** Ortho-Cellular Nutrition Therapy (OCNT), Acanthosis nigricans, Skin pigmentation, Lichenification, Insulin resistance, and Obesity

## Introduction

Acanthosis nigricans refers to a disease that occurs in foldable body parts, such as the neck, armpits, the front of the elbow, or the back of the knee. It is characterized by a symmetrical shape, black or gray coloring of the skin, and thickening of the skin. They cause wrinkles, papillomatosis, or hyperkeratosis on the skin.<sup>1</sup> The exact cause of acanthosis nigricans is not known, but it is known

that insulin plays a significant role in its development. The disease often appears in obese people, in which case it is known to result in an insulin resistance (IR) state. In addition to insulin resistance, the disease is rarely associated with malignant tumors mainly in the abdomen; gastric cancer is the most common case. In addition, it rarely occurs even after taking medications such as oral contraceptives, hormones, etc., but there are cases in which a specific cause cannot be found. Moderate concentrations of insulin play a role in regulating carbohydrate, fat, and protein metabolisms, but high concentrations of insulin are combined with insulin-like growth factor 1 receptors (IGF-1Rs). IGF-1Rs show high-affinity insulin with 100- to 1000-fold, resulting in acanthosis nigricans by promoting the excessive proliferation of keratinocytes and fibroblasts.<sup>2</sup> Obesity is considered the most common cause of acanthosis nigricans. The symptoms of the disease are commonly observed in adults although it has nothing to do with age. Usually, about half of people whose weight is more than

\*Correspondence: Sook-hyun Kim

E-mail: [truelovetrue70@naver.com](mailto:truelovetrue70@naver.com)

Received Apr 28, 2023; Accepted Apr 28, 2023; Published Apr 28, 2023

doi: <http://dx.doi.org/10.5667/CellMed.spc.017>

©2023 by CellMedOrthocellular Medicine Pharmaceutical Association

This is an open access article under the CC BY-NC license.

(<http://creativecommons.org/licenses/by-nc/3.0/>)

† This report has been translated and edited by the CellMed editor-in-chief, Prof. Beom-Jin Lee.

200% of their ideal body weight have acanthosis nigricans. As there is a correlation between the symptoms of the disease and body weight, if the weight is lost, the symptoms of the disease are also reduced. It has been reported that those who have the symptoms of acanthosis nigricans in childhood have a high risk of developing diseases such as obesity, hypertension, hyperinsulinemia, IR, and type 2 diabetes.<sup>3</sup> Thus, obesity can be used as an indicator of IR, but acanthosis nigricans is not an exclusive marker of obesity and excess insulin levels. IR is a kind of a metabolic disorder requiring a response to insulin in order for cells to use blood sugar. However, if that function is not performed, the concentration of insulin in the blood and the level of blood sugar cannot be maintained in a normal state. This leads to endothelial dysfunction and adversely affects subcellular signaling pathways, such as the PI-3-kinase/Akt pathway, which may lead to the development of cardiovascular diseases. In addition, it has been reported that IR can cause metabolic syndrome by increasing blood triglycerides.<sup>4</sup> In the treatment of acanthosis nigricans, weight loss is effective, and various methods, such as topical/oral agents, cosmetic surgery, etc., are used for its treatment. The patient of this case, who is obese with fatty liver, has been suffering from acanthosis nigricans for several years. It was intended to report the progress of dermal therapy applied to the male patient who had thick skin and deep wrinkles due to skin pigmentation around the neck and abnormal proliferation of skin cells.

## Case

### 1. Target

The subject of this case study was one patient with acanthosis nigricans.

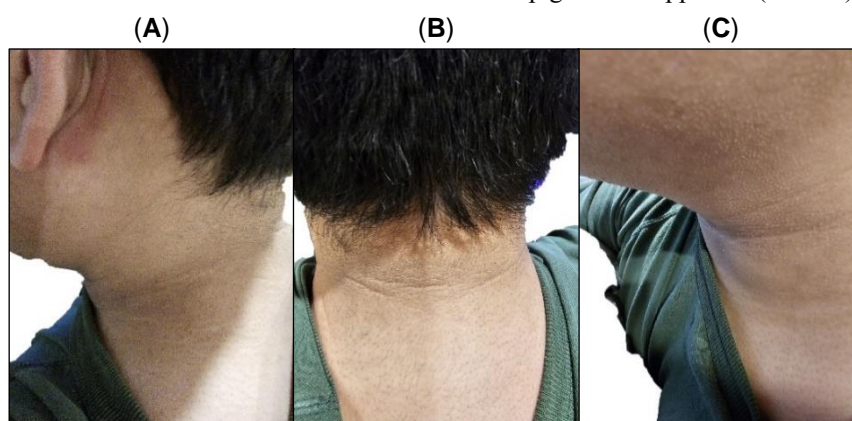
- 1) Name: Choi O O (M/23 years old)
- 2) Diagnosis: Insulin resistance / acanthosis nigricans
- 3) Date of onset: 2021
- 4) Treatment period: March 9, 2023 to present
- 5) Chief complaint: The entire skin around the patient's neck turned black as it became thick with deep wrinkles.
- 6) Medical history: Fatty liver. Obesity with a height of 170cm and a weight of 90kg.
- 7) Social history: No smoking and drinking
- 8) Family medical history: Hypertension from the maternal line and hyperlipidemia
- 9) History of present illness: None

### 2. Methods

The male patient did not combine exercise and diet, but he applied an appropriate amount of Sulfoplex Cream Mild (001, 1 time a day) to the affected area once a day.

## Results

The male patient found that all the skin around his neck was heavily pigmented and became thicker than normal skin. In particular, the back of the neck, where the symptoms were the most severe, turned black. He applied an appropriate amount of Sulfoplex Cream Mild to the affected area once a day. As a result of its application to the affected skin for about a month, the color of the most severely pigmented skin at the back of the neck seemed to become lighter (Figure 1). In addition, the patient felt that the thickened skin had become softer compared to before. And, the patient's thick wrinkles became much blurred, and the skin border between his neck and back disappeared as much of the black pigment disappeared (Table 1).



**Figure 1.** Photos of a patient whose symptoms improved after Ortho-Cellular Nutrition Therapy (OCNT) for one month (A) Skin pigmentation (B) Lichenification, and (C) Wrinkle

**Table 1.** An indicator of the patient's symptoms. That means the symptoms are getting worse on a scale of 1 to 5.

Factor	Mar. 7	Apr. 7	Apr. 15
Skin pigmentation	5	2	1
Lichenification	5	2	2
Wrinkle	5	3	3

SBP; systolic blood pressure, DBP; diastolic blood pressure

### Considerations

The patient of this case who has severe obesity with a high BMI index is highly likely to have IR and has had the symptoms of acanthosis nigricans for three years. The skin around the patient's neck has turned black, and the abnormal proliferation of cells is thought to have irritated his skin, making him to complain of itching. It caused microscopic scars on the patient's skin, and tissue thickening (defence mechanism) and lichenification around the neck appeared to have occurred due to skin fibrosis. In addition, the patient requires proper treatment because papillomatosis seems to have spread to and around the affected area. It aimed to make a report on the progress of applying Sulfoplex Cream Mild to the skin, considering that the patient had a very busy life and had difficulty devoting more time to losing weight with diet management. Cyanidin contained in Sulfoplex Cream Mild is reported to have excellent antioxidant and anti-inflammatory effects or to protect cells from active oxygen.<sup>5</sup> Centella asiatica, which has been used as a medicinal herb in China since ancient times, has been also actively studied in modern times. In particular, the triterpenoids contained in the extracts has been known through in vivo and in vitro tests that it has various functions in the treatment of acne, hair loss, burns, vitiligo, and atopy, in the regeneration of skin and tongue, etc.<sup>6</sup> Anemarrhena asphodeloides, which has pharmacological effects on the nervous and blood systems, is a medicinal herb that has been documented to be used for nearly a thousand years in Korea, Japan and China and contain a variety of bioactive substances such as steroidal saponins, flavonoids, phenylpropanoids, alkaloids, steroids, organic acids, and anthraquinones.<sup>7</sup> It is reported to have anti-tumor, anti-oxidation, anti-microbial, anti-virus, anti-inflammation, anti-osteoporosis, and anti-aging properties while protecting the skin from damage, etc. As this case

study is based on a single instance of data obtained during a short treatment period, it cannot be applied universally to all patients, but it is thought to be a case of improving the patient's acanthosis nigricans. Therefore, this case study is reported with the patient's prior consent.

### References

- 1 Phiske, M. M. An approach to acanthosis nigricans. *Indian Dermatol Online J* **5**, 239-249, doi:10.4103/2229-5178.137765 (2014).
- 2 Jeong KH, O. S., Chon S, Lee MH. Generalized acanthosis nigricans related to type B insulin resistance syndrome: A case report. *Cutis* **86**, 299-302 (2010).
- 3 Fu, J., Liang, L., Dong, G., Jiang, Y. & Zou, C. J. Z. e. k. z. z. C. j. o. p. Obese children with benign acanthosis nigricans and insulin resistance: analysis of 19 cases. **42**, 917-919 (2004).
- 4 Grundy, S. M. J. T. A. j. o. c. Hypertriglyceridemia, insulin resistance, and the metabolic syndrome. **83**, 25-29 (1999).
- 5 Wang, H. *et al.* Antioxidant and antiinflammatory activities of anthocyanins and their aglycon, cyanidin, from tart cherries. *J Nat Prod* **62**, 294-296, doi:10.1021/np980501m (1999).
- 6 Sun, B. *et al.* Therapeutic Potential of Centella asiatica and Its Triterpenes: A Review. *Front Pharmacol* **11**, 568032, doi:10.3389/fphar.2020.568032 (2020).
- 7 Wang, Y. *et al.* The genus Anemarrhena Bunge: A review on ethnopharmacology, phytochemistry and pharmacology. *J Ethnopharmacol* **153**, 42-60, doi:10.1016/j.jep.2014.02.013 (2014).