

## 세포교정영양요법(OCNT)을 이용한 탈모 개선 사례 연구

김기원 약사

경기도 고양시 일산서구 중앙로1559 (대화동) 대화동시티타워 103호 대화약국

## A Case Study on the Improvement of Hair Loss Using Ortho-Cellular Nutrition Therapy (OCNT)

Pharmacist, Ki-won Kim

Daehwa Pharmacy, #103, City Tower, 1559, Jungang-ro, Ilsanseo-gu, Goyang-si, Gyeonggi-do, Republic of Korea (Daehwa-dong)

## ABSTRACT

**Objective:** A case report on the improvement of bald crown by Ortho-Cellular Nutrition Therapy (OCNT).**Methods:** A 61-year-old Korean male suffering from bald crown, male pattern baldness, and reduced hair thickness**Results:** Bald crown improved after Ortho-Cellular Nutrition Therapy (OCNT).**Conclusion:** Ortho-Cellular Nutrition Therapy (OCNT) is effective in relieving the symptoms of hair loss patients.**Keywords** Ortho-Cellular Nutrition Therapy (OCNT), Hair loss, and Hair thickness

## Introduction

The skin, the second largest organ in the body, is composed of ectoderm and mesoderm, and hair follicles are generated from the two germ layers. Hairs from hair follicles are an important factor in the survival of mammals because they protect the skin from external stimuli and ultraviolet rays.<sup>1</sup>

Hair loss refers to the permanent hair loss without being able to exist normally after the gradual thinning of the hair with a progressive pattern. It is assumed that hair loss is

caused by various causes such as genetic causes, lack of food, fever, intake of medicines, exposure to heavy metals, etc. According to a study on 5,531 Korean men, it appears that more than 30% of men in their 40s and 50s suffer from hair loss which is also increasing especially in young men.<sup>1,3</sup>

Hair loss usually seen in men is called androgenetic alopecia (AGA), which is known that it accounts for about 80% of male hair loss. The progress rate of male hair loss varies depending on individual characteristics and racial differences. Usually, the types of hair loss, the frontal hairline and ludwig pattern, are most common in Asians. Frontal hairline refers to the loss of hair on the forehead in the M-shape while ludwig-patterned hair loss usually occurs in women and means that the hair becomes thinner and then intensifies at the top of the head.<sup>2</sup> The male hormone testosterone is the main circulating androgen and is converted to androgens DHT by 5 $\alpha$ -reductase (5 $\alpha$ R) when it reaches the skin. It is known that hair loss patients have high concentrations of DHT and secrete high amounts of androgens, and the androgens decrease the

\*Correspondence: Ki-won Kim

E-mail: lion3485@hanmail.net

Received Apr 28, 2023; Accepted Apr 28, 2023; Published Apr 28, 2023

doi: <http://dx.doi.org/10.5667/CellMed.spc.019>

©2023 by CellMed Orthocellular Medicine Pharmaceutical Association

This is an open access article under the CC BY-NC license.

<http://creativecommons.org/licenses/by-nc/3.0/>

† This report has been translated and edited by the CellMed editor-in-chief, Prof. Beom-Jin Lee.

expression of growth factors, such as IGF-1, bFGF, and VEGF that sustain the anagen of hair follicles, while increasing the expression of IL-1, TNF- $\alpha$ , and TGF- $\beta$  that accelerate the catagen of hair follicles. In addition, active oxygen generated from aging, smoking, ultraviolet rays, environmental pollution, etc., which can cause chronic inflammatory reactions, can also adversely affect hair follicles.<sup>4</sup>

A variety of drugs are being developed for the treatment of hair loss, and other treatment methods, such as laser, etc., are also being used in parallel. However, when there are complex causes of hair loss, and hormonal agents, such as Dutasteride, Minoxidil, etc., are used, side effects, such as obesity, gynecomastia, breast cancer, lack of libido, erectile dysfunction, etc. occur due to the decrease in male hormones.<sup>1 and 4</sup>

In the atmosphere of Korean society, which values appearance, hair loss patients not only have a negative image, but also lose self-confidence, form negative perceptions of society, and experience anxiety about interpersonal relationships, so improving hair loss is very important from a long-term perspective.<sup>5</sup>

For the patient in this case, the bald crown and fine hair are slowly progressing, and the male pattern baldness has already progressed to a considerable extent. The patient has continued to take the Morangmorang Booster Capsule through consultation for Ortho-Cellular Nutrition Therapy (OCNT). The patient had never had any special diseases or underwent any other procedures and took antihistamines occasionally due to allergic rhinitis. It was intended to report the progress of Ortho-Cellular Nutrition Therapy (OCNT) for the patient who had felt uncomfortable due to hair loss.

## Case

### 1. Target

The subject of this case study was one hair loss patient.

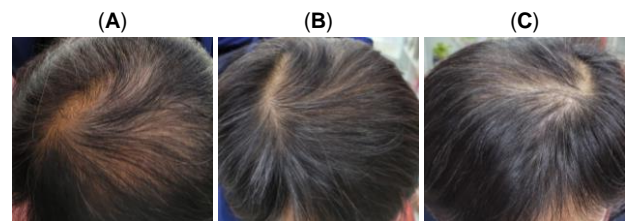
- 1) Name: Kim O O (M/61 years old)
- 2) Diagnosis: Bald crown and fine hair
- 3) Date of onset: October 2022
- 4) Treatment period: October 2022 to present
- 5) Chief complaint: His hair loss, which started with bald crown, is now expanding to male pattern baldness.
- 6) Medical history: None
- 7) Social history: None
- 8) Family medical history: Hair loss inherited from the father's side
- 9) History of present illness: Allergic rhinitis

### 2. Methods

The patient took the Morangmorang Booster Capsule (101, 2 times a day, 1 tablet per time) with water.

### Results

The patient had already a bald crown to some extent before performing Ortho-Cellular Nutrition Therapy (OCNT). Therefore, the density of the patient's hair was reduced, and the thickness of his hair was also thin (Figure 1A). After about three months of taking the Morangmorang Booster Capsule, the patient's hair not only became thicker but also began to shine (Figure 1B). After about six months of receiving Ortho-Cellular Nutrition Therapy (OCNT), the hair density of the patient's top of the head increased significantly compared to before. In addition, even with naked eyes, the area of the scalp seen by hair loss was reduced (Figure 1C).



**Figure 1.** Changes in the symptoms of the hair loss patient receiving Ortho-Cellular Nutrition Therapy (OCNT) over time (A) Hair condition of the patients before receiving Ortho-Cellular Nutrition Therapy (OCNT) (B) Hair condition of the patients after three months of receiving Ortho-Cellular Nutrition Therapy (OCNT) (C) Hair condition of the patients after six months of receiving Ortho-Cellular Nutrition Therapy (OCNT)

### Considerations

Since hair loss is not accompanied by pain, most of hair loss patients start receiving medical treatment after the disease has progressed to some extent. If appropriate treatment is not performed in time, about 5% of the total amount of the hair is lost each year, so it is very important to treat hair loss promptly.<sup>6</sup> Currently, there is topical minoxidil as a treatment method for male androgenetic alopecia. Minoxidil was originally used to treat hypertension as a vasodilator. However, It has been shown to promote hair regrowth as well as prevent hair loss when

being prescribed to hair loss patients.<sup>7</sup> The horse placental extract contained in the Morangmorang Booster Capsule contains the active ingredient, growth promoter (PIGF). It has been reported through in vivo/in vitro tests that PIGF forms hair follicles and expands capillaries similar to the efficacy of minoxidil.<sup>8</sup> and <sup>9</sup> And, the Morangmorang Booster Capsule contains L-methionine, a nutrient required for the production of hair and nails, which is necessary for the metabolism of L-cystine, an essential amino acid.<sup>10</sup> In addition, it contains Vitamin B, which can cause hair loss when it is deficient in the body.<sup>11</sup> It is known that Methyl Sulfonyl Methane (MSM), one of the main ingredients, induces the synthesis of collagen, a component of hair and nails.<sup>12</sup>

As this case study is targeted for one patient and determines the symptoms only with the naked eyes, it cannot be applied universally to all patients. However, Traditional hair loss treatments have the risk of causing side effects, so new approaches to treat hair loss are needed. From this point of view, the application of Ortho-Cellular Nutrition Therapy (OCNT) to hair loss patients can be an alternative for treating hair loss, so it is thought that more active research activities need to be conducted. Therefore, this case study is reported with the patient's prior consent.

## References

- 1 Hong, S.-S. J. B. o. F. T. Hair biology and effluvium. **22**, 651-663 (2009).
- 2 York, K., Meah, N., Bhoyrul, B. & Sinclair, R. J. E. o. o. p. A review of the treatment of male pattern hair loss. **21**, 603-612 (2020).
- 3 Paik, J. H., Yoon, J. B., Sim, W. Y., Kim, B. S. & Kim, N. I. J. B. J. o. D. The prevalence and types of androgenetic alopecia in Korean men and women. **145**, 95-99 (2001).
- 4 Rossi, A. *et al.* Multi-therapies in androgenetic alopecia: Review and clinical experiences. **29**, 424-432 (2016).
- 5 Kim, D.-H. & Kim, S.-N. J. K. J. A. C. The effect on hair loss for impression formation and interpersonal anxiety. **8** (2010).
- 6 Rushton, D., Ramsay, I., Norris, M., Gilkes, J. J. C. & dermatology, e. Natural progression of male pattern baldness in young men. **16**, 188-192 (1991).
- 7 Savin, R. C. J. J. o. t. A. A. o. D. Use of topical minoxidil in the treatment of male pattern baldness. **16**, 696-704 (1987).
- 8 Yoon, S.-Y. *et al.* A role of placental growth factor in hair growth. **74**, 125-134 (2014).
- 9 Cianfarani, F. *et al.* Placenta growth factor in diabetic wound healing: altered expression and therapeutic potential. **169**, 1167-1182 (2006).
- 10 Hertel, H. *et al.* Low dosage retinol and L-cystine combination improve alopecia of the diffuse type following long-term oral administration. **40**, 490-495 (1989).
- 11 Almohanna, H. M., Ahmed, A. A., Tsatalis, J. P., Tosti, A. J. D. & therapy. The role of vitamins and minerals in hair loss: a review. **9**, 51-70 (2019).
- 12 Dalle Carbonare, L. *et al.* Methylsulfonylmethane enhances MSC chondrogenic commitment and promotes pre-osteoblasts formation. **12**, 1-12 (2021).