

## 세포교정영양요법(OCNT)을 이용한 탈모 환자 개선 사례 연구

박정미 약사

경기도 부천시 성주로 267 메디팜비타민약국

## A case study on the use of Ortho-Cellular Nutrition Therapy (OCNT) in patients with alopecia

Pharmacist, Jungmee Park

Medipharm Vitamin Pharmacy, 267 Seongju-ro, Bucheon-si, Gyeonggi-do

## ABSTRACT

**Objective:** A case study on improvement of alopecia through OCNT.**Methods:** 62-year-old woman suffering from alopecia symptoms and thinning hair due to stress and overwork after her marriage.**Results:** Hair got thicker following the implementation of nutrition therapy with improvement of alopecia symptoms at the crown and lateral aspects of the head.**Conclusion:** Nutrition therapy can be helpful in promoting hair growth and increase in hair thickness for patients displaying alopecia symptoms.**Keywords:** Ortho-Cellular Nutrition Therapy (OCNT) and alopecia

## Introduction

Alopecia can be classified into the disorder for which hair follicle is damaged and disorder for which hair follicle is normal, but the growth cycle of hair is abnormal. Other disorders

include alopecia areata, telogen alopecia, cicatricial alopecia, traumatic alopecia and masculine alopecia. Among these, the masculine alopecia is the most common cause of feminine alopecia.<sup>1</sup> Alopecia can manifest at any age following adolescence with the frequency increasing with increase in the age of the patient. Clinically, it starts with thinning of the hair at the center of scalp and the hairline at the forehead is generally maintained.<sup>2</sup> Although alopecia can manifest at any parts of

\*Correspondence: Jungmee Park

E-mail: lemon2201@naver.com

Received Oct 30, 2023; Accepted Oct 30, 2023; Published Oct 31, 2023

doi: <http://dx.doi.org/10.5667/CellMed.spc.050>

©2023 by CellMed Orthocellular Medicine Pharmaceutical Association

This is an open-access article under the CC BY-NC license. (<http://creativecommons.org/licenses/by-nc/3.0/>)

† This report has been translated and edited by the CellMed editor-in-chief, Prof. Beom-Jin Lee.

the body, manifestation in scalp is most painful and stressful. Masculine alopecia is characterized by thinning of hair along with alopecia symptoms. In particular, when it manifests in female, it imparts negative effects from the emotional perspectives including discontentment and embarrassment on external appearance as well as helplessness in not being able to stop alopecia.<sup>3,4</sup> In this case, progresses of alopecia symptoms and thinning hair after having implemented nutrition therapy on a 62-year-old female with high blood pressure, thinning hair and alopecia symptoms will be examined.

## **Case**

### **1. Subject**

1 case of patient diagnosed with alopecia was selected for the study.

- 1) Name: Jang, O O (F/62 years old)
- 2) Name of diagnosis: Alopecia and thin hair
- 3) Date of manifestation: After marriage
- 4) Treatment period: October 2022 ~ August 2023 (approximately 10 months)
- 5) Main symptoms: Severe alopecia, and thin and crumply hair
- 6) Current medical history and medicine administered: Currently taking medicine for high blood pressure

### **2. Method**

Nutrition therapy was implemented as follows to alleviate the alopecia symptoms.

#### **- Cyaplex Scalp Revitalizing Shampoo**

After having wetted the scalp with lukewarm water, lightly remove contamination first. At the time of the second shampooing, massage the scalp and then wash off with water 5 minutes later.

#### **Cyaplex Scalp Care Tonic**

- After shampooing, spray evenly throughout the scalp and allow it to be absorbed by massaging it in.

Morangmorang Booster Capsule (101, 1 capsule at a time for 2 times a day)

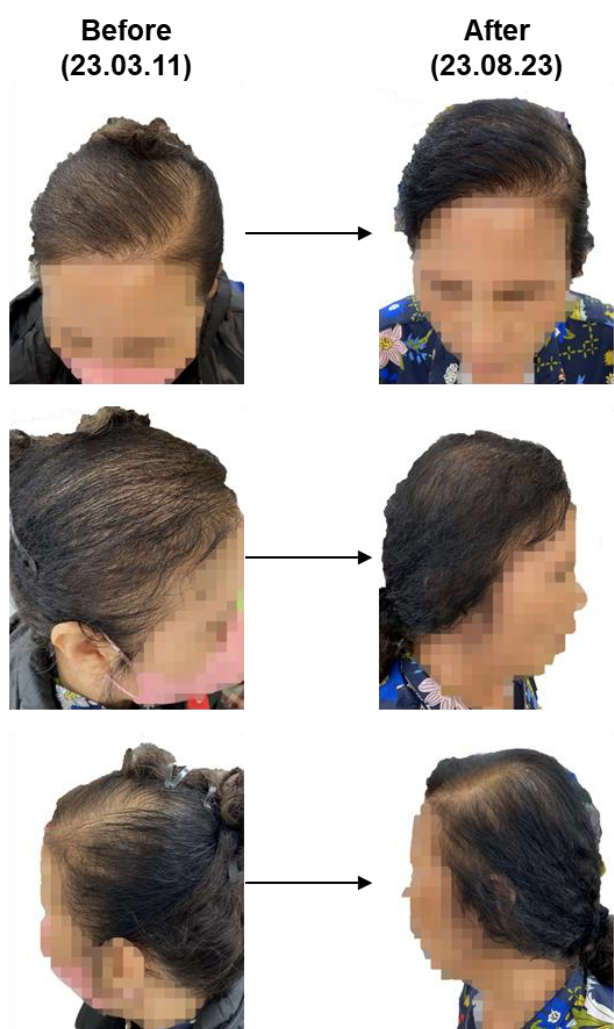
Vivagin X Capsule (101, 1 capsule at a time for 2 times a day)

Implementation of OCNT began in the aforementioned method.

## **Results**

The alopecia symptoms of the patient began to be manifested gradually due to severe stress and overwork following her marriage and alopecia appeared to have progressed significantly due to absence of appropriate management and prescription. Hair was very thin and crumply without luster, and there was a lot of heat in the scalp. In addition, the patient was covering the extensive exposure of scalp due to alopecia symptoms with frequent perming of the hair. Cyaplex Scalp Tonic was used since October 2022 to reduce the heat in her scalp and Cyaplex Scalp Revitalizing Shampoo was applied directly onto the scalp. Although definitive effects did not manifest for

approximately 3 months after the commencement of nutrition therapy, it was possible to feed the thickening of the hair in August 2023 in comparison to the condition in March 2023 along with the scalp in the crown and lateral aspects of the head that was previously exposed began to be filled with new hair as the result of having continuously implemented nutrition therapy with patience (Fig. 1).



**Fig. 1. Changes in alopecia symptoms with passage of time before and after the nutrition therapy.**

### **Considerations**

Alopecia is considered to be a very common disorder and it was disclosed that there is no correlation between sex hormone and alopecia in the population-based study. Although the cause of alopecia is thought to be induced by male hormone nowadays, with the exclusion of the low level of dehydroepiandrosterone sulphate in male with alopecia, no meaningful correlation was displayed for total testosterone.<sup>5</sup> In this case, nutrition therapy was implemented to a patient with hair that continuously thinned and alopecia symptoms for more than 30 years. Compositional ingredients of Vivagin X Capsule include 156 nature-derived ingredients with immune and antioxidation functions that supply nutrients to the scalp and play the role of booster that follicular cell division through supplying of iron.<sup>6</sup> Compositional ingredients of Morangmorang Capsule include biotin, manganese and vitamin B6, etc., which are nutrients essential for synthesis of hair and fingernail.<sup>7</sup> In addition, it contains vitamin B group that can induce alopecia by damaging hair in the event of their deficiency.<sup>8</sup> A growth promotion factor (PIGF), which is an active ingredient of horse placenta extract, contained in Cyaplex Scalp Care Tonic is reported to have functions including formation of hair follicle and strengthening of capillary vessels.<sup>9,10</sup> Methyl Sulfonyl Methane (MSM) makes hair stronger by inducing synthesis of collagen,

which is a compositional ingredient of hair and fingernail.<sup>11</sup> Menthol included in Cyaplex Scalp Revitalizing Shampoo is obtained from peppermint oil or other mint oils, or through synthesis, and provides assistance with the functions including growth and development of hair and strengthening of hair follicle.<sup>12</sup>

The patient in this case is in her old age and the functions of hair follicle is substantially degraded due to declined metabolism and aging of cells. Accordingly, it is thought that there exist limitations in personal opinion and interpretation in visually observing the density of hair rather than measurement of the formation of hair follicle and thickness of hair, and observation of scalp cells.

Treatment is being continued by proposing solution with focus on treating the cells through application of such treatment approach for alopecia symptoms and it is deemed that the burden on the patient regarding the side effects of the drug would be relatively low.

This case is being reported by having acquired the consent of the patient.

## Reference

- 1 Thiedke CC. Alopecia in women. *Am Fam Physician*. 2003;67(5):1007-1014.
- 2 Starace M, Orlando G, Alessandrini A, Piraccini BM. Female Androgenetic Alopecia: An Update on Diagnosis and Management. *Am J Clin Dermatol*. 2020;21(1):69-84.
- 3 Cash TF, Price VH, Savin RC. Psychological effects of androgenetic alopecia on women: comparisons with balding men and with female control subjects. *J Am Acad Dermatol*. 1993;29(4):568-575.
- 4 Girman CJ, Hartmaier S, Roberts J, Bergfeld W, Waldstreicher J. Patient-perceived importance of negative effects of androgenetic alopecia in women. *J Womens Health Gend Based Med*. 1999;8(8):1091-1095.
- 5 Kische H, Arnold A, Gross S, et al. Sex Hormones and Hair Loss in Men From the General Population of Northeastern Germany. *JAMA Dermatol*. 2017;153(9):935-937
- 6 Almohanna HM, Ahmed AA, Tsatalis JP, Tosti A. The Role of Vitamins and Minerals in Hair Loss: A Review. *Dermatol Ther (Heidelb)*. 2019;9(1):51-70.
- 7 Hertel, H., Gollnick, H., Matthies, C., Baumann, I. & Orfanos, C. E. [Low dosage retinol and L-cystine combination improve alopecia of the diffuse type following long-term oral administration]. *Hautarzt* **40**, 490-495 (1989).
- 8 Almohanna, H. M., Ahmed, A. A., Tsatalis, J. P. & Tosti, A. The Role of

Vitamins and Minerals in Hair Loss: A Review. *Dermatol Ther (Heidelb)* **9**, 51-70.

- 9 Failla CM, Odorisio T, Cianfarani F, Schietroma C, Puddu P, Zambruno G. Placenta growth factor is induced in human keratinocytes during wound healing. *J Invest Dermatol*. 2000;115(3):388-395.
- 10 Yoon, S. Y. et al. A role of placental growth factor in hair growth. *J Dermatol Sci* 74, 125-134.
- 11 Ha SH, Choung PH. MSM promotes human periodontal ligament stem cells differentiation to osteoblast and bone regeneration. *Biochem Biophys Res Commun*. 2020;528(1):160-167.
- 12 Oh, J. Y., Park, M. A. & Kim, Y. C. Peppermint Oil Promotes Hair Growth without Toxic Signs. *Toxicol Res* **30**, 297-304.