

## 세포교정영양요법(OCNT)을 이용한 설소대 염증 개선 사례

신수정 약사

대구광역시 북구 동변동 682 금강약국

## A Case of Improvement of Lingual Frenulum Inflammation Using Ortho-Cellular Nutrition Therapy (OCNT)

Pharmacist, Soo Jeong Shin

Geumgang Pharmacy, 682, Dongbyeon-dong, Buk-gu, Daegu, Republic of Korea

## ABSTRACT

**Objective:** A case study on improving lingual frenulum inflammation using Ortho-Cellular Nutrition Therapy (OCNT).

**Methods:** OCNT was administered to a woman in her 30s suffering from acute inflammation of the lingual frenulum.

**Results:** Approximately 5 hours after the initiation of OCNT, the redness and swelling of the lingual frenulum and the enlargement of the surrounding lymph nodes were alleviated, and by 10 hours, most discomfort symptoms had significantly improved.

**Conclusion:** OCNT can help alleviate symptoms for patients suffering from lingual frenulum inflammation.

**Keywords:** Ortho-Cellular Nutrition Therapy (OCNT), lingual frenulum inflammation, lymph nodes

## Introduction

The lingual frenulum is a type of mucosal fold attached to the floor of the mouth or the lower jaw. This area is composed of muscle fibers connected to the tongue, and anatomical studies have revealed that proteins such as collagen and elastin also comprise this area.<sup>1</sup> This structure helps keep the tongue in a fixed position and balances its movement during activities such as speaking, eating, and swallowing, which also affects the breastfeeding capability of infants.

Although the lingual frenulum plays a crucial role in the oral mobility of the tongue, various causes can lead to diseases in this area. One example is ankyloglossia, where the lingual frenulum is not properly attached or is too short, restricting movement excessively. This condition can affect speech articulation, eating difficulties, and facial development and is typically treated surgically.<sup>2</sup>

In addition to the aforementioned symptoms, the lingual frenulum region may occasionally feel sore or sensitive. These sensations typically indicate the presence of inflammation or ulcers in the lingual frenulum. When inflammation occurs, it can cause pain, redness, and swelling in the affected area and its

vicinity. The causes of such inflammation are often unclear, but they may include tears due to oral injuries, deficiencies in nutrients, such as vitamin B12, folic acid, and iron, sensitivities to certain foods, and stress.<sup>3</sup>

When inflammation of the lingual frenulum occurs due to various reasons, it is primarily treated with anti-inflammatory medications. However, if the symptoms do not improve or worsen, laser treatments may be used, or oral splints may be employed to prevent further damage.<sup>3,4</sup> Given the variety of treatment methods available, it is crucial to carefully assess the patient's condition and apply appropriate treatment.

The patient in this case suffered from pain due to inflammation in the lingual frenulum, which caused discomfort in the movement of the tongue and mouth. Therefore, OCNT was applied to this patient, which resulted in significant improvement. Thus, this case is reported with the consent of the patient.

## Case Study

## 1. Subject

A case of a one patient with lingual frenulum inflammation was studied.

- 1) Name: Lee OO (31 years old, F)
- 2) Diagnosis: Lingual frenulum inflammation
- 3) Date of onset: October 2024
- 4) Treatment duration: October 2024
- 5) Primary symptoms: Foreign body sensation under the tongue, difficulty opening mouth, numbness of the tongue
- 6) Past Medical History: Seborrheic dermatitis

\*Correspondence: Soo Jeong Shin

E-mail: anlinagood@naver.com

Received Oct 31, 2024; Accepted Oct 31, 2024; Published Oct 31, 2024  
doi: <http://dx.doi.org/10.5667/CellMed.spc.102>

©2024 by CellMed Orthocellular Medicine Pharmaceutical Association  
This is an open access article under the CC BY-NC license.

(<http://creativecommons.org/licenses/by-nc/3.0/>)

† This report has been translated and edited by the CellMed editor-in-chief, Prof. Beom-Jin Lee.

- 7) Social History: Craving for sweet foods
- 8) Family History: None
- 9) Current Medical Condition and Medications: Intermittent use of dermatitis medication due to seborrheic dermatitis.

## 2. Methods

The following OCNT was applied:

One sachet of Sulfoplex F Powder  
One sachet of Notoplex Granules  
One sachet of Lymph Circulation Enhancer

The OCNT was slowly dissolved under the tongue and was taken in conjunction with Aqua SAC Pure, which had been in use previously. The patient was also instructed to continue a diet that avoids dairy, spicy foods, and wheat flour.

## Results

Before OCNT, the lingual frenulum was generally swollen and reddened (Fig. 1A), and swelling of the lymph nodes under the tongue was also observed. Additionally, the patient experienced significant pain, and there was discomfort when speaking or moving the tongue.

Five hours after applying OCNT, the patient reported a significant reduction in the pain and discomfort she was experiencing, and a visible decrease in inflammation was observed upon monitoring the affected area. (Fig. 1B) Ten hours after the initial application of OCNT, the discomfort had completely disappeared, and there was a significant improvement in the redness and swelling compared to the initial state. (Fig. 1C) Additionally, a reduction in the swelling of the lymph nodes under the tongue was observed. The circulation of the sublingual vein was also smoothened.

The degree of discomfort experienced by the patient during OCNT is detailed in Table 1.

## Discussion

The patient, a woman in her 30s, was experiencing sudden under-tongue pain and a foreign body sensation, which caused her discomfort. She also reported discomfort when speaking due

to these symptoms. Moreover, she was advised to consider laser treatment when she visited the hospital due to these symptoms.

After examination, she intermittently developed seborrheic dermatitis and occasionally required medication. Therefore, it was presumed that she was particularly susceptible to inflammation. Significant symptom alleviation was observed in prior applications of OCNT for patients with lingual frenulum irritation among middle and high school students. Therefore, following the same method, OCNT was chosen to reduce inflammation and improve blood flow.

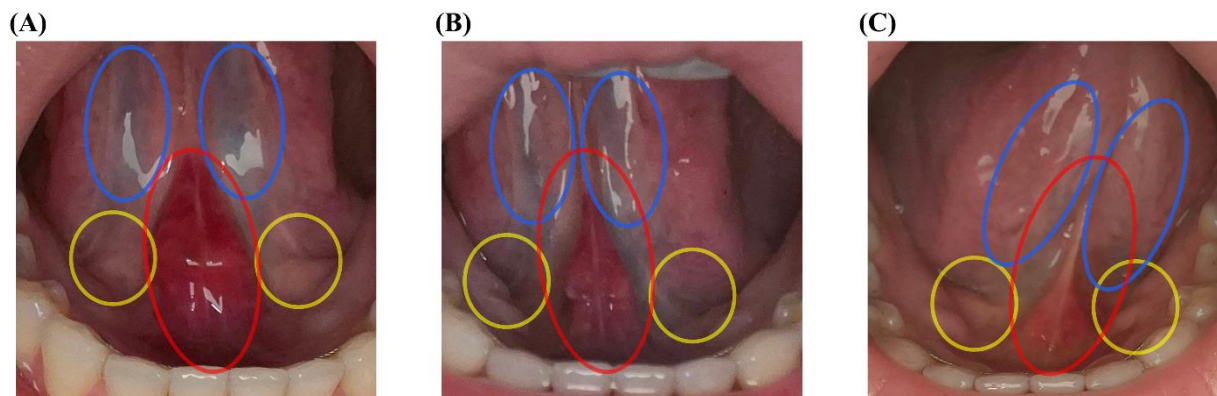
One of the key ingredients in Sulfoplex, methylsulfonylmethane (MSM), inhibits the activity of transcription factors involved in inflammatory signaling, such as NF- $\kappa$ B, Interleukin (IL)-1, IL-6, TNF- $\alpha$ , thus aiding in reducing inflammation. MSM also uses the crosstalk between oxidative stress and inflammatory responses to modulate immune reactions<sup>5</sup> and supplies sulfur to connective tissues, thereby aiding tissue formation and damage prevention.<sup>6</sup> Thus, MSM likely played a crucial role in alleviating the inflammation in the lingual frenulum.

Extracts from the root of *Panax notoginseng*, found in Notoplex, help alleviate inflammation by regulating markers like TLR4, VEGF, and ICAM-1. A study administered this extract to rats with induced chronic obstructive pulmonary disease showed a significant reduction in inflammation around the bronchi and vessels compared with the control group.<sup>7</sup> Ginsenosides, the

**Table 1. Degree of Symptoms Experienced by the Patient during OCNT.** A numerical rating scale was used for the symptom scale, ranging from 0 to 10, where higher values indicate greater discomfort.

Period Symptoms	1st (Before OCNT)	2nd (5 hours later)	3rd (10 hours later)
Lingual frenulum pain, foreign body sensation, and discomfort when speaking.	10	3	0

\* 0: No pain and no discomfort in daily life, 1–4: Mild pain with slight discomfort in daily life, 5–6: Moderate pain with some discomfort in daily life, 7–10: Severe pain with significant discomfort in daily life.



**Fig 1. Patient's lingual frenulum and surrounding area during the OCNT process.** (A) Before OCNT implementation, (B) About 5 hours after OCNT application, (C) About 10 hours after OCNT application. After the application of OCNT, improvements in the redness and swelling of the lingual frenulum (red circle) and a general reduction in the swelling of surrounding lymph nodes (yellow circle) were observed. Moreover, the circulation of the sublingual vein improved with the continuation of OCNT (blue circle).

saponin components of *Panax notoginseng* root, are known to improve blood circulation by clearing blocked blood passages.<sup>8</sup> These improvements were leveraged to facilitate blood circulation in the affected area and reduce inflammation for the patient.

The patient suddenly developed lingual frenulum inflammation, and her condition was severe enough for the hospital to recommend laser treatment. Not only was the lingual frenulum affected, but the surrounding lymph nodes were also swollen. However, with the application of OCNT, swelling significantly improved within approximately 5 hours, and notable improvements were seen in the surrounding lymph nodes and sublingual veins. The significant improvement within 24 hours, at which time the patient almost felt no discomfort, was deemed meaningful.

As this case study involves a single patient, it has limitations in being universally applicable to all cases of lingual frenulum inflammation. However, the significant and rapid improvement of symptoms through OCNT is considered significant. Thus, this case is reported with the patient's consent.

### References

1. Mills N, Geddes DT, Amirapu S, Mirjalili SA. Understanding the Lingual Frenulum: Histological Structure, Tissue Composition, and Implications for Tongue Tie Surgery. *Int J Otolaryngol*. 2020;2020:1820978.
2. Mills N, Pransky SM, Geddes DT, Mirjalili SA. What is a tongue tie? Defining the anatomy of the in-situ lingual frenulum. *Clin Anat*. Sep 2019;32(6):749-761.
3. Seladi-Schulman J. Lingual frenulum: Treating and preventing abnormal conditions. Healthline Media. Accessed October 24, 2024. <https://www.healthline.com/health/lingual-frenulum>
4. Silva FG, Loeb LM, Macedo AF, dos Santos MTBR, Diniz MB, Guaré RO. Five year follow-up of non-invasive treatment for self-inflicted oral trauma in a child with cerebral palsy. *Revista Cubana de Estomatología*. 2019;56(3):1-9.
5. Butawan M, Benjamin RL, Bloomer RJ. Methylsulfonylmethane: applications and safety of a novel dietary supplement. *Nutrients*. 2017;9(3):290.
6. Barmaki S, Bohlooli S, Khoshkharesh F, Nakhostin-Roohi B. Effect of methylsulfonylmethane supplementation on exercise-Induced muscle damage and total antioxidant capacity. *The Journal of sports medicine and physical fitness*. 2012;52(2):170-174.
7. Hu Y, Fan Q, Qiao B, et al. Alleviatory Role of Panax Notoginseng Saponins in Modulating Inflammation and Pulmonary Vascular Remodeling in Chronic Obstructive Pulmonary Disease: mechanisms and Implications. *Copd*. Dec 2024;21(1):2329282.
8. Zhou R, Zhang J, Zhang W, et al. Clinical efficacy and safety of Panax notoginseng saponins in treating chronic obstructive pulmonary disease with blood hypercoagulability: A meta-analysis of randomized controlled trials. *Phytomedicine*. Mar 2024;125:155244.