

세포교정영양요법(OCNT)을 이용한 건선 개선 사례

신재명 약사

서울특별시 영등포구 영등포로 208-1 하나로약국

A Case of Psoriasis Improvement Using Ortho-Cellular Nutrition Therapy (OCNT)

Pharmacist, Jaemyeong Shin

Hanaro Pharmacy, 208-1, Yeongdeungpo-ro, Yeongdeungpo-gu, Seoul, Republic of Korea

ABSTRACT

Objective: Case report on the improvement of psoriasis using Ortho-Cellular Nutrition Therapy (OCNT).**Methods:** A woman in her forties, who suddenly developed psoriasis with excessive scaling, itching, and inflammation, was treated with OCNT.**Results:** After implementing OCNT, the scaling and inflammation at the psoriasis sites significantly decreased, and both skin condition and quality of life significantly improved.**Conclusion:** OCNT can help alleviate symptoms in patients suffering from discomfort due to psoriasis.**Keywords** Ortho-Cellular Nutrition Therapy (OCNT), psoriasis, inflammation, immune response

Introduction

Psoriasis is a type of chronic papulosquamous dermatitis that can occur at any age. This condition can be classified into various types based on the symptoms and affected areas, including plaque psoriasis characterized by silver scales on erythema, pustular psoriasis with hyperkeratosis and pustules, and psoriasis occurring on the nails and toenails.¹

The primary cause of psoriasis is associated with an immune response. When dendritic cells in the body are activated by genetic, environmental factors, or chronic diseases, pro-inflammatory cytokines such as TNF- α , IFN- γ , interleukin (IL)-17, and IL-23 are produced. An excessive concentration of these cytokines can cause overproliferation of keratinocytes and inflammation, triggering psoriasis. Moreover, this inflammatory response is not temporary but persists chronically, increasing the cytokine levels systemically and potentially widening the affected areas.² External factors such as physical stress, excessive exposure to ultraviolet rays, drugs, vaccinations, external infections, and lifestyle habits can also cause psoriasis.³

Psoriasis not only causes physical symptoms but also significantly impacts psychological and social quality of life due to the nature of the skin lesions. Accordingly, in 2014, WHO adopted a resolution defining psoriasis as "a chronic, non-

communicable disease with no cure that causes pain, disfigures appearance, and leads to disability".⁴

Therefore, modern medicine and pharmacy apply various methods to treat psoriasis. These methods can be broadly divided into topical treatments and systemic treatments. Topical treatments include the use of creams, ointments, gels with corticosteroids, calcineurin inhibitors, and phototherapy that targets the lesions with ultraviolet light. Systemic treatments typically involve oral medications that block chemical and biological pathways. These treatments can be selectively applied depending on the patient's lesion area and extent. Moreover, the best outcomes are achieved by considering various factors such as underlying diseases, patient preferences, and satisfaction in the selection process of the treatment method.⁵

This case involves a patient who suddenly developed severe psoriasis, experiencing significant discomfort from itching, redness, and scaling all over the body. Therefore, after applying OCNT and observing significant improvements, it was decided to report this case with the patient's consent.

Case Study

1. Subject

A single case of a psoriasis patient was studied.

- 1) Name: Shin O (46 / F)
- 2) Diagnosis: Psoriasis
- 3) Date of onset: May 2024
- 4) Treatment duration: May 2024 to June 2024
- 5) Primary symptoms: Dermatitis, itching
- 6) Medical history: Shingles, nummular eczema

*Correspondence: Jaemyeong Shin

E-mail: chum119@naver.com

Received Nov 29, 2024; Accepted Nov 29, 2024; Published Nov 29, 2024
doi: <http://dx.doi.org/10.5667/CellMed.spc.106>

©2024 by CellMed Orthocellular Medicine Pharmaceutical Association
This is an open access article under the CC BY-NC license.

(<http://creativecommons.org/licenses/by-nc/3.0/>)

† This report has been translated and edited by the CellMed editor-in-chief, Prof. Beom-Jin Lee.

- 7) Social history: None
- 8) Family history: None
- 9) Current medical conditions and medications: None

2. Methods

The following OCNT regimen was applied:

- Oral Formulations

Paragon (101, twice daily, one packet per dose, prescribed for the initial 5 days)
Cyaplex X granule (101, twice daily, one packet per dose)
Eufaplex Alpha Stick (101, twice daily, one packet per dose)
Nutaplex granule (101, twice daily, one packet per dose)
Tmplex granule (101, twice daily, one packet per dose)

- Topical Formulations

Cyaplex Balm (applied mornings and evenings regularly on areas with oozing and wounds, and swollen areas)
Cyaplex Cream (applied frequently on areas with scaling or itching such as elbows and hands)
Licoplex Liquid (applied frequently when itching intensifies)
Cyaplex Cleansing Bar (used during facial washing and showering)

OCNT was prescribed as described above. Additionally, the patient was advised to resume a diet that she had previously started on her own but discontinued, which restricts dining out, condiments, processed foods, and meat consumption.

Results

The patient was experiencing severe itching and psoriasis symptoms throughout the body. The psoriasis symptoms were particularly severe around the neck area and noticeable on the inner arms, knees, and backs of the hands. Therefore, OCNT was implemented to induce improvement of these symptoms.

In the early stages of OCNT, redness and scaling tended to worsen slightly. However, most of the skin inflammation throughout the body had improved after 15 days. Additionally, the inflammation and thick layer of scaling in the most severely affected neck area gradually became healthier as OCNT progressed. Changes in the patient's lesion sites with the progression of OCNT are presented in Figs. 1-6.

Discussion

The patient, a woman in her forties, experienced a sudden onset of severe itching and psoriasis across her entire body and visited a pharmacy. Upon examination, the lesions had thick scaling and erythema was observed throughout the body. Particularly, the neck area showed a wider extent of keratinization more severe than other areas.

During the patient interview, chronic coin-shaped eczema (nummular eczema) was reported as a condition she had been suffering from since her early forties. Consequently, she believed that her diet, particularly meat-based meals, had a significant impact and continued a diet that eliminated meat and condiments. However, during a month-long international tour, she was unable to maintain this dietary management, which resulted in severe itching and the onset of psoriasis.

This suggests that the patient's immune maintenance was affected by stress due to changes in her environment and dietary conditions during her international travels, leading to excessive toxin production. The impact seems to manifest as psoriasis on her skin, similar to the eczema and shingles she had experienced before. Therefore, topical OCNT was prescribed to improve inflammation at the lesion sites and provide moisturization and nutrients, while oral formulations of OCNT were used to enhance overall antioxidant functions, improve immunity, eliminate toxins, and strengthen cellular membranes.

Initially, Paragon was used to eliminate toxins that negatively affect the body's condition. Among the ingredients used in Paragon, extracts of wormwood, fennel, and clove, known for their antimicrobial activity against parasites, bacteria, and viruses, have been widely used in traditional medicine.⁶⁻⁸ Additionally, research suggests that the extract of *Torreya nucifera* found in Paragon can help inhibit parasitic infections and internal parasites.⁹ Thus, early use of OCNT is thought to effectively remove toxins and subsequently aid the synergistic effects of following OCNT.

Anthocyanins, abundantly found in berries, are known for their antioxidant effects that protect cells from free radicals and oxidative stress and are recognized to be more potent than other antioxidants. Studies have also shown their antimicrobial and anti-inflammatory effects.¹⁰ These components, richly contained in the oral formulation Cyaplex X, and topical formulations Cyaplex Balm and Cyaplex Cream, were intended to help improve symptoms through internal and external antioxidant actions.

The removal of oxidative stress and toxins that affect cells is important for symptom improvement, but equally crucial is strengthening the cell membrane to prevent the penetration of toxins. Omega-3, the main ingredient in Eufaplex, alters the lipid composition of the cell membrane when distributed in the cell's lipid membrane after ingestion. This change modifies the mechanical properties of the cell membrane and is involved in the signaling of cell receptors, playing a vital role in forming healthy cell membranes. For example, numerous studies have shown that omega-3 intake improves endothelial function and health in cardiovascular areas.¹¹ Therefore, this presumably strengthened the cell barriers and helped improve symptoms.

Furthermore, OCNT was intended to provide nutrients necessary for the normal functioning of the immune system. An adequate intake of trace minerals is essential to promote and maintain a normal immune response. This includes selenium, zinc, manganese, iron, etc. These nutrients help enhance immune function by acting on various mechanisms of innate and adaptive immunity within the body.¹² Moreover, chlorella is known to enhance the activation of immune responses by promoting the response of NK cells and Th1 cells internally.¹³ These nutrients were provided through Tmplex and Nutaplex.

Through oral formulations, we aimed to improve systemic symptoms and used topical formulations for specific lesion areas to induce anti-inflammatory, antibacterial, moisturizing, descaling, and skin barrier strengthening effects to aid in the improvement of psoriasis symptoms.

Licoplex Liquid and Cyaplex Cream contain Dipotassium Glycyrrhizate (DPG) extracted from licorice. This component has been shown through research to help aid in anti-inflammatory functions by suppressing inflammatory exudates

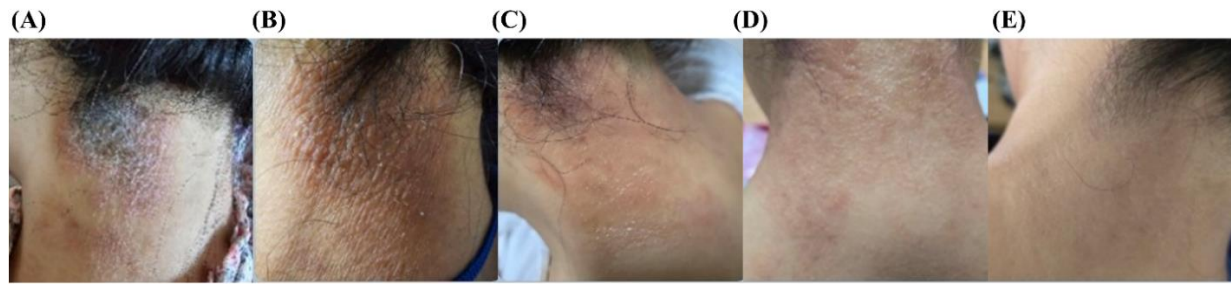


Fig. 1. Changes in the lesions on the back of the patient's neck following OCNT progression. The figures show the changes with OCNT progression timewise from (A) to (E). As OCNT progresses, both the extent and degree of scaling decrease, and the erythema also fades.

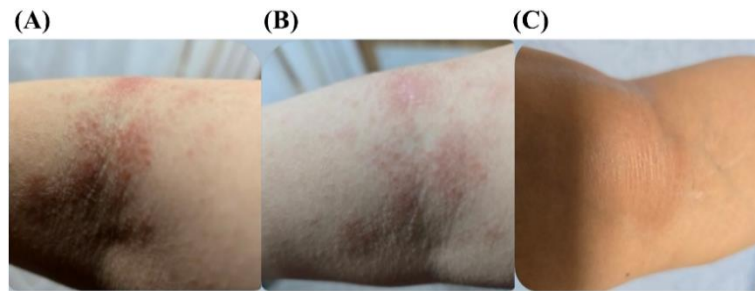


Fig. 2. Changes in the lesions on the back of the patient's left knee following OCNT progression. The figures show the changes with OCNT progression timewise from (A) to (C). As OCNT progresses, the degree of scaling improves and the erythema diminishes.

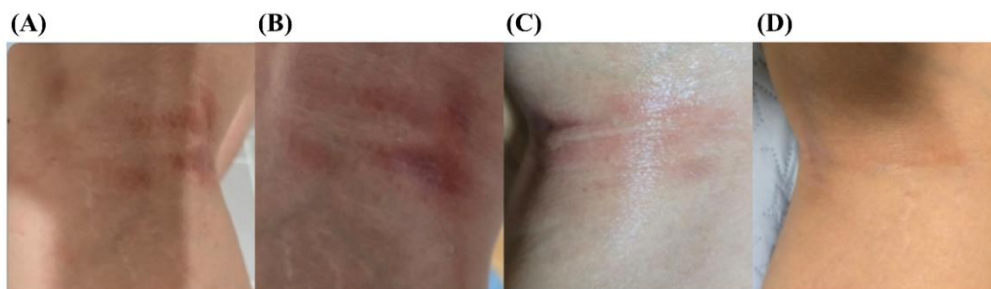


Fig. 3. Changes in the lesions on the back of the patient's right knee following OCNT progression. The figures show the changes with OCNT progression timewise from (A) to (D). An improvement in erythema is noticeable as OCNT progresses.

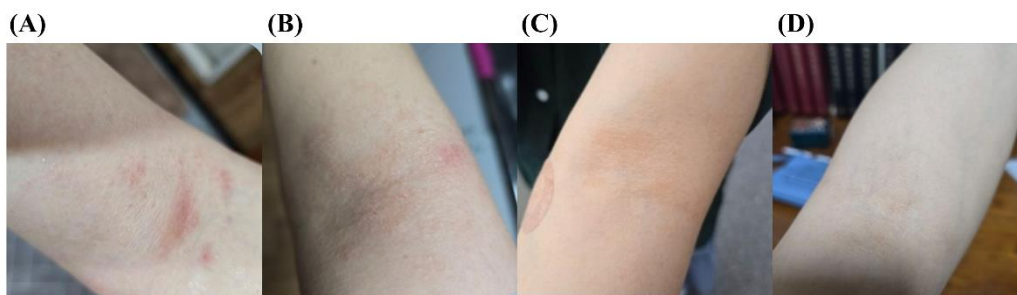


Fig. 4. Changes in the lesions on the inner part of the patient's left arm following OCNT progression. The figures show the changes with OCNT progression timewise from (A) to (D). As OCNT progresses, the erythema lightens and the skin scaling gradually decreases.

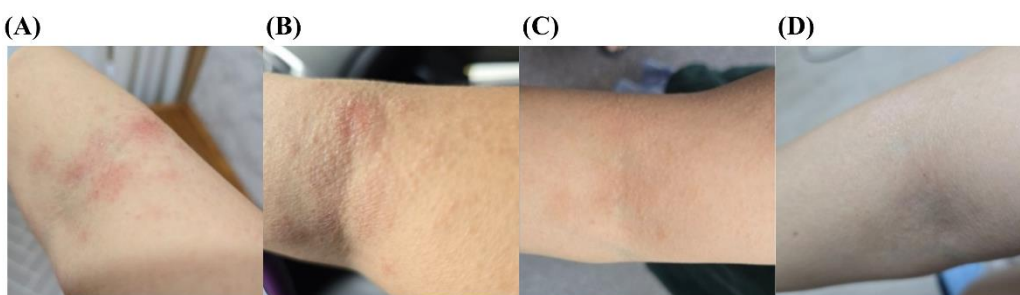


Fig. 5. Changes in the lesions on the inner part of the patient's right arm following OCNT progression. The figures show the changes with OCNT progression timewise from (A) to (D). As OCNT progresses, the erythema decreases and the degree of keratinization improves.

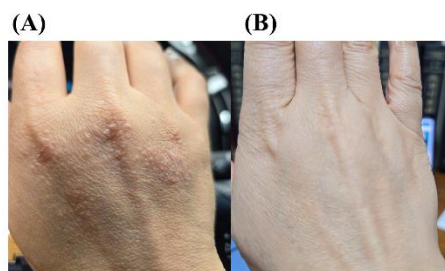


Fig. 6. Changes in the lesions on the back of the patient's hands following OCNT progression. (A) shows the condition before OCNT, and (B) after OCNT. As OCNT progresses, the degree and extent of skin keratinization decrease.

and cytokines.¹⁴ Additionally, one of the ingredients in Cyaplex Balm is an extract of *Centella asiatica*, which contains active components such as asiaticoside and madecassoside. Studies have indicated that these components can suppress inflammation and promote collagen synthesis, aiding in wound healing and potentially improving psoriasis symptoms.¹⁵

It is crucial to moisturize the psoriatic areas for assistance in the recovery of the region. The plant oils in Cyaplex Balm and Cyaplex Cleansing Bar are rich in gamma-linolenic acid, a type of omega-6. This component is known through experimentation to assist in skin moisturization and prevent moisture loss.¹⁶ Moreover, lanolin, contained in Cyaplex Balm, is known to aid skin moisturization and prevent moisture loss through its high occlusive ability.¹⁷ Thus, these ingredients likely played a role in providing basic hydration.

Next, softening and removing hyperkeratized skin and protecting damaged skin would be beneficial for symptom improvement. Salicin and Methylsulfonylmethane (MSM) presumably aided in this aspect, which is contained in the Cyaplex Cleansing Bar. These two ingredients are known through clinical trials to significantly reduce scaling stably and help improve wrinkles created by damage from UV rays and other sources.^{18,19}

Through such OCNT measures, significant improvements in itching, erythema, and scaling symptoms were visually observed within a relatively short period. Additionally, concurrent use of oral and topical formulations is suggested to potentially elicit complex synergistic effects, leading to improvements in local and systemic symptoms.

Since this case study focused on a single patient, there are limitations to applying these results to all psoriasis patients. However, the significant improvement of symptoms through OCNT in a short period and the enhancement of the patient's quality of life are considered meaningful. Thus, this case is reported with the patient's consent.

References

1. Oji V, Luger TA. The skin in psoriasis: assessment and challenges. *Clin Exp Rheumatol*. Sep-Oct 2015;33(5 Suppl 93):S14-9.
2. Korman NJ. Management of psoriasis as a systemic disease: what is the evidence? *Br J Dermatol*. Apr 2020;182(4):840-848.
3. Kamiya K, Kishimoto M, Sugai J, Komine M, Ohtsuki M. Risk Factors for the Development of

Psoriasis. *Int J Mol Sci*. Sep 5 2019;20(18)

4. World Health O. *Global report on psoriasis*. World Health Organization; 2016.
5. Griffiths CEM, Armstrong AW, Gudjonsson JE, Barker J. Psoriasis. *Lancet*. Apr 3 2021;397(10281):1301-1315.
6. Feng X, Cao S, Qiu F, Zhang B. Traditional application and modern pharmacological research of *Artemisia annua* L. *Pharmacol Ther*. Dec 2020;216:107650.
7. Rafieian F, Amani R, Rezaei A, Karaça AC, Jafari SM. Exploring fennel (*Foeniculum vulgare*): Composition, functional properties, potential health benefits, and safety. *Crit Rev Food Sci Nutr*. 2024;64(20):6924-6941.
8. Batiha GE, Alkazmi LM, Wasef LG, Beshbishy AM, Nadwa EH, Rashwan EK. *Syzygium aromaticum* L. (Myrtaceae): Traditional Uses, Bioactive Chemical Constituents, Pharmacological and Toxicological Activities. *Biomolecules*. Jan 30 2020;10(2)
9. Jeong MJ, Kang SA, Yu SN, et al. Extract of *Torreya nucifera* Pericarps Exhibits a Parasitocidal Effect on the Nematode Parasite, *Trichinella spiralis*. *J Med Food*. Sep 2023;26(9):624-630.
10. Zafra-Stone S, Yasmin T, Bagchi M, Chatterjee A, Vinson JA, Bagchi D. Berry anthocyanins as novel antioxidants in human health and disease prevention. *Mol Nutr Food Res*. Jun 2007;51(6):675-83.
11. Ayee MAA, Bunker BC, De Groot JL. Membrane modulatory effects of omega-3 fatty acids: Analysis of molecular level interactions. *Curr Top Membr*. 2020;86:57-81.
12. Weyh C, Krüger K, Peeling P, Castell L. The role of minerals in the optimal functioning of the immune system. *Nutrients*. 2022;14(3):644.
13. Bax CE, Chakka S, Concha JSS, Zeidi M, Werth VP. The effects of immunostimulatory herbal supplements on autoimmune skin diseases. *Journal of the American Academy of Dermatology*. 2021;84(4):1051-1058.
14. Leite CDS, Bonafé GA, Pires OC, et al. Dipotassium Glycyrrhizinate Improves Skin Wound Healing by Modulating Inflammatory Process. *Int J Mol Sci*. Feb 14 2023;24(4)

15. Bylka W, Znajdek-Awiżeń P, Studzińska-Sroka E, Dańczak-Pazdrowska A, Brzezińska M. Centella asiatica in dermatology: an overview. *Phytother Res.* Aug 2014;28(8):1117-24.
16. Muggli R. Systemic evening primrose oil improves the biophysical skin parameters of healthy adults. *International journal of cosmetic science.* 2005;27(4):243-249.
17. Pavlou P, Siamidi A, Varvaresou A, Vlachou M. Skin care formulations and lipid carriers as skin moisturizing agents. *Cosmetics.* 2021;8(3):89.
18. Abdel-Motaleb AA, Abu-Dief EE, Hussein MR. Dermal morphological changes following salicylic acid peeling and microdermabrasion. *Journal of Cosmetic Dermatology.* 2017;16(4):e9-e14.
19. Chu SG, Chang YJ, Ryu JY, et al. Effects of Methylsulfonylmethane on UVB-induced skin damage: An experimental study in a mouse model. *in vivo.* 2022;36(6):2714-2721.