

Stafne bone cavity and cone-beam computed tomography: a report of two cases

Elluru Venkatesh

Department of Oral Medicine and Radiology, College of Dentistry, Qaseem Private College, Buraidah, Kingdom of Saudi Arabia

Abstract (J Korean Assoc Oral Maxillofac Surg 2015;41:145-148)

In 1942 Stafne reported 35 asymptomatic, radiolucent cavities that were unilaterally located in the posterior region of the mandible between the mandibular angle and the third molar, and below the mandibular canal. The term Stafne bone cavity (SBC) is now used for such asymptomatic lingual bone depressions of the lower jaw. Since then there have been many reports of SBCs but very few studies have used cone-beam computed tomography (CBCT) for their diagnosis. The aim of this paper is to describe the clinical and radiological characteristics of two cases of SBCs and the importance of limited CBCT in confirming the diagnosis.

Key words: Stafne bone cavities, Cone-beam computed tomography, Panoramic radiography, Salivary glands

[paper submitted 2014. 12. 18 / revised 2015. 1. 10 / accepted 2015. 1. 13]

I. Introduction

Stafne¹ first described 35 asymptomatic radiolucent lesions located unilaterally in the posterior region of the mandible, between the mandibular angle and the third molar, inferior to the mandibular canal, and slightly above the mandibular base.

This entity has been given numerous names based on different theories of etiopathogenesis, including static bone cyst, lingual mandibular bone defect, Stafne bone cavity (SBC), idiopathic bone cavity, and lingual mandibular bone depression². However, the accepted theory is that they develop as a result of localized pressure atrophy of the lingual surface of the mandible from the adjacent salivary gland³.

SBCs are most commonly observed in men in their fifth or sixth decade of life and have a prevalence between 0.10% and 0.48%⁴⁻⁶. They may present as round or oval, and range in size from 1 to 3 cm in diameter⁷.

SBC is more commonly seen in the posterior region of the mandible (posterior variant), but can also appear in the anterior region (anterior variant) and in the ascending ramus of the mandible (mandibular ramus variant)⁸. It is generally unilateral, with some reports of bilateral occurrence⁹⁻¹². Double unilateral occurrence is rare, and bilocular occurrence is even rarer⁹. There are many reports of SBC but the use of cone-beam computed tomography (CBCT) for diagnosis is rare. The aim of this paper is to describe the clinical and radiological characteristics of 2 cases of Stafne bone cyst and the importance of limited CBCT in confirming the diagnosis.

II. Cases Report

1. Case 1

A 31-year-old asymptomatic male patient was referred to Secunderabad Dental Imaging Centre (Hyderabad, India) to undergo routine panoramic radiography. The panorama revealed a cystic lesion in the left posterior mandible just anterior to the mandibular angle and below the third molar and mandibular canal. (Fig. 1) There was no significant medical or dental history. There was no tenderness on bidigital palpation at the site of the lesion. For further analysis, CBCT restricted to the area of lesion was performed. The results revealed a complete radiolucent lesion that was regular, oval in shape,

Elluru Venkatesh

Department of Oral Medicine and Radiology, College of Dentistry, Qaseem Private College, Western Ring Road, Buraidah 156, Kingdom of Saudi Arabia

TEL: +966-16-3260111 FAX: +966-16-3260666

E-mail: dr_eva1@yahoo.com

ORCID: <http://orcid.org/0000-0002-6723-2514>

© This is an open-access article distributed under the terms of the Creative Commons Attribution Non-Commercial License (<http://creativecommons.org/licenses/by-nc/4.0/>), which permits unrestricted non-commercial use, distribution, and reproduction in any medium, provided the original work is properly cited.

Copyright © 2015 The Korean Association of Oral and Maxillofacial Surgeons. All rights reserved.

and well corticated.(Fig. 2. A-D) The lesion was located below the mandibular canal and measured 11.8×8.4×14.1 mm (height×breadth×length).(Fig. 2. E, 2. F) The long axis of the lesion was placed horizontally on the left side. The cross-sections revealed a close relationship with the mandibular nerve without any pressure effect.(Fig. 2. B) The patient was asymptomatic and there was no parasthesia or anaesthesia. The buccal wall was intact and there was no expansion (Fig. 2. B); however, the lingual wall was involved. The inferior border was also intact with little pressure atrophy.

A radiographic diagnosis of SBC was considered and the patient was advised to undergo regular follow-up examinations.

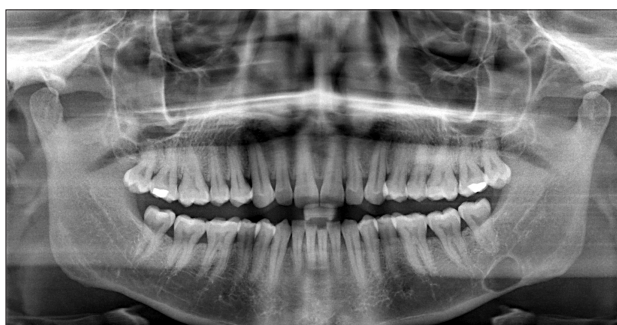

Fig. 1. Panoramic view shows the lesion.
 Elluru Venkatesh: Stafne bone cavity and cone-beam computed tomography: a report of two cases. J Korean Assoc Oral Maxillofac Surg 2015

2. Case 2

A 35-year-old male patient was similarly referred to Secunderabad Dental Imaging Centre (Hyderabad, India) to undergo routine panoramic radiography. The panorama revealed a cystic cavity on the left side below the second molar and mandibular canal, anterior to the angle of the mandible. (Fig. 3) Medical and dental history was not contributory. There was no tenderness on bidigital palpation at the site of the lesion. For further analysis, CBCT restricted to the area of lesion was performed. The results revealed a complete radiolucent lesion that was regular, oval in shape, and well corticated.(Fig. 4. A-D) The lesion was situated below the mandibular canal and measured 4.7×12.7×16.6 mm (height×breadth×length).(Fig. 4. E, 4. F) The long axis of the lesion was situated horizontally in the left side. Cross-sections revealed a mandibular canal within the lesion without any pressure effect.(Fig. 4. B) The patient was asymptomatic and there was no parasthesia or anaesthesia. The buccal wall and the inferior border were intact and there was no expansion (Fig. 4. B); however, the lingual wall was involved and the inferior border showed some pressure atrophy.

A radiographic diagnosis of SBC was considered and the patient was recommended for regular follow-up.

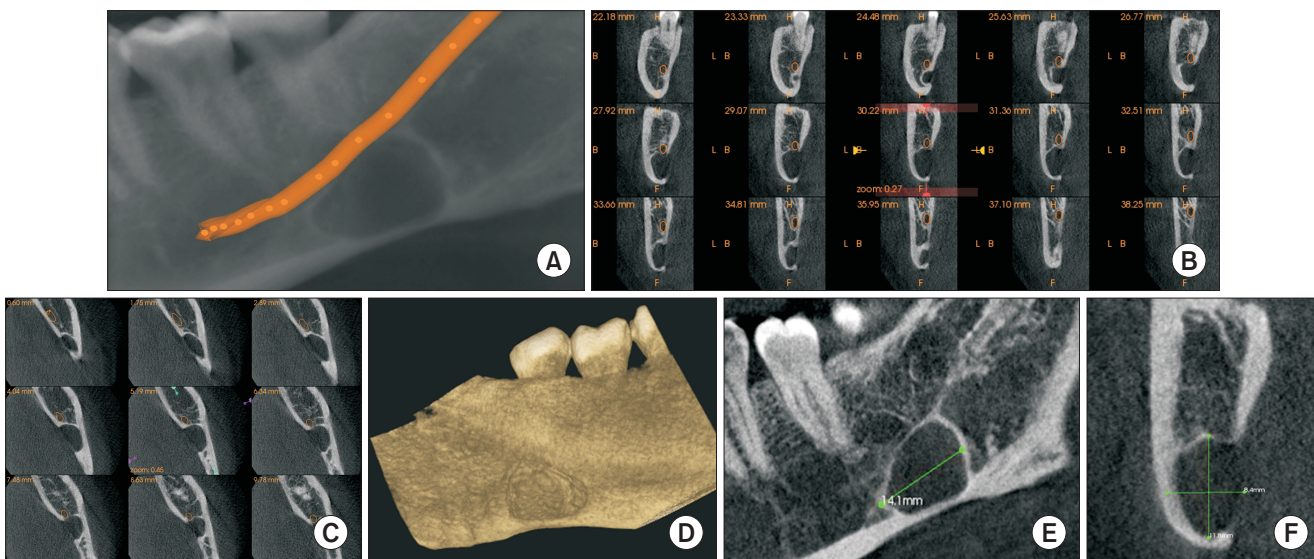


Fig. 2. Cone-beam computed tomography images. A. Panoramic view with mandibular nerve canal traced. B. Cross-section revealing the relationship of the lesion with the mandibular canal. C. Axial view revealing the relationship of the lesion with the mandibular canal. D. Three-dimensional reconstructed view from lingual aspect. E, F. Dimensions of the lesion.
 Elluru Venkatesh: Stafne bone cavity and cone-beam computed tomography: a report of two cases. J Korean Assoc Oral Maxillofac Surg 2015

III. Discussion

Since Stafne first described the SBC in 1942, many cases have been reported. The most widely accepted etiopathogenesis is that the lesions develop as a result of localized pressure atrophy of the lingual surface of the mandible from the adjacent salivary gland^{1,7,9,10}.

There are anterior and posterior variants of SBC, although most cases are posterior variants located between the mandibular angle and first mandibular molar tooth below the inferior dental canal^{1,2,4,7-18}. In both of our cases the lesions were situated in the posterior region below the mandibular canal, anterior to the angle of the mandible, and on the left side.

According to their relationship to the buccal cortical wall, SBCs can be divided into three types: in type I, the cavity

does not reach the buccal cortex; in type II, it reaches the buccal cortex without expanding it; and in type III, the buccal osseous cortex is expanded¹⁹. Both of the cases described here belonged to type II.

SBCs are incidental findings because patients are asymptomatic⁴. Radiographically, they present as a cystic cavity with a well-defined sclerotic border, situated in the posterior region of the mandible, below the inferior dental canal^{17,18}. Similar findings were obtained in our cases.

The reported predilection of SBC in men is aged between 50 and 70 years^{2,7,11,13}. Both of our patients were male, but they were relatively young at 37 and 35 years old, respectively. Both were asymptomatic.

SBCs are an anatomical rather than a pathological condition and do not require any surgical treatment. Patients are usually only followed up radiographically, although surgical exploration or biopsy should be performed in atypical cases or other suspected lesions. As there were no signs of inflammatory or tumoral changes in our patients no surgical intervention was performed and the patients were recommended for regular follow-up.

CBCT is a major innovation in the field of dentistry and has gained popularity because of its low radiation, limited area exposure, high resolution, and ease of availability compared to medical CT²⁰.

CBCT facilitates both diagnosis and follow-up, especially through the reconstructed images that show radiographic features in fine detail. In both of our cases CBCT was very

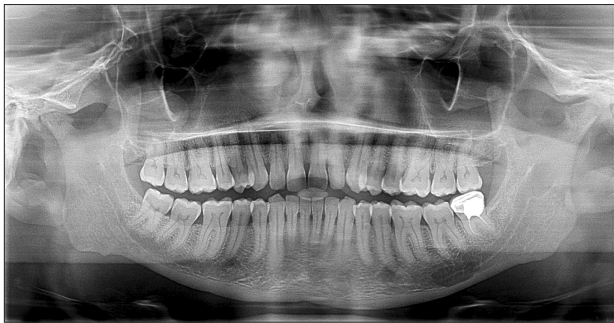

Fig. 3. Panoramic view shows the lesion.
Elluru Venkatesh: Stafne bone cavity and cone-beam computed tomography: a report of two cases. *J Korean Assoc Oral Maxillofac Surg* 2015

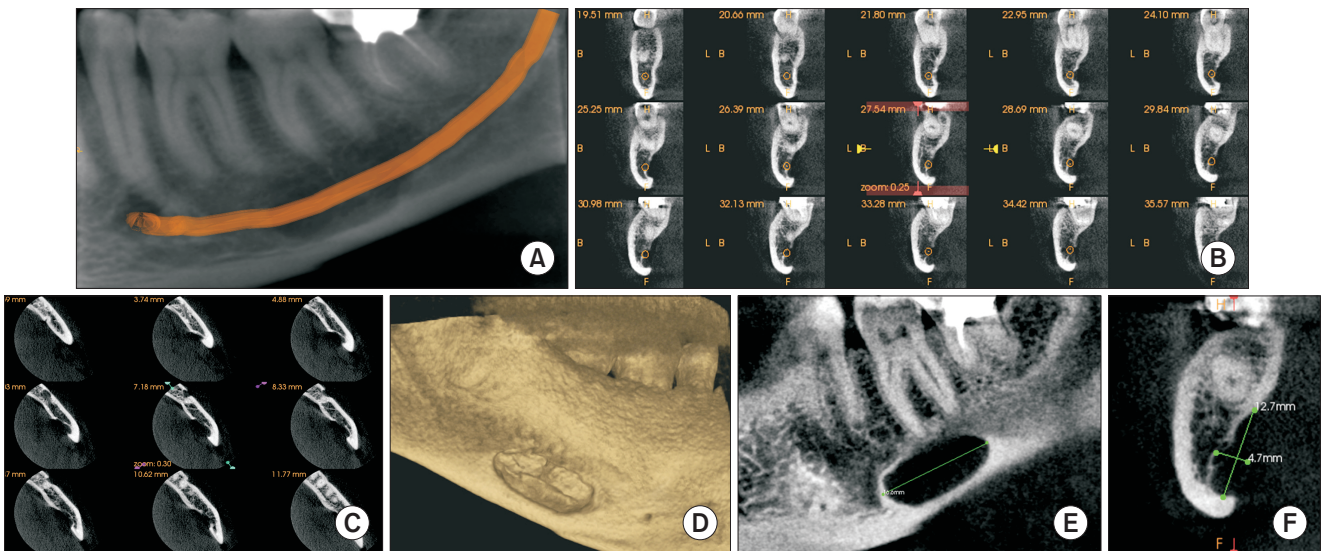


Fig. 4. Cone-beam computed tomography images. A. Panoramic view with mandibular nerve canal traced. B. Cross-sections revealing the relationship of the lesion with the mandibular canal. C. Axial view revealing the relationship of the lesion with the mandibular canal. D. Three-dimensional reconstructed view from lingual aspect. E, F. Dimensions of the lesion.

Elluru Venkatesh: Stafne bone cavity and cone-beam computed tomography: a report of two cases. *J Korean Assoc Oral Maxillofac Surg* 2015

helpful in analyzing the cases and establishing a negative relationship with dentition and the mandibular canal. Another important aspect of our paper is the use of limited area exposure with CBCT, which is an added advantage of this technique.

SBCs are incidental findings, especially on panorama, and are considered anatomical rather than pathological. They do not have any alarming effects on the surrounding structure and do not require surgical attention, but only regular radiographic follow-up. However, they should be analyzed using three-dimensional imaging to rule out other similar appearing lesions. As demonstrated in our cases, the use of CBCT is highlighted because of the low radiation dose, limited area exposure, and the fine detail of imaging, which is beneficial for the diagnosis of SBC.

Conflict of Interest

No potential conflict of interest relevant to this article was reported.

References

1. Stafne EC. Bone cavities situated near the angle of the mandible. *J Am Dent Assoc* 1942;29:1969-72.
2. Grellner TJ, Frost DE, Brannon RB. Lingual mandibular bone defect: report of three cases. *J Oral Maxillofac Surg* 1990;48:288-96.
3. Boyle CA, Horner K, Coulthard P, Fleming GJ. Multiple Stafne bone cavities: a diagnostic dilemma. *Dent Update* 2000;27:494-7.
4. Quesada-Gómez C, Valmaseda-Castellón E, Berini-Aytés L, Gay-Escoda C. Stafne bone cavity: a retrospective study of 11 cases. *Med Oral Patol Oral Cir Bucal* 2006;11:E277-80.
5. Correll RW, Jensen JL, Rhyne RR. Lingual cortical mandibular defects: a radiographic incidence study. *Oral Surg Oral Med Oral Pathol* 1980;50:287-91.
6. Philipsen HP, Takata T, Reichart PA, Sato S, Sueti Y. Lingual and buccal mandibular bone depressions: a review based on 583 cases from a world-wide literature survey, including 69 new cases from Japan. *Dentomaxillofac Radiol* 2002;31:281-90.
7. Flores Campos PS, Oliveira JA, Dantas JA, de Melo DP, Pena N, Santos LA, et al. Stafne's defect with buccal cortical expansion: a case report. *Int J Dent* 2010. doi: 10.1155/2010/515931.
8. Sahin M, Gorgun S, Guven O. Stafne's bone cavity. *Turkey Clinic Dental Sci J* 2005;11:39-42.
9. Dereci O, Duran S. Intraorally exposed anterior Stafne bone defect: a case report. *Oral Surg Oral Med Oral Pathol Oral Radiol* 2012; 113:e1-3.
10. Turkoglu K, Orhan K. Stafne bone cavity in the anterior mandible. *J Craniofac Surg* 2010;21:1769-75.
11. Segev Y, Puterman M, Bodner L. Stafne bone cavity--magnetic resonance imaging. *Med Oral Patol Oral Cir Bucal* 2006;11:E345-7.
12. Branstetter BF, Weissman JL, Kaplan SB. Imaging of a Stafne bone cavity: what MR adds and why a new name is needed. *AJNR Am J Neuroradiol* 1999;20:587-9.
13. Aguiar LB, Neves FS, Bastos LC, Crusoé-Rebello I, Ambrosano GM, Campos PS. Multiple stafne bone defects: a rare entity. *ISRN Dent* 2011. doi: 10.5402/2011/792145.
14. Layne EL, Morgan AF, Morton TH Jr. Anterior lingual mandibular bone concavity: report of case. *J Oral Surg* 1981;39:599-600.
15. Dorman M, Pierse D. Ectopic salivary gland tissue in the anterior mandible: a case report. *Br Dent J* 2002;193:571-2.
16. de Courten A, Küffer R, Samson J, Lombardi T. Anterior lingual mandibular salivary gland defect (Stafne defect) presenting as a residual cyst. *Oral Surg Oral Med Oral Pathol Oral Radiol Endod* 2002;94:460-4.
17. Barker GR. Xeroradiography in relation to a Stafne bone cavity. *Br J Oral Maxillofac Surg* 1988;26:32-5.
18. Reuter I. An unusual case of Stafne bone cavity with extra-osseous course of the mandibular neurovascular bundle. *Dentomaxillofac Radiol* 1998;27:189-91.
19. Arijji E, Fujiwara N, Tabata O, Nakayama E, Kanda S, Shiratsuchi Y, et al. Stafne's bone cavity. Classification based on outline and content determined by computed tomography. *Oral Surg Oral Med Oral Pathol* 1993;76:375-80.
20. Okano T, Harata Y, Sugihara Y, Sakaino R, Tsuchida R, Iwai K, et al. Absorbed and effective doses from cone beam volumetric imaging for implant planning. *Dentomaxillofac Radiol* 2009;38:79-85.