

# Deep benign fibrous histiocytoma in the oral cavity: a case report

Eun Jo<sup>1</sup>, Eunae Sandra Cho<sup>2</sup>, Hyun Sil Kim<sup>2,3</sup>, Woong Nam<sup>1,3</sup>

Departments of <sup>1</sup>Oral and Maxillofacial Surgery and <sup>2</sup>Oral Pathology, <sup>3</sup>Oral Cancer Research Institute, Yonsei University College of Dentistry, Seoul, Korea

**Abstract** (J Korean Assoc Oral Maxillofac Surg 2015;41:270-272)

Benign fibrous histiocytoma (FH) is a benign tumor composed of fibroblasts and histiocytes in varying proportions. This tumor is usually found in adult extremities but rarely occurs in deep soft tissues of the oral cavity. As it is difficult to diagnose with physical and radiologic exams, deep benign FH can only be diagnosed by histopathology. We report a case of a 36-year-old female patient who came to our department with painless swelling in the right buccal mucosa. This case report reviews the clinical, radiological, and histological aspects of this tumor.

**Key words:** Histiocytoma, Head and neck neoplasms, Mouth neoplasms

[paper submitted 2015. 4. 10 / revised 1st 2015. 5. 29, 2nd 2015. 7. 2 / accepted 2015. 7. 29]

## I. Introduction

Fibrous histiocytoma (FH), first reported by Kauffman and Stout in 1961, is composed of fibroblasts and histiocytes in varying proportions<sup>1,2</sup>. FH can be benign or malignant, and malignant FH is usually found in the lower extremities, upper extremities, and retroperitoneum, in order of frequency. Malignant FH in the head and neck area accounts for less than 10% of all malignant FH, and less than 0.5% of all malignant head and neck tumors<sup>3,4</sup>. The treatment of choice for malignant FH is surgical excision, and obtaining a clear surgical margin is crucial due to its survival benefit<sup>2,3,5</sup>. Benign FH is usually found in adult extremities, the head and neck area, and the retroperitoneum. However, the occurrence of benign FH in the oral cavity is rare<sup>6,7</sup>. Benign FH can be categorized into superficial and deep forms. Deep benign FH is very rare, comprising less than 5% of all benign FH tumors<sup>6</sup>. We encountered a patient with painless swelling in the right buccal

mucosa. Based on magnetic resonance imaging (MRI), we suspected that the lesion was a minor salivary gland tumor or a neurofibroma. Excisional biopsy was performed and the intraoperative mass appeared to be a pleomorphic adenoma. The final pathologic diagnosis was deep benign FH. This case report reviews the clinical, radiological, and histological aspects of this tumor.

## II. Case Report

A 36-year-old female patient came to our department with painless swelling in the right buccal mucosa which had started 3 weeks previously. There was no specific medical history or history of trauma. A palpable mass was found at the right buccal mucosa, having an induration consistency without tenderness on palpation. However, no gross abnormality was found by observation. After the physical examination, we suspected a lipoma. MRI revealed a well-marginated 1.8 cm enhancing ovoid lesion in the right buccal space.(Fig. 1)

An excisional biopsy was performed under local anesthesia. An incision was created over the mass at the buccal mucosa and extraoral pressure was applied with a finger during the dissection. A well-encapsulated 2.3×1.3×1.3 cm mass was easily separated and removed.(Fig. 2, 3) It appeared to be a pleomorphic adenoma based on the intraoperative findings.

Histopathologic examination showed predominantly spindle cells and areas of myxoid stroma.(Fig. 4. A) A high power view revealed a prominent storiform pattern of fibroblastic

### Woong Nam

Department of Oral and Maxillofacial Surgery, Yonsei University College of Dentistry, 50-1 Yonsei-ro, Seodaemun-gu, Seoul 03722, Korea

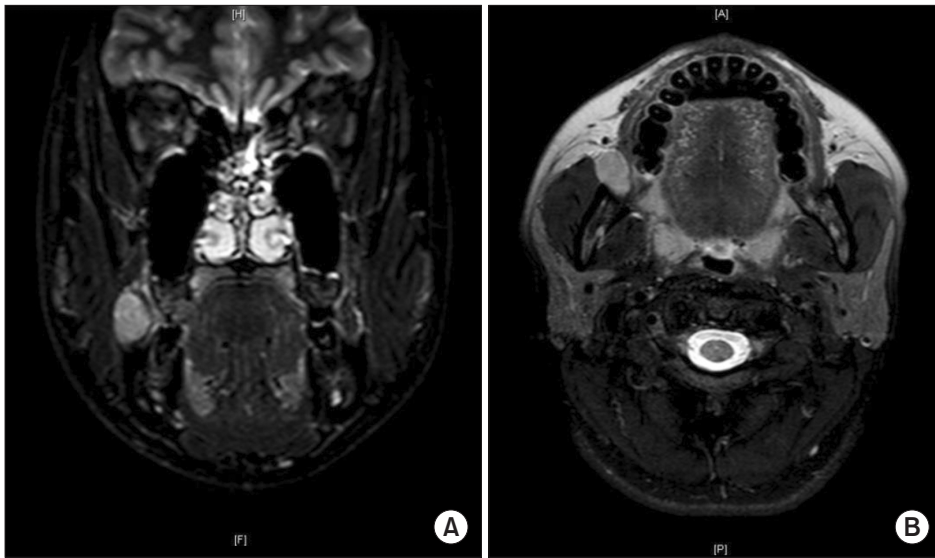
TEL: +82-2-2228-2971 FAX: +82-2-2227-8022

E-mail: omsnam@yuhs.ac

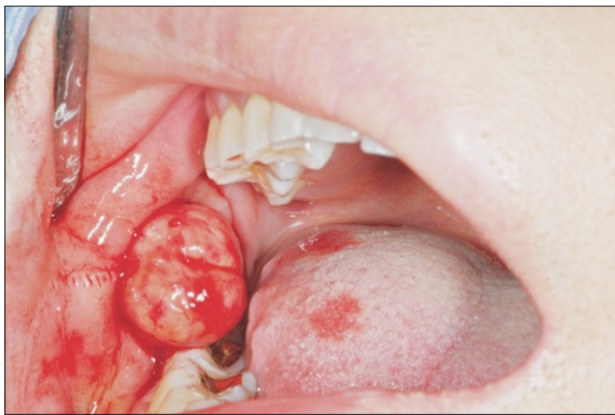ORCID: <http://orcid.org/0000-0003-0146-3624>

©This is an open-access article distributed under the terms of the Creative Commons Attribution Non-Commercial License (<http://creativecommons.org/licenses/by-nc/4.0/>), which permits unrestricted non-commercial use, distribution, and reproduction in any medium, provided the original work is properly cited.

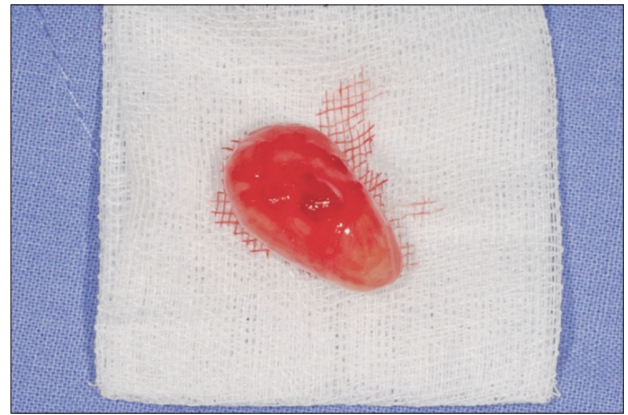Copyright © 2015 The Korean Association of Oral and Maxillofacial Surgeons. All rights reserved.



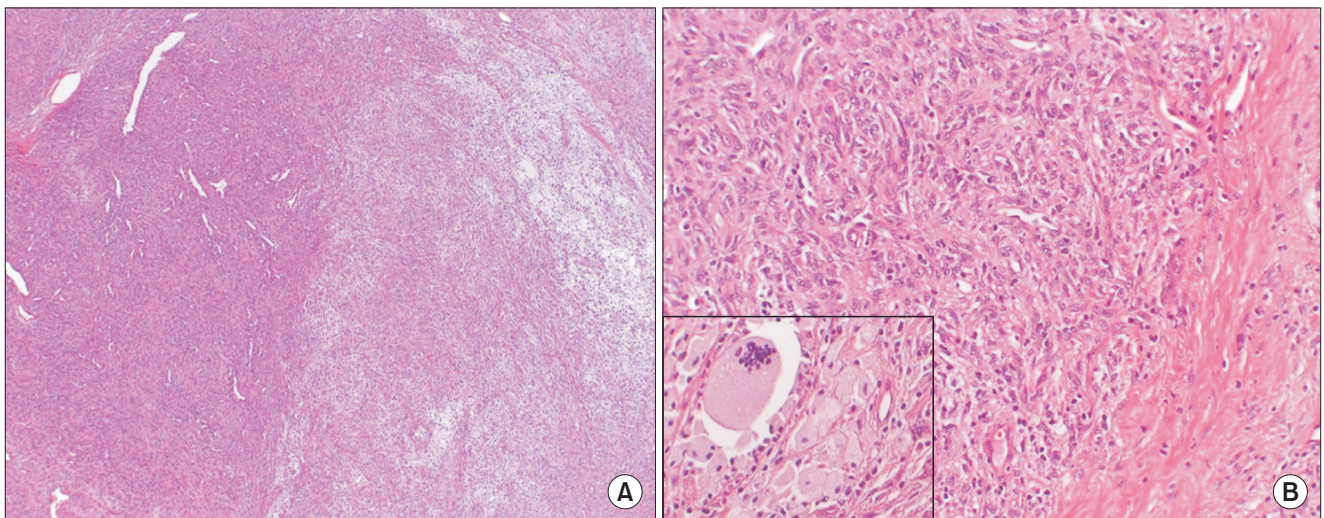
**Fig. 1.** Magnetic resonance imaging findings. A 1.8-cm well-margined enhancing ovoid mass-like lesion in the right buccal space, deep to Stenson's duct. A. Coronal view. B. Axial view.  
*Eun Jo et al: Deep benign fibrous histiocytoma in the oral cavity: a case report. J Korean Assoc Oral Maxillofac Surg 2015*



**Fig. 2.** Incision and dissection was easily done. The mass was well-encapsulated.  
*Eun Jo et al: Deep benign fibrous histiocytoma in the oral cavity: a case report. J Korean Assoc Oral Maxillofac Surg 2015*



**Fig. 3.** A 2.3x1.3x1.3 cm ovoid mass was found.  
*Eun Jo et al: Deep benign fibrous histiocytoma in the oral cavity: a case report. J Korean Assoc Oral Maxillofac Surg 2015*



**Fig. 4.** Histopathologic examination (H&E staining; A: x40, B: x200).  
*Eun Jo et al: Deep benign fibrous histiocytoma in the oral cavity: a case report. J Korean Assoc Oral Maxillofac Surg 2015*

spindle cells with focal bundles of dense collagen, foam cells, and multinucleated giant cells.(Fig. 4. B)

The patient is being regularly followed-up, and there has been no sign of recurrence during 6 months of follow-up.

### III. Discussion

Benign FH is divided into superficial benign FH and deep benign FH, and usually occurs in the extremities of adults<sup>6</sup>. It has been clinically reported on under several names<sup>4</sup>. Deep benign FH accounts for less than 5% of all benign FH tumors and occurs predominantly in males in their 2nd to 4th decade in the lower extremities and head and neck areas, in order of frequency<sup>6,7</sup>.

In most cases, benign FH is a painless mass without symptoms and is well-marginated<sup>8-10</sup>. It is difficult to diagnose deep benign FH with only physical examination.

Deep benign FH rarely occurs in the oral cavity. For this reason, it is difficult to distinguish at first sight and is easily misdiagnosed as a benign tumor such as fibroma or lipoma, which are easily found in the oral cavity. Imaging of deep benign FH shows nonspecific signal intensities on computed tomography and MRI<sup>11</sup>. As it is difficult to diagnose with physical and radiologic exams, deep benign FH can only be diagnosed by its histopathology.

Complete resection of deep benign FH is recommended since it has a higher recurrence rate after operation than other forms of FH. The prognosis of patients with benign FH is usually excellent. Less than 5%-10% recurrence has been reported in the case of large tumors or positive margins after operation<sup>12</sup>. As the reported mean time interval between operation and recurrence is 2 years<sup>13</sup>, follow-up for more than 2 years is suggested. No metastasis has been reported, and radiation therapy and chemotherapy are rarely needed for the management of benign FH.

### Conflict of Interest

No potential conflict of interest relevant to this article was reported.

### ORCID

Eun Jo, <http://orcid.org/0000-0001-6380-1727>

Eunae Sandra Cho, <http://orcid.org/0000-0002-0820-3019>

Hyun Sil Kim, <http://orcid.org/0000-0003-3614-1764>

Woong Nam, <http://orcid.org/0000-0003-0146-3624>

### References

1. Kauffman SL, Stout AP. Histiocytic tumors (fibrous xanthoma and histiocytoma) in children. *Cancer* 1961;14:469-82.
2. Min BI, Kim JW, Kim YK. The clinicopathologic study of malignant fibrous histiocytoma. *J Korean Assoc Oral Maxillofac Surg* 1988;14:77-81.
3. Hardison SA, Davis PL 3rd, Browne JD. Malignant fibrous histiocytoma of the head and neck: a case series. *Am J Otolaryngol* 2013;34:10-5.
4. Blitzer A, Lawson W, Biller HF. Malignant fibrous histiocytoma of the head and neck. *Laryngoscope* 1977;87:1479-99.
5. Spector GJ, Ogura JH. Malignant fibrous histiocytoma of the maxilla. A report of an unusual lesion. *Arch Otolaryngol* 1974;99:385-7.
6. Fletcher CD. Benign fibrous histiocytoma of subcutaneous and deep soft tissue: a clinicopathologic analysis of 21 cases. *Am J Surg Pathol* 1990;14:801-9.
7. Gray PB, Miller AS, Loftus MJ. Benign fibrous histiocytoma of the oral/perioral regions: report of a case and review of 17 additional cases. *J Oral Maxillofac Surg* 1992;50:1239-42.
8. Pandey NK, Sharma SK, Banerjee S. A rare case of fibrous histiocytic tumor of the tongue. *Indian J Surg* 2013;75(Suppl 1):1-5.
9. Weiss SW, Enzinger FM. Malignant fibrous histiocytoma: an analysis of 200 cases. *Cancer* 1978;41:2250-66.
10. Huh HY, Jin WJ, Shin HK, Kim OW. A case report of malignant fibrous histiocytoma of the maxilla. *J Korean Assoc Oral Maxillofac Surg* 1988;14:139-45.
11. Machiels F, De Maeseneer M, Chaskis C, Bourgain C, Osteaux M. Deep benign fibrous histiocytoma of the knee: CT and MR features with pathologic correlation. *Eur Radiol* 1998;8:989-91.
12. Ferrari Parabita G, Viva E, Derada Troletti G, Girardi E. Rare case of a fibrous histiocytoma located in the parotid. *Minerva Stomatol* 1982;31:693-6.
13. Hong KD, Ha SS, Sim JC, Kim TH, Lee JS, Sung MC. Intra-articular benign fibrous histiocytoma of the knee: a case report. *J Korean Bone Joint Tumor Soc* 2012;18:94-8.