

Anterior tympanic plate fracture following extraction of the lower molar

Yeon-Ho Kim, Moon-Key Kim, Sang-Hoon Kang

Department of Oral and Maxillofacial Surgery, National Health Insurance Service Ilsan Hospital, Goyang, Korea

Abstract (J Korean Assoc Oral Maxillofac Surg 2016;42:51-54)

The present case report describes an external auditory canal injury following extraction of the lower molar. The external auditory canal was torn in the same fashion that occurs in an anterior tympanic plate fracture. This case demonstrates one of the rare complications associated with dental extractions.

Key words: External auditory canal, Tooth extraction, Complications

[paper submitted 2015. 6. 22 / revised 2015. 8. 17 / accepted 2015. 9. 5]

I. Introduction

Dental extraction is a commonly performed technique in oral and maxillofacial surgery. Although this technique is frequently performed, it is also commonly associated with diverse complications^{1,2}. The present case report describes an external auditory canal (EAC) injury following extraction of the lower molar. The EAC was torn in the same fashion that occurs in an anterior tympanic plate fracture. This case demonstrates one of the rare complications associated with dental extractions.

II. Case Report

A 55-year-old female patient visited our Department of Oral and Maxillofacial Surgery (OMS) with complaints of right ear discomfort, which began bleeding immediately following a dental extraction performed 30 minutes prior. An hour earlier, the right lower molar and premolar were removed in our OMS department.

The patient had a medical history of hypertension, diabetes,

hyperlipidemia, and varicose veins. This patient had a dental history of an intermittent clicking sound on the right temporomandibular joint (TMJ) with mouth opening. She first visited our department two weeks earlier with a chief complaint of a defect in the lower right, 3-unit gold bridge and a loose, upper right lateral incisor.(Fig. 1) She received a simple extraction of the maxillary lateral incisor with external root resorption during the first visit. A second appointment was scheduled for extractions of the mandibular right molar and premolar two weeks later due to the risk of secondary dental caries. The patient did not report any discomfort during the waiting period after the inferior alveolar nerve block anesthesia. The extraction was performed with a simple method under prophylactic antibiotics. Briefly, the lower right second molar was grasped with forceps and luxated in the lingual direction. The second premolar, which was the 3-unit gold bridge abutment, was removed simultaneously. The second molar was fractured during this process but the root remained intact.

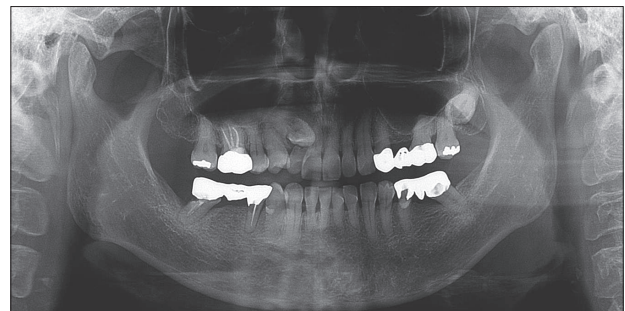


Fig. 1. Panoramic radiograph taken before extraction of the right mandibular molar.

Yeon-Ho Kim et al: Anterior tympanic plate fracture following extraction of the lower molar. J Korean Assoc Oral Maxillofac Surg 2016

Sang-Hoon Kang

Department of Oral and Maxillofacial Surgery, National Health Insurance Service Ilsan Hospital, 100 Ilsan-ro, Ilsan-donggu, Goyang 10444, Korea

TEL: +82-31-900-0267 FAX: +82-303-3448-7138

E-mail: omfs1ksh@hanmail.net

ORCID: <http://orcid.org/0000-0003-3335-3040>

©This is an open-access article distributed under the terms of the Creative Commons Attribution Non-Commercial License (<http://creativecommons.org/licenses/by-nc/4.0/>), which permits unrestricted non-commercial use, distribution, and reproduction in any medium, provided the original work is properly cited.

Copyright © 2016 The Korean Association of Oral and Maxillofacial Surgeons. All rights reserved.

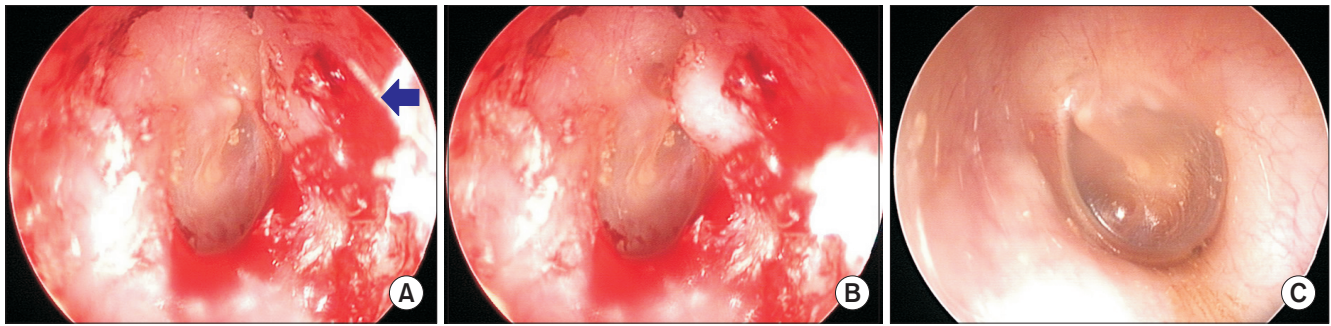


Fig. 2. Endoscopic views of the injured region in the external auditory canal (EAC). A. Endoscopic views of the injured region in the right EAC (arrow). The skin of the anterior wall area of EAC was torn when the jaws were slightly opened. B. Endoscopic views of the injured region in the right EAC. An anterior wall interior bump formed the inside EAC when the mouth was closed. C. Endoscopic views of the non-injured region in the left EAC.

Yeon-Ho Kim et al: Anterior tympanic plate fracture following extraction of the lower molar. J Korean Assoc Oral Maxillofac Surg 2016

The second molar roots were removed one at a time; first the distal root followed by the mesial root with straight elevation. The entire extraction process took approximately 3 minutes. The patient was instructed to bite firmly on three sterile 2×2-inch gauze pads placed over the extraction socket area to stop the bleeding. A second year resident of the OMS department performed the entire procedure. The patient's mouth was wide open during the entire extraction procedure and no abnormal signs were observed. The patient also reported that she did not experience any abnormal symptoms during the procedure.

However, the patient reported that her right ear area began to itch immediately after the extraction and it started bleeding 30 minutes after the extraction. The right EAC was bleeding when the patient returned to the hospital one hour after the extraction. The patient did not report any painful sensations in the right ear. The only symptoms were bleeding and itching. There was no trismus or pain during mastication. The right ear was examined with an endoscope at the Department of Ear, Nose, and Throat Surgery. The skin of the anterior wall area of the EAC was torn.(Fig. 2. A) While clenching, a bump formed on the inside of the ear, within the anterior wall of the EAC.(Fig. 2. B) The ear drum was intact. The left EAC was intact.(Fig. 2. C) When the teeth were closed, a bump was not formed on the inside of the left ear. A computed tomography (CT) scan showed a fracture in the anterior tympanic plate.(Fig. 3) Based on the endoscopic and CT findings, the patient was diagnosed with a fracture in the anterior tympanic plate of the EAC. The patient was sent home after confirming that the bleeding had stopped. The patient was instructed to be careful when chewing or closing the mouth and to return to the hospital immediately if any abnormal symptoms arose in the ear area.

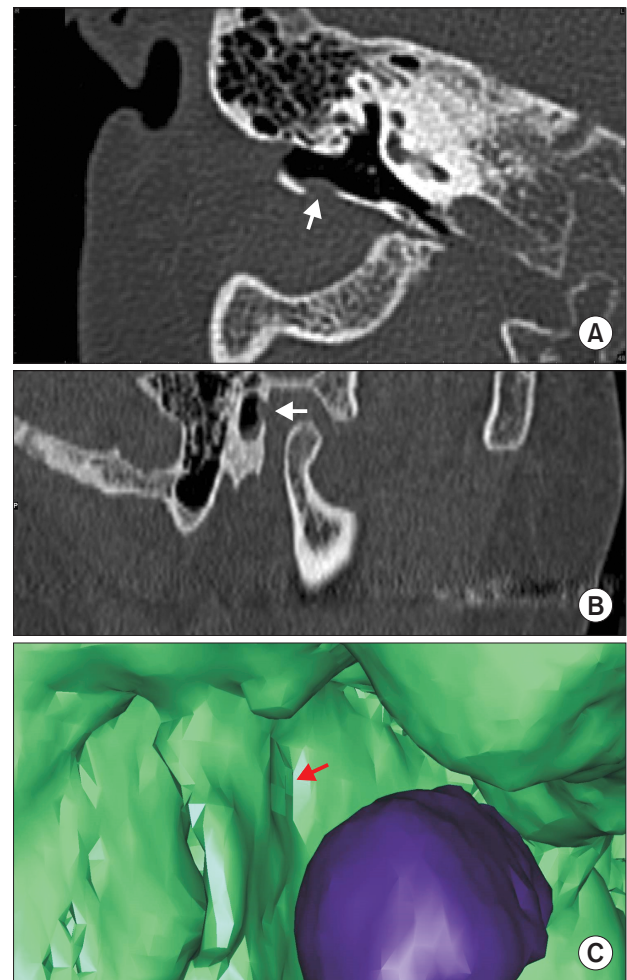


Fig. 3. Computed tomography (CT) image of the damaged external auditory canal area and a fractured anterior tympanic plate. The arrows point to the fractured anterior tympanic plate area. A. Transverse CT image of the injured area. B. Sagittal CT image of the injured area. C. Three-dimensional reconstruction of the CT image of the injured area (purple, condyle head).

Yeon-Ho Kim et al: Anterior tympanic plate fracture following extraction of the lower molar. J Korean Assoc Oral Maxillofac Surg 2016

Two weeks later, an endoscopic examination showed that the EAC was healing well. We checked for signs and symptoms of abnormal mouth function and we acquired a panoramic radiograph.(Fig. 4) The patient did not exhibit any abnormal symptoms in the ear area when opening or closing the mouth or when chewing. We decided to proceed with dental treatment, because there were no symptoms in the ear area or in the TMJ with lower jaw movements.

III. Discussion

Several complications can accompany dental extractions. The present case describes a rare complication where the EAC was injured after extracting the lower molar. Abnormal symptoms in the EAC began 30 minutes after the extraction. The patient complained that the ear area was itchy. It is presumed that at that point, the EAC was damaged. We speculated that the anterior tympanic plate was damaged when the mouth was closed after remaining wide open for extraction, and that the damage was worsened by keeping the mouth closed for a sustained period after the extraction. After the anterior tympanic plate was fractured, the fractured bone segments most likely displaced, thereby tearing the soft tissues in the EAC, which ultimately caused bleeding.

Bayram et al.³ previously reported a case of an EAC injury following extraction of the lower third molar in a 22-year-old female patient. They reported that excess pressure during extraction or suddenly closing the mouth could affect the TMJ, causing a minor fracture without displaced segments. In Bayram's case³, the extraction procedure took about 30 minutes. That patient visited the emergency room with bleeding in the EAC four hours after the extraction. In the present case, the complication occurred despite a rapid extraction

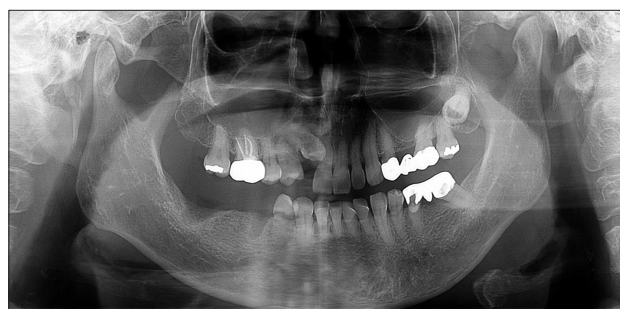

Fig. 4. Panoramic radiograph taken 2 weeks after bleeding at the external auditory canal was observed following extraction of the right mandibular molar.

Yeon-Ho Kim et al: Anterior tympanic plate fracture following extraction of the lower molar. *J Korean Assoc Oral Maxillofac Surg* 2016

procedure. Injection of anesthesia for the inferior alveolar nerve block and the infiltration of anesthesia took about two minutes, and ten minutes were given to obtain a completely anesthetized state. The extraction of the lower right molar took approximately three minutes.

Several factors are thought to play a role in damaging the EAC during dental extraction, including a steep slope of the glenoid fossa in the TMJ and a narrow distance between the mandibular condyle and the anterior wall region of the EAC. Based on CT images taken 3 years ago to examine the maxillary sinus, our patient had a narrow space between the mandibular condyle and anterior tympanic plate of the EAC in the TMJ.(Fig. 5) The panoramic radiograph that we acquired before the extraction did not clearly indicate whether this space was small. Therefore, a separate CT image may be required to assess the space between the mandibular condyle and the tympanic plate.

Quickly closing the mouth after opening for an extended period of time may cause the mandibular condyle to stress the EAC. Wish-Baratz et al.⁴ suggested that when the mouth remains open during molar extraction, blood flow to the retrodiscal pad tissue at the TMJ increases and thereby enlarges the tissue. The TMJ's retrodiscal pad then functions to alleviate the posterior displacement of the mandibular condyle when closing the mouth. In the present case, when the patient was instructed to open her mouth wide, the retrodiscal pad of the TMJ should have enlarged. Consequently, the retrodiscal pad may not have increased in volume sufficiently. We speculated that quickly closing the mouth when the retrodiscal pad of the TMJ was not sufficiently enlarged may have

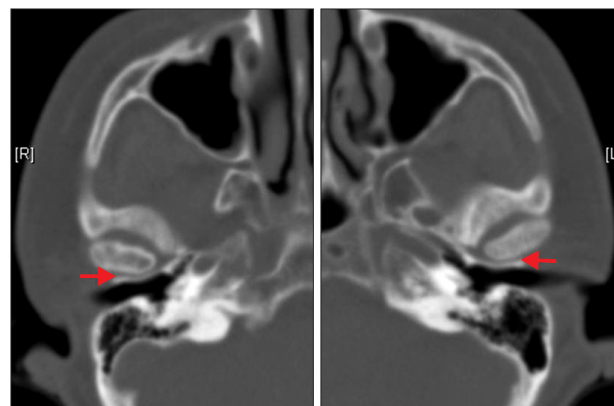


Fig. 5. Axial computed tomography images of the mandibular condylar region acquired 3 years earlier. A small space (arrows) can be observed between the mandibular condyle and external auditory canal.

Yeon-Ho Kim et al: Anterior tympanic plate fracture following extraction of the lower molar. *J Korean Assoc Oral Maxillofac Surg* 2016

increased the pressure on the anterior wall of the EAC. At the same time, the condyle head may have caused increased stress on the anterior tympanic plate of the EAC, due to the steep slope of the glenoid fossa. The past medical history of the patient including diabetes and hypertension may also be associated with impaired blood flow to the retrodiscal pad.

In the case presented by Bayram et al.³, the left EAC was damaged following the extraction of the lower left third molar. In the present case, the right EAC was damaged after the extraction of the lower right molar. Therefore, the EAC ipsilateral to the extraction site appeared more likely to be stressed and damaged than the contralateral EAC. This type of EAC injury is a rare complication of dental extraction because the retrodiscal pad of the TMJ normally buffers posterior movement of the mandibular condyle⁴. Despite the fact that the extraction of the lower third molar requires the patient to maintain the mouth wide open for a long time, EAC injuries are rare, particularly in young patients with good blood circulation to provide sufficient buffering capacity at the retrodiscal pad of the TMJ. In the case presented by Bayram et al.³, the main cause of the complication was the long extraction time (30 minutes). In the present case, the injury was thought to have been aggravated by posterior and superior displacement of the mandibular condyle, due to a malocclusion of the molars after the extraction. These conclusions were based on the endoscopic finding that the EAC was internally displaced when the molars were clenched tightly and the fact that bleeding occurred 40 minutes after extraction. When examining Bayram's case³, we found that the panoramic radiograph taken after EAC bleeding showed that the mandible had been displaced to the left. Thus, the left EAC may have been damaged when the mandible was displaced to the left.

We recommend that the extraction procedure be atraumatic. The slope of the glenoid fossa at the TMJ and the space between the mandibular condyle and EAC should be assessed with CT data when possible. In patients with a steep slope from the TMJ to the glenoid fossa or a small space

between the mandibular condyle and EAC, dental extraction should be performed with extra care. We advise the clinician to ensure that patients do not open their mouths excessively wide or close them too quickly during and immediately after extraction procedures. Furthermore, caution should be taken when luxating teeth to avoid causing the mandibular condyle to exert excessive pressure on the EAC. Moreover, after the extraction, patients should be instructed to bite on a gauze padding of appropriate size, i.e., when the gauze is placed in the extraction socket, the appropriate vertical dimension and anteroposterior position of the mandible should be maintained. Finally, it is critical to observe the symptoms after an atraumatic extraction procedure. An EAC injury following the extraction of the lower molar is a rare but real complication of this procedure.

Conflict of Interest

No potential conflict of interest relevant to this article was reported.

ORCID

Yeon-Ho Kim, <http://orcid.org/0000-0001-9488-7041>

Moon-Key Kim, <http://orcid.org/0000-0002-3634-3705>

Sang-Hoon Kang, <http://orcid.org/0000-0003-3335-3040>

References

1. Lim JS, Yoon HJ, Lee SH. Injury of submandibular gland and lingual nerve as complication third molar tooth extraction in mandible: a case report. *J Korean Assoc Oral Maxillofac Surg* 2011;37:137-41.
2. Marciani RD. Complications of third molar surgery and their management. *Atlas Oral Maxillofac Surg Clin North Am* 2012;20:233-51.
3. Bayram B, Aydin E, Uckan S. External auditory canal injury following removal of an impacted third molar: a case report. *J Oral Maxillofac Surg* 2007;65:1372-4.
4. Wish-Baratz S, Ring GD, Hiss J, Shatz A, Arensburg B. The microscopic structure and function of the vascular retrodiscal pad of the human temporomandibular joint. *Arch Oral Biol* 1993;38:265-8.