

## Angioleiomyoma of the gingiva: a report of two cases

Osman Fatih Arpağ<sup>1</sup>, Ibrahim Damlar<sup>2</sup>, Soydan Kılıç<sup>2</sup>, Ahmet Altan<sup>3</sup>, Zeynel Abidin Taş<sup>4</sup>, Tümay Özgür<sup>4</sup>

Departments of <sup>1</sup>Periodontology and <sup>2</sup>Oral and Maxillofacial Surgery, Faculty of Dentistry, Mustafa Kemal University, Hatay,

<sup>3</sup>Department of Oral and Maxillofacial Surgery, Faculty of Dentistry, Gaziosmanpasa University, Tokat,

<sup>4</sup>Department of Pathology, Faculty of Medicine, Mustafa Kemal University, Hatay, Turkey

**Abstract** (J Korean Assoc Oral Maxillofac Surg 2016;42:115-119)

Leiomyoma is a type of benign smooth muscle neoplasm that is a common neoplasm of the uterus and gastrointestinal tract but rarely affects the head and neck region and is especially unlikely to affect the oral cavity. The diagnosis of leiomyoma is mainly determined by histopathological studies due to variation in its clinical appearance and symptoms. In the present paper we report two rare cases of gingival angioleiomyoma in the posterior maxilla and mandible. After total excision, hematoxylin-eosin and smooth muscle actin staining confirmed the diagnosis of angioleiomyoma.

**Key words:** Leiomyoma, Gingiva, Smooth muscle

[paper submitted 2015. 6. 23 / revised 2015. 8. 28 / accepted 2015. 11. 7]

### I. Introduction

Leiomyoma, a benign smooth muscle tumor, is classified by the World Health Organization (WHO) into three types on the basis of histopathology: i) solid leiomyoma, ii) vascular leiomyoma (angiomyoma, angioleiomyoma), and iii) epithelioid leiomyoma. Although leiomyoma may occur anywhere in the body, leiomyoma most commonly arises in the muscular layer of the gut and the body of the uterus<sup>1</sup>. It rarely affects the oral cavity<sup>2,3</sup> and such cases account for only 0.4% of all neoplasms of the soft tissue and 0.06% of all leiomyoma lesions. Leiomyoma lesions normally have presented as angioleiomyoma at rates ranging from 64.0% to 66.2% of all the reported cases<sup>4</sup>. Angioleiomyomas are common, well-defined, painless, slow growing swellings<sup>5</sup>. The present report describes two rare cases of angioleiomyoma in the gingiva.

### II. Cases Report

#### 1. Case 1

A 25-year-old male patient presented to Department of Periodontology, Faculty of Dentistry, Mustafa Kemal University (Hatay, Turkey) with a complaint of painless gingival swelling that had persisted for one year. On clinical examination we observed a well-demarcated, firm swelling in the region of the lower left first molar vestibular gingiva. (Fig. 1) There was no bleeding upon probing or deep periodontal pocket. The probe depth averaged 2 mm. Radiographic examination did not reveal any changes in the associated bone. (Fig. 2) In addition to general gingival health, the periodontal condition of the mandibular left first molar was healthy. The mass had an ulcerative surface and was measured to be 5×5 mm in diameter. No anesthesia/paresthesia was present. His medical and family history were unremarkable.

As a result of the narrow periodontal probing depth, we chose blunt dissection for the excision of the mass. During excision of the mass, the keratinized gingival structure was preserved to the extent possible. The excised lesion was placed in 10% buffered formalin solution and sent for histopathological assessment. The flap was repositioned and sutured with 4/0 non-resorbable silk suture. Amoxicillin 1 g/12 hr per oral was administered for the following 7 days, while ibuprofen was prescribed as an analgesic along with

---

#### Osman Fatih Arpağ

Department of Periodontology, Faculty of Dentistry, Mustafa Kemal University, Hatay 31040, Turkey

TEL: +90-326-245-60-60 FAX: +90-326-245-50-60

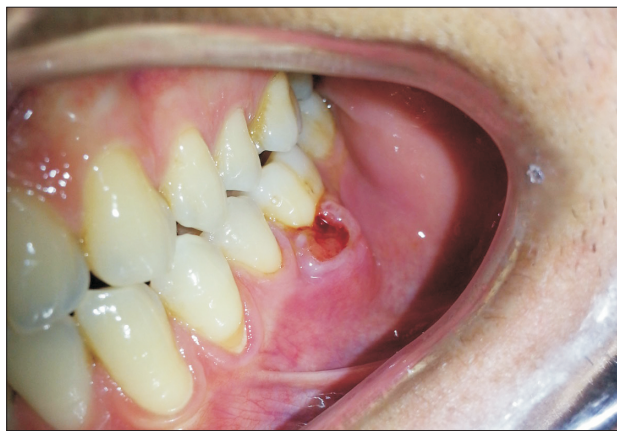E-mail: ofarpag@hotmail.com

ORCID: <http://orcid.org/0000-0002-1510-8917>

©This is an open-access article distributed under the terms of the Creative Commons Attribution Non-Commercial License (<http://creativecommons.org/licenses/by-nc/4.0/>), which permits unrestricted non-commercial use, distribution, and reproduction in any medium, provided the original work is properly cited.

Copyright © 2016 The Korean Association of Oral and Maxillofacial Surgeons. All rights reserved.

chlorhexidine gluconate rinse (0.12%). We confirmed the diagnosis of angioleiomyoma through histological examination via hematoxylin-eosin and smooth muscle actin (SMA) staining. In the histopathological report, the angioleiomyoma was composed of spindle shaped smooth muscle cells (SMC) nested in dilated vascular structures with prominent endothelial cells. SMA immunohistochemistry stained positive in tumoral SMC and the vascular smooth muscle layer. SMA positivity suggested leiomyoma.(Fig. 3) The postoperative recovery of the patient was uneventful and his sutures were removed after 7 days. The patient remained free of recurrence after one year of follow-up.

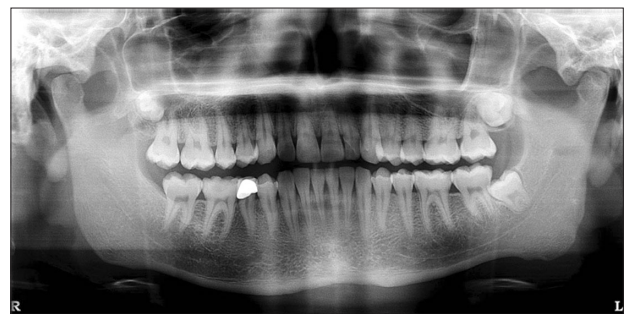

**Fig. 1.** Clinical view of Case 1.  
Osman Fatih Arpağ et al: Angioleiomyoma of the gingiva: a report of two cases. J Korean Assoc Oral Maxillofac Surg 2016

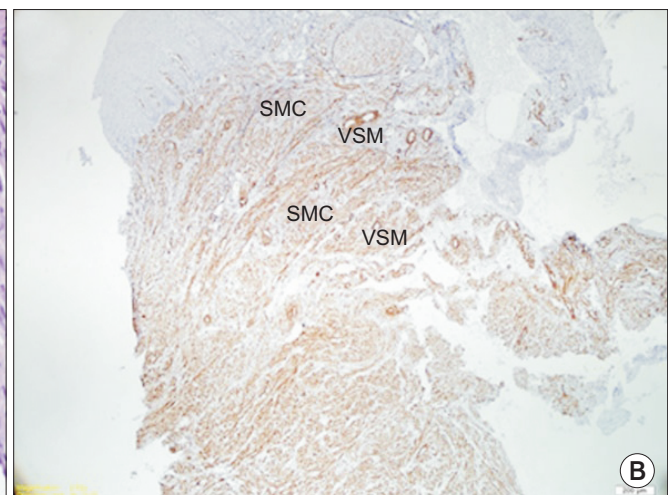
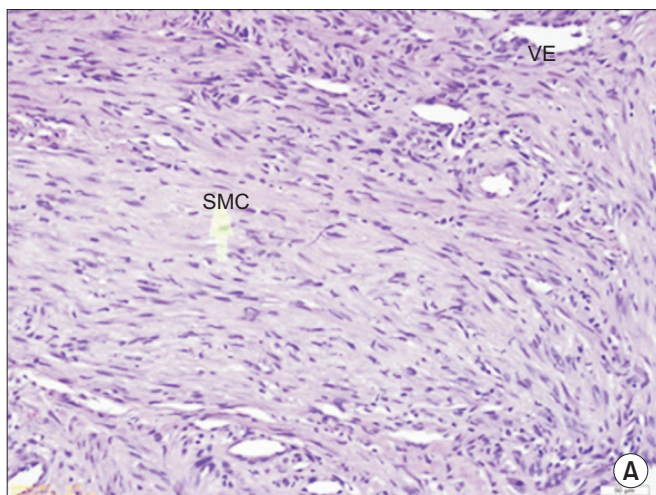
## 2. Case 2

A 55-year-old female patient was referred to Department of Oral and Maxillofacial Surgery, Faculty of Dentistry, Mustafa Kemal University for a routine dental examination. Upon examination, a 15×20 mm diameter, painless gingival swelling was detected in the maxillary first molar region. The lesion was bluish in hue and well circumscribed. The lesion also demonstrated multiple blood vessels with thickened walls.(Fig. 4) Radiographic examination did not show any changes in the associated bone.(Fig. 5)

Total excision of the mass was performed under local anesthesia. An elliptical incision was made to fully enucleate the lesion along with the overlying mucosa. After the excision was completed, we observed an exostosis of the alveolar bone. The exostosis was surgically removed with a round burr and micromotor. The excised lesion was placed in

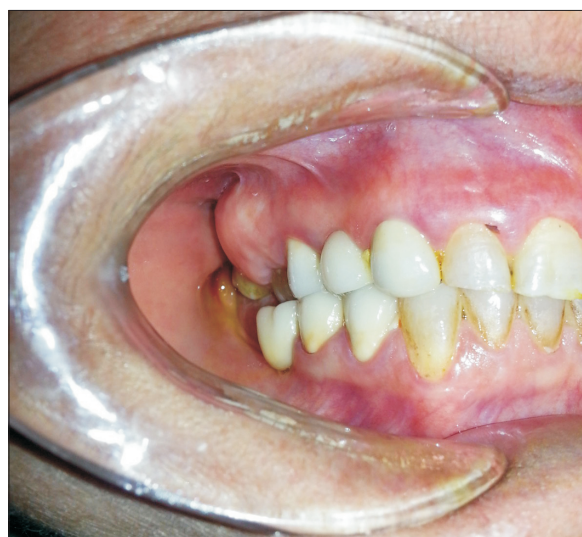

**Fig. 2.** Radiographic view of Case 1.  
Osman Fatih Arpağ et al: Angioleiomyoma of the gingiva: a report of two cases. J Korean Assoc Oral Maxillofac Surg 2016



**Fig. 3.** A. The tumour is formed by interlacing bundles of SMC (H&E staining, ×200). B. The tumour cells are immunoreactive for smooth muscle actin (SMA staining, ×100) in Case 1. (SMC: smooth muscle cell, VE: vascular endothelium, VSM: vascular smooth muscle)  
Osman Fatih Arpağ et al: Angioleiomyoma of the gingiva: a report of two cases. J Korean Assoc Oral Maxillofac Surg 2016

10% buffered formalin solution and sent for histopathological assessment. H&E and SMA staining revealed positivity of SMA suggesting angioleiomyoma. The histopathological findings of this case were similar to those of Case 1.(Fig. 6) During the postoperative period the patient received amoxicillin 1 g/12 hr per oral for 7 days, dexketoprofen as an analgesic and chlorhexidine gluconate rinse (0.12%). Sutures were removed after 7 days. The surgical site healed uneventfully without recurrence over a period of 4-month follow-up.

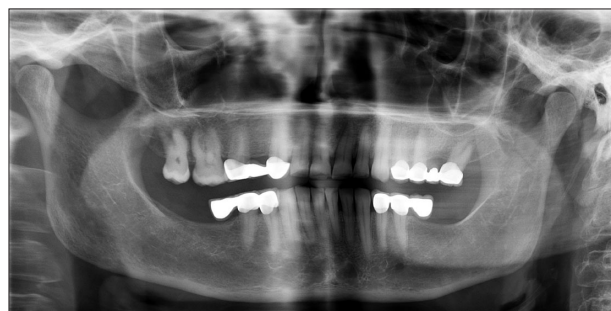

**Fig. 4.** Clinical view of Case 2.

Osman Fatih Arpağ et al: Angioleiomyoma of the gingiva: a report of two cases. *J Korean Assoc Oral Maxillofac Surg* 2016

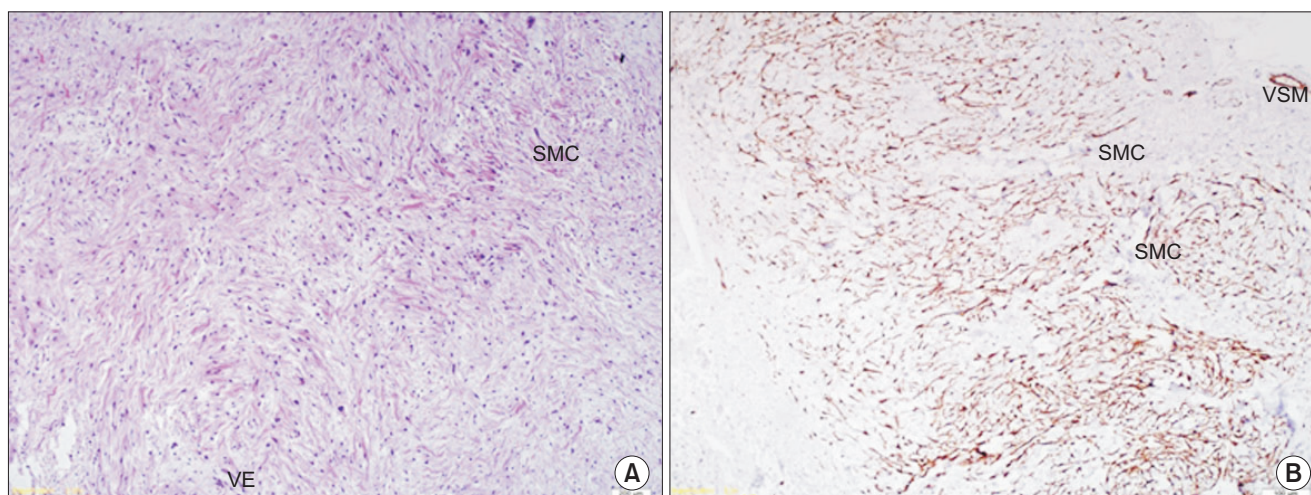
### III. Discussion

Leiomyoma occurs in all age groups, but its greatest prevalence is in adults 40 to 59 years of age is more common in females. One of our cases was fully compatible with this profile. Leiomyomas in the oral region are usually found on the lips, tongue, palate, and buccal mucosa. Brooks et al.<sup>6</sup> reported that the most frequently affected site was the lip (48.6%), followed by the palate (21.1%), buccal mucosa and tongue (each 9.2%), mandible (8.3%), and buccal sulcus, labial sulcus, floor of mouth, and gingiva (each 0.9%). The WHO classifies leiomyoma into three groups including angioleiomyoma (74%), solid leiomyoma (25%), and epithelioid leiomyoma (1%). Angioleiomyoma occurs more frequently than non-vascular and epithelioid forms<sup>7</sup>. Both of the cases described in this report involved gingival angioleiomyoma, which is one of the most common forms of leiomyoma.



**Fig. 5.** Radiographic view of Case 2.

Osman Fatih Arpağ et al: Angioleiomyoma of the gingiva: a report of two cases. *J Korean Assoc Oral Maxillofac Surg* 2016



**Fig. 6.** A. The tumour is formed by interlacing bundles of SMC (H&E staining,  $\times 200$ ). B. The tumour cells are immunoreactive for smooth muscle actin (SMA staining,  $\times 100$ ) in Case 2. (SMC: smooth muscle cell, VE: vascular endothelium, VSM: vascular smooth muscle)

Osman Fatih Arpağ et al: Angioleiomyoma of the gingiva: a report of two cases. *J Korean Assoc Oral Maxillofac Surg* 2016

Oral angioleiomyoma is rare due to the deficiency of smooth muscles in this area found associated with the tunica media layer of blood vessels, circumvallate papillae of the ductus lingualis, and heterotrophic smooth muscle<sup>4</sup>. In histologic sections, the walls of small blood vessels stained positively with hematoxylin-eosin and SMA. Therefore, we conclude that the angioleiomyomas, which were localized in the gingiva, originated from the smooth muscle of blood vessels due to the absence of smooth muscles except for blood vessels in the gingiva and their immediate vicinity.

The differential diagnosis in similar cases should include benign lesions such as fibroma, neurofibroma, myofibroma, fibrous histiocytoma, mucocele, schwannoma, and malignant tumors such as leiomyosarcoma<sup>8</sup>. Due to the similarities between these tumors, the diagnosis of leiomyomas can only be made histopathologically<sup>4</sup>. In such cases, histopathological SMA positivity may be used to rule out the tumors that do not originate from the smooth muscle. Hematoxylin eosin staining has also been used to distinguish between benign and malignant conditions. Although the malignant transformation of angioleiomyoma is very rare<sup>9</sup> there are several case studies describing angioleiomyosarcoma in the literature (added). In the majority of reported cases, angioleiomyomas are characterized by slow growing masses, firm to the touch with color depending on depth and vascularity. Such tumors are usually asymptomatic, but some may cause pain and complicate swallowing. They average in size between 1 to 2 cm and typically present with a history of less than one year<sup>10,11</sup>.

Both the masses in our cases were positioned in the buccal gingiva and of normal size, sessile, and caused slight soreness. Although ulceration is not observed very often in leiomyoma<sup>12</sup>, one of our cases exhibited ulceration on the surface of the mass that may have arisen from trauma to the lesion during eating and mastication.

When tumors exhibit ulceration and are located in the gingiva or palate adjacent to the gingival sulcus they may be confused with periodontal lesions. In one of our cases, the lesion resembled a localized periodontal abscess. However, neither case exhibited pus, bone loss, or deep periodontal pockets typical of periodontal abscesses. Clinically, 55.9% of angioleiomyomas are red in color, while the remainder are gray, white, or normal mucosal color. Radiographically, leiomyomas emerging in the gingiva cause bone loss and tooth mobility<sup>13</sup>.

We observed no mobility in teeth adjacent to the masses in our patients. In addition, bone loss was not detected on radiological examination, and the bone exposed during surgery

was healthy and normal in appearance.

The treatment of choice for angioleiomyomas is total surgical excision. Although these lesions are vascular in origin, during excision there is typically no excessive bleeding<sup>4</sup>. In our cases, the time and the severity of bleeding were within normal limits. The recurrence of this tumor after surgery is extremely rare, with recurrence within two weeks after the surgical incision indicating incomplete resection<sup>14</sup>. Thus, it is important to ensure total resection with a border of healthy tissue to avoid recurrences.

## Conflict of Interest

No potential conflict of interest relevant to this article was reported.

## ORCID

Osman Fatih Arpağ, <http://orcid.org/0000-0002-1510-8917>

Ibrahim Damlar, <http://orcid.org/0000-0003-1453-5391>

Soydan Kılıç, <http://orcid.org/0000-0002-1552-4232>

Ahmet Altan, <http://orcid.org/0000-0003-2041-6364>

Zeynel Abidin Taş, <http://orcid.org/0000-0002-5504-4487>

Tümay Özgür, <http://orcid.org/0000-0002-5291-4483>

## References

1. Regezzi JA, Sciubba JJ, Jordan RCK. Oral pathology: clinical pathologic correlations. 4 ed. Missouri: Saunders; 2003.
2. Bhattacharyya I, Summerlin DJ, Cohen DM, Ellis GL, Bavitz JB, Gillham LL. Granular cell leiomyoma of the oral cavity. *Oral Surg Oral Med Oral Pathol Oral Radiol Endod* 2006;102:353-9.
3. Nam OH, Kim MS, Fung WC, Ahn SH, Ro HS, Chang EY. A case of oral leiomyoma. *J Korean Assoc Oral Maxillofac Surg* 2002;28:484-7.
4. Veeresh M, Sudhakara M, Girish G, Naik C. Leiomyoma: a rare tumor in the head and neck and oral cavity: report of 3 cases with review. *J Oral Maxillofac Pathol* 2013;17:281-7.
5. Damlar I, Kisa H, Tatli U, Altan A, Hakverdi S. Oral angioleiomyoma of the lower lip: a case report. *J Clin Anal Med* 2014. doi: 10.4328/JCAM.2544.
6. Brooks JK, Nikitakis NG, Goodman NJ, Levy BA. Clinicopathologic characterization of oral angioleiomyomas. *Oral Surg Oral Med Oral Pathol Oral Radiol Endod* 2002;94:221-7.
7. Menditti D, Laino L, Nastri L, Caruso U, Fiore P, Baldi A. Oral angioleiomyoma: a rare pathological entity. *In Vivo* 2012;26:161-3.
8. Arruda MM, Monteiro DY, Fernandes AM, Menegatti V, Thomazzi E, Hubner RA, et al. Angioleiomyoma of the nasal cavity. *Int Arch Otorhinolaryngol* 2014;18:409-11.
9. Mahima VG, Patil K, Srikanth HS. Recurrent oral angioleiomyoma. *Contemp Clin Dent* 2011;2:102-5.
10. Liang H, Frederiksen NL, Binnie WH, Cheng YS. Intraosseous oral leiomyoma: systematic review and report of one case. *Dentomaxillofac Radiol* 2003;32:285-90.
11. Wertheimer-Hatch L, Hatch GF 3rd, Hatch B S KF, Davis GB,

- Blanchard DK, Foster RS Jr, et al. Tumors of the oral cavity and pharynx. *World J Surg* 2000;24:395-400.
12. Choe KS, Sclafani AP, McCormick SA. Angioleiomyoma of the auricle: a rare tumor. *Otolaryngol Head Neck Surg* 2001;125:109-10.
  13. Koca H, Guneri P, Cetingol E, Onal T. A very rare of leiomyoma: mandibular angioleiomyoma. *Int J Pediatr Otorhinolaryngol Extra* 2006;1:110-4.
  14. Svane TJ, Smith BR, Cosentino BJ, Cundiff EJ, Ceravolo JJ Jr. Oral leiomyomas. Review of the literature and report of a case of palatal angioleiomyoma. *J Periodontol* 1986;57:433-5.