

A little-known relationship between immune recovery syndrome and herpes zoster

Supriya Bhandage¹, Manjunath Kurki¹, Vagdevi Hosur², Piyush Sukhija³, Atul Bajoria³

Departments of¹Oral and Maxillofacial Surgery, ²Orthodontics, and³Oral Medicine, Sri Hasanamba Dental College and Hospital, Hassan, India

Abstract (J Korean Assoc Oral Maxillofac Surg 2016;42:169-172)

Following anti-retroviral therapy (ART) or highly active antiretroviral therapy, there is an increased response to latent infections such as herpes zoster, which may lead to their reactivation. This is a result of improved immunity brought about by ART, also termed immune recovery syndrome. A 75-year-old male patient arrived at our institute with widespread vesicles and scabs on the right half of his face and oral cavity, suggesting the involvement of the trigeminal nerve. The patient had a history of being on ART two months earlier and a history of tooth extraction eight days prior to his arrival at our institute. The incidence of human immunodeficiency virus (HIV)-positive cases amongst herpes zoster cases is high, and these patients become susceptible to infections following ART. Therefore, regardless of the presence of risk factors, every herpes zoster patient should be tested for HIV infection, and high anti-retroviral therapy should be commenced/reinstated as soon as possible. In addition, the treating physician should maintain a high level of vigilance for the patient during the first few months of ART, the peak incidence of immune recovery inflammatory disease.

Key words: Herpes zoster, HIV, Immune recovery syndrome, Anti-retroviral therapy

[paper submitted 2015. 7. 1 / revised 2015. 10. 8 / accepted 2015. 10. 19]

I. Introduction

Herpes zoster is a reactivation of the latent varicella zoster virus in the dorsal spinal ganglion that is initiated by triggering factors such as trauma, aging, an immunocompromised state, malignancy, and radiotherapy. When reactivated, the virus replicates, resulting in inflammation, host cell death, and transportation of the virus along the axonal length of the sensory nerves to the skin. Patients clinically present with early symptoms of dysesthesia, tingling sensations, numbness, and itching, followed by the characteristic appearance of a rash in a few days. Vesicle formation is seen along the course of the nerve in a week to 10 days. These vesicles transform into bullae and eventually burst open to form scabs. When the trigeminal ganglion is involved, the pain produced by the in-

fection can mislead clinicians into diagnosing the disorder as trigeminal neuralgia or odontalgia.

Herpes zoster may produce complications such as blindness as seen in trigeminal ophthalmicus¹, acute or chronic encephalitis, myelitis, retinitis, autonomic dysfunction, motor neuropathies, Guillain-Barré syndrome, hemiparesis, and cranial or peripheral nerve palsies². More common complications include bacterial superinfection of the scabs by *Staphylococcus aureus* or *Streptococcus pyogenes*, scarring, and hyperpigmentation.

Individuals infected with human immunodeficiency virus (HIV) show a higher prevalence for zoster infection than the general population¹. Therefore, it is imperative to test every patient with zoster for HIV. Although a reduction in immunity is considered the rationale for this feature, it has not been well documented in the literature that individuals on anti-retroviral therapy (ART) experience a condition known as immune reconstitution inflammatory syndrome. During the first two months post-ART or due to the change to a highly active antiretroviral therapy (HAART), the patient's immunity tends to improve and respond better to latent infections, resulting in the manifestation of the infection. Also called immune recovery syndrome, HAART is characterized by an increase in the CD4 count and a significant reduction in the viral load³⁻⁵.

Supriya Bhandage

Department of Oral and Maxillofacial Surgery, Sri Hasanamba Dental College and Hospital, P.B. No. 86, Vidyanagar, Hassan, Karnataka 573202, India

TEL: +91-081722-67843

E-mail: Supriyagb11@gmail.com

ORCID: <http://orcid.org/0000-0001-9929-6427>

©This is an open-access article distributed under the terms of the Creative Commons Attribution Non-Commercial License (<http://creativecommons.org/licenses/by-nc/4.0/>), which permits unrestricted non-commercial use, distribution, and reproduction in any medium, provided the original work is properly cited.

Copyright © 2016 The Korean Association of Oral and Maxillofacial Surgeons. All rights reserved.

1. Demography/epidemiology

The National AIDS Control Organisation (NACO), a government initiative launched in 1992 to prevent and control HIV infection in India, estimated the epidemiological status of HIV/AIDS in 2012 as 20.89 lakh. The immunocompromised state in HIV patients makes them susceptible to various infections, including shingles or herpes zoster. A study carried out from 2004 to 2005 in Karnataka, India, confirmed that out of 90 reported herpes zoster infections, 37.77% were sero-positive cases of HIV⁶. Thoracic and lumbar dermatomes are commonly affected, and the trigeminal nerve is involved in 13% of patients⁷. Currently, no evidence-based pharmacological strategy or a definitive guideline table for the prevention of immune reconstitution inflammatory disease can be recommended, as none of the pharmacological clinical trials have been completed. Clinical trials involving the use of Maraviroc, a CCR5 chemokine receptor antagonist and a nonsteroidal anti-inflammatory drug (NSAID), are currently ongoing. Statins, vitamin D, and corticosteroids have also been suggested as other possible immune recovery inflammatory disease prevention strategies⁸. Since the early initiation of ART is not always possible due to a lack of awareness and economical limitations, a late presentation along with advanced HIV leads to high rates of opportunistic infections in these patients.

2. Etiology/pathogenesis

Herpes zoster is a reactivation of the latent varicella zoster virus in the dorsal spinal ganglion initiated by triggering factors such as trauma, aging, an immunocompromised state, malignancy, and radiotherapy. When reactivated, the virus replicates, producing inflammation and host cell death. The virus is transported along the axonal length of the sensory nerves to the skin and clinically presents with early symptoms of dysesthesia, tingling sensations, numbness, and itching; a characteristic rash appears after a few days. Vesicle formation is seen along the course of the nerve in a week to 10 days. These vesicles transform into bullae and eventually burst open to form scabs. When the trigeminal ganglion is involved, the pain produced by the infection can mislead clinicians to diagnose it as trigeminal neuralgia or odontalgia.

II. Case Report

1. Clinical presentation

A 75-year-old male patient visited the hospital with a chief complaint of pain in the entire right half of his face for the past eight days. The pain was accompanied by burning and a tingling sensation. The patient revealed a history of extraction of the right maxillary third molar tooth eight days before at a private clinic. His pain was severe in intensity and continuous in frequency, radiating to the forehead on the same side. There was no history of fever or lymphadenopathy. The patient had been on ART two months earlier for a period of three months, which was revealed only after the results of the investigations were obtained.

The patient was conscious, delirious, irritable, and appeared tired and distressed. He was moderately built and poorly nourished. There was history of a loss of appetite and weakness for the past six months. On examination, multiple cutaneous vesicles and scabs covered the same side of his cheek, ear, upper and lower lips, chin, and submandibular region.(Fig. 1) Mild diffuse swelling on the right half of the lips was noted, and generalized ulceration of the right buccal and labial mucosa was present.(Fig. 2, 3) Ulcerations on the anterior two-thirds of the right half of the tongue, lingual mucosa, tonsillar pillars, and the soft palate were also present. The ulcers were irregular and more than a centimeter in size and were covered with slough. The patient also complained

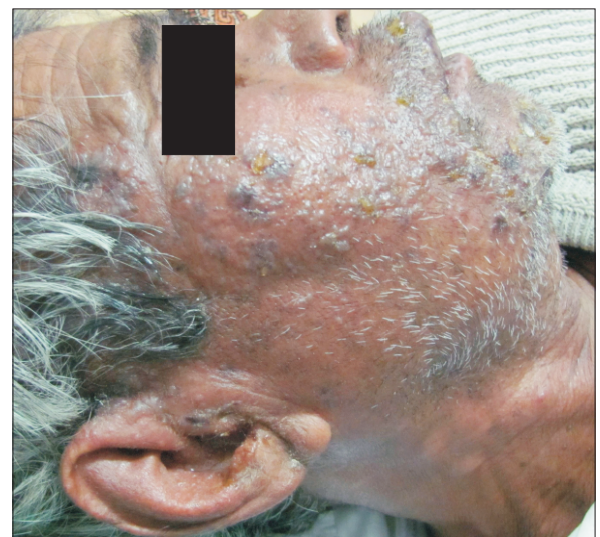

Fig. 1. Herpetic lesions involving the maxillary and mandibular divisions.

Supriya Bhandage et al: A little-known relationship between immune recovery syndrome and herpes zoster. J Korean Assoc Oral Maxillofac Surg 2016

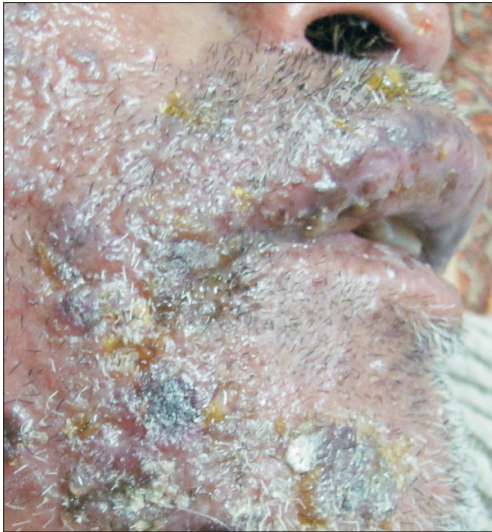


Fig. 2. Multiple scabs and vesicles.
Supriya Bhandage et al: A little-known relationship between immune recovery syndrome and herpes zoster. J Korean Assoc Oral Maxillofac Surg 2016

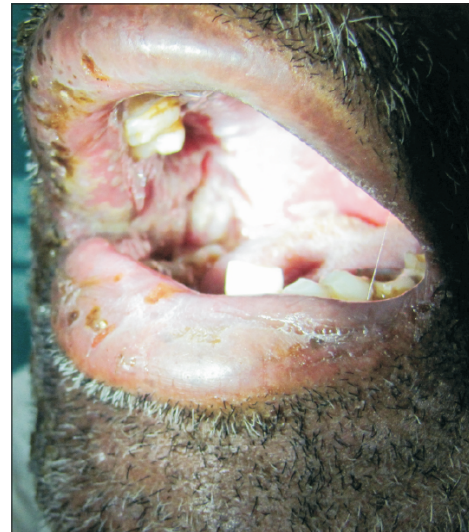

Fig. 3. Intraoral ulcerations with sloughing.
Supriya Bhandage et al: A little-known relationship between immune recovery syndrome and herpes zoster. J Korean Assoc Oral Maxillofac Surg 2016

of restriction in his jaw opening due to severe pain. There were no signs of systemic dissemination.

2. Investigations

Herpes simplex is the most common skin infection that presents a clinical picture similar to herpes zoster; others include impetigo, contact dermatitis, folliculitis, scabies, insect bites, papular urticaria, candidal infection, and dermatitis herpetiformis. Immune suppression also may have an atypical presentation. Therefore, laboratory testing with polymerase chain reaction, direct fluorescent antibody staining, and immunoglobulin M enzyme-linked immunosorbent assay (ELISA) have proven useful for such cases. A history of or exposure to the zoster virus or the clinical presentation of a rash with a dermatomal pattern helps distinguish varicella infection from disseminated herpes zoster. In this case, the patient had a distinct pattern of lesions along the sensory distribution of the maxillary and mandibular nerves. His laboratory report showed a marked decrease in his lymphocyte count, and he tested positive for HIV.

3. Management

Anti-inflammatory drugs such as corticosteroids are reserved for mild to moderate symptoms of pain. Any interruption of ART during the phase of opportunistic infection is not recommended unless it is a life-threatening opportunistic infection because the cessation of ART can lead to ART re-

sistance. Since the patient was immunocompromised, the recommended oral dosage of 1,000 mg of Acyclovir three times a day for seven days was prescribed. A topical application of acyclovir was also prescribed. Tramadol infusions in saline were administered to relieve the pain. The patient was treated for the next two days and then was discharged against medical advice since he wanted to be admitted to a government hospital. The patient was therefore referred to a government hospital for continuation of the ART.

III. Discussion

A reactivation of the zoster virus in the nerve ganglia can be precipitated by many triggering factors, such as aging, trauma, immunosuppression, malignancy, and radiotherapy. The patient in our case report had a history of trauma following a tooth extraction, which triggered the reactivation of the latent virus.

Treatment of herpes zoster consists of antivirals such as acyclovir and famciclovir. Although these drugs should theoretically be started within 72 hours of onset of rash, they should be initiated even in cases with delays, as they reduce the duration of viral shedding and also the severity and progression of the infection. Corticosteroids, analgesics, and topical agents such as lignocaine are adjuvants that can be administered to reduce the pain and severity of the infection. Patients who experience insomnia due to the discomfort may also benefit from tricyclic anti-depressants.

The diagnosis of herpes zoster should prompt the clinician

to consider HIV testing if risk factors, such as an age of less than 50 years or multi-dermatomal lesions, are present. None of these risk factors were positive in our patient. He belonged to an older age group (75 years), and only his facial skin was affected, suggesting that clinicians cannot always narrow down the probability of HIV infection based upon its relation with risk factors. It is imperative that every patient with zoster infection be tested for HIV infection regardless of their absence of risk factors. Recognition of an underlying immunocompromised state is important. It is a lesser-known fact that ART causes a manifestation of latent infections³⁻⁵ such as herpes zoster as a result of immune recovery, as seen in this case report. A high vigilance for the patient by the treating physician during the first few months of ART, during which there is a peak incidence of immune recovery inflammatory disease, is recommended. All patients who present with a zoster should be questioned regarding their history of ART.

Conflict of Interest

No potential conflict of interest relevant to this article was reported.

ORCID

Supriya Bhandage, <http://orcid.org/0000-0001-9929-6427>

Manjunath Kurki, <http://orcid.org/0000-0003-1445-3089>

Vagdevi Hosur, <http://orcid.org/0000-0003-0412-0846>

Piyush Sukhija, <http://orcid.org/0000-0002-4951-4382>

Atul Bajoria, <http://orcid.org/0000-0001-9796-9640>

References

1. Wiafe B. Herpes zoster ophthalmicus in HIV/AIDS. *Community Eye Health* 2003;16:35-6.
2. Gnann JW Jr. Varicella-zoster virus: atypical presentations and unusual complications. *J Infect Dis* 2002;186 Suppl 1:S91-8.
3. Immune reconstitution syndrome [Internet]. Washington (DC): AIDS InfoNet [cited 2015 Jun 15]. Available from: http://aidsinfonet.org/uploaded/factsheets/85_eng_483.pdf.
4. Immune Reconstitution Inflammatory Syndrome (IRIS) in HIV-Infected Patients [Internet]. New York (NY): New York State Department of Health AIDS Institute [cited 2015 Jun 15]. Available from: <http://www.hivguidelines.org/clinical-guidelines/adults/immune-reconstitution-inflammatory-syndrome-iris-in-hiv-infected-patients/>.
5. Martínez E, Gatell J, Morán Y, Aznar E, Buira E, Guellar A, et al. High incidence of herpes zoster in patients with AIDS soon after therapy with protease inhibitors. *Clin Infect Dis* 1998;27:1510-3.
6. Naveen KN, Tophakane RS, Hanumanthayya K, Pv B, Pai VV. A study of HIV seropositivity with various clinical manifestation of herpes zoster among patients from Karnataka, India. *Dermatol Online J* 2011;17:3.
7. Millar EP, Troulis MJ. Herpes zoster of the trigeminal nerve: the dentist's role in diagnosis and management. *J Can Dent Assoc* 1994;60:450-3.
8. Lawn SD, Meintjes G. Pathogenesis and prevention of immune reconstitution disease during antiretroviral therapy. *Expert Rev Anti Infect Ther* 2011;9:415-30.