



Verruciform xanthoma in the hard palate: a case report and literature review

Alexandre Simões Garcia, Otávio Pagin, Paulo Sérgio da Silva Santos, Denise Tostes Oliveira

Department of Surgery, Stomatology, Pathology and Radiology, Bauru School of Dentistry, University of São Paulo, Bauru, Brazil

Abstract (J Korean Assoc Oral Maxillofac Surg 2016;42:383-387)

Oral verruciform xanthoma (OVX) is an uncommon lesion that appears on the oral mucosa. The aim of this paper was to discuss the probable etiopathogenesis of OVX in the hard palate, reinforcing the importance of including this lesion in the differential diagnosis of verrucous lesions. A 43-year-old male smoker presented with a painless lesion with a verrucous surface and erythematous spots on the hard palate. Excisional biopsy revealed oral mucosa consisting of hyperkeratosis, acanthosis, and elongated rete pegs. Subjacent connective tissue showed numerous foam cells with clear cytoplasm and pyknotic nucleus, negative on periodic acid-Schiff staining. Immunohistochemical analysis revealed foam cells positive for anti-CD68 antibody, while anti-KI-67 antibody was restricted to the basal layer of the oral epithelium. A final diagnosis of OVX was established. The patient showed no signs of recurrence after seven months of follow-up. Physical trauma and smoking habits can be directly related to the etiology of verruciform xanthoma because the lesion is chronic and inflammatory with slow growth, and sites of high trauma are more often affected by such a lesion. The hard palate is the second most commonly affected site, and local trauma caused by smoking can be a cause of this type of lesion.

Key words: Xanthomatosis, Hard palate, Immunohistochemistry

[paper submitted 2016. 1. 26 / revised 2016. 4. 2 / accepted 2016. 4. 5]

I. Introduction

Oral verruciform xanthoma (OVX) is an uncommon lesion described by Shafer in 1971¹, that appears on oral mucosa as a reactive lesion. The etiopathogenesis of this lesion remains unclear, with reaction response to trauma the most accepted explanation². Contrary to skin xanthomas that are associated with metabolic disturbances of lipids, OVXs are not related to any generalized disease³.

This lesion may occur anywhere in the oral mucosa, but the hard palate is the second most commonly affected site, representing approximately 15% of all cases in a large survey⁴.

The treatment for OVX is surgical resection, and recur-

rence is extremely rare⁴. Interestingly, the three recurrence case reports in the English literature occurred in the hard palate⁵⁻⁷.

The aim of this paper was to discuss the probable etiopathogenesis of OVX in the hard palate, reinforcing the importance of including this benign lesion in the differential diagnosis of verrucous lesions in this location.

II. Case Report

A 43-year-old man presented with a painless lesion in the hard palate, discovered during routine examination two months before. Clinically, a lesion with a verrucous surface and erythematous spots was observed next to the first upper right molar, measuring approximately 5 mm in diameter. (Fig. 1) The patient was a current smoker. The presumptive diagnosis was squamous cell carcinoma or traumatic ulcer. Excisional biopsy was performed, and the surgical specimen was sent to the Bauru School of Dentistry Oral Pathology Biopsy Service of the University of São Paulo (Bauru, Brazil). Histopathological examination revealed oral mucosa consisting of hyperkeratosis, acanthosis, and elongated rete pegs. Subjacent connective tissue showed numerous foam cells with

Alexandre Simões Garcia

Department of Surgery, Stomatology, Pathology and Radiology, Bauru School of Dentistry, University of São Paulo, Alameda Octávio Pinheiro Brisolla, 9-75, Bauru, São Paulo 17012-901, Brazil

TEL: +55-21-14-32358251 FAX: +55-21-14-32234679

E-mail: alexsg@fob.usp.br

ORCID: <http://orcid.org/0000-0002-5630-1983>

©This is an open-access article distributed under the terms of the Creative Commons Attribution Non-Commercial License (<http://creativecommons.org/licenses/by-nc/4.0/>), which permits unrestricted non-commercial use, distribution, and reproduction in any medium, provided the original work is properly cited.

Copyright © 2016 The Korean Association of Oral and Maxillofacial Surgeons. All rights reserved.

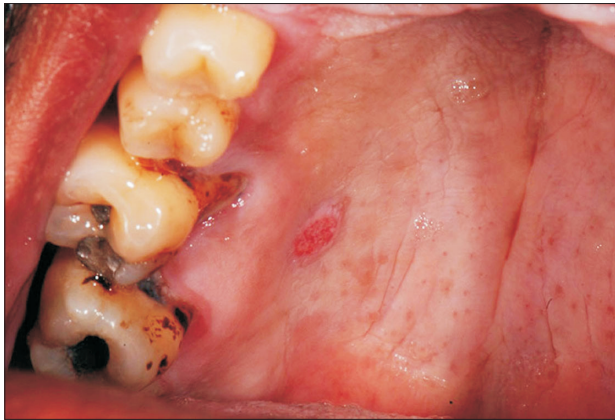

Fig. 1. Clinical appearance of the lesion on the hard palate showing verrucous surface and erythematous spots, measuring approximately 5 mm in diameter.

Alexandre Simões Garcia et al: Verruciform xanthoma in the hard palate: a case report and literature review. J Korean Assoc Oral Maxillofac Surg 2016

clear cytoplasm and pyknotic nucleus, negative on periodic acid-Schiff staining.(Fig. 2. A, 2. B) Immunohistochemical analysis revealed that foam cells were positive for anti-CD68 antibody (Fig. 2. C), and anti-KI-67 antibody was restricted to the basal layer of the oral epithelium and negative for foam cells.(Fig. 2. D) Based on clinical and microscopic features, the final diagnosis of OVX was established. After seven months of follow-up, the patient showed no signs of recurrence.(Fig. 3)

III. Discussion

OVX is an uncommon lesion that was first described by Shafer in 1971¹. It typically presents as a single lesion, the color of normal oral mucosa with verrucous surface, affecting

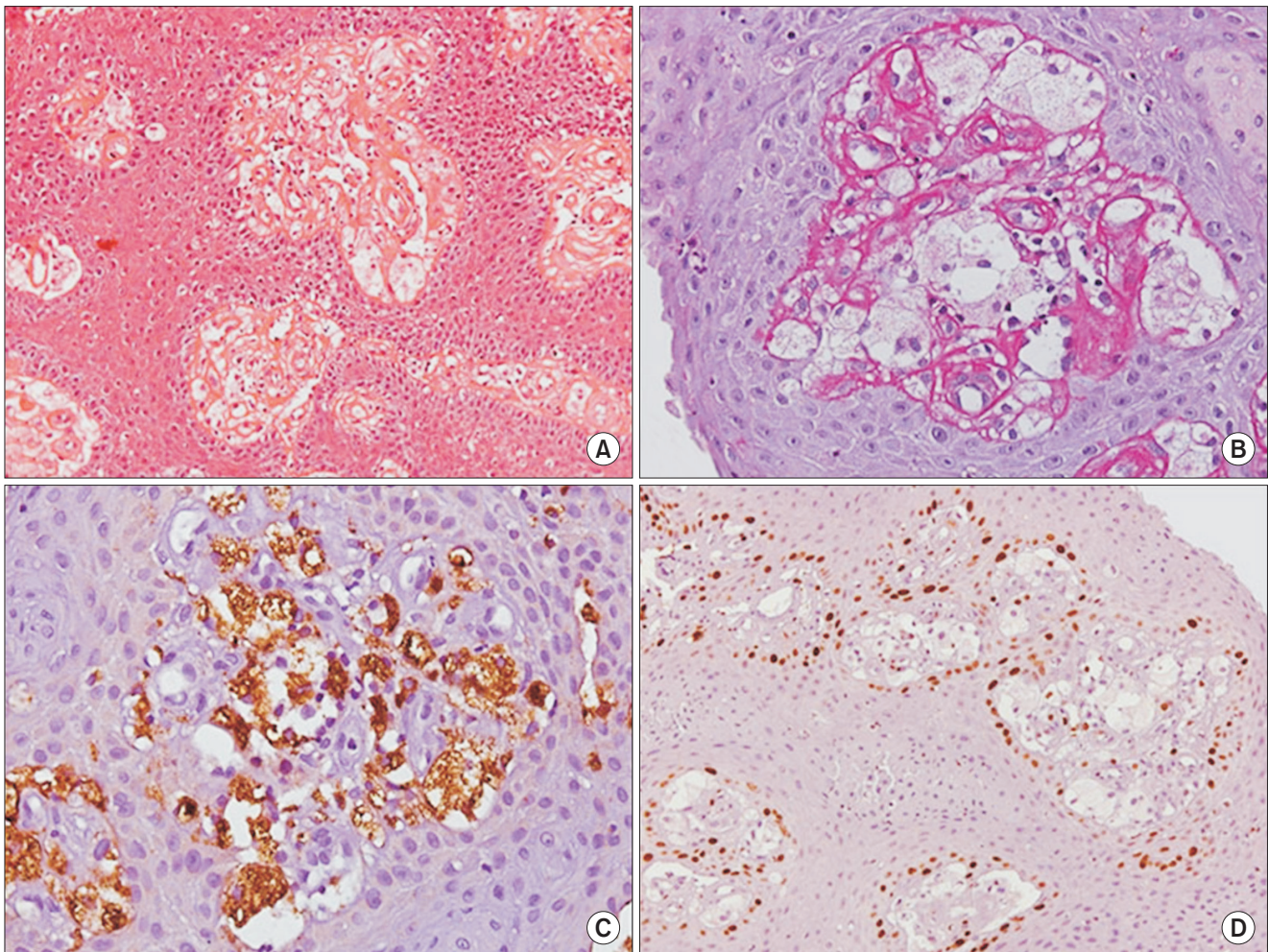


Fig. 2. Histopathological features of the verruciform xanthoma showing hyperkeratosis, acanthosis, elongated rete pegs and numerous foam cells with clear cytoplasm and pyknotic nucleus in the connective tissue (H&E staining, $\times 200$; A), foam cells showing negative for periodic acid-Schiff (PAS staining, $\times 400$; B), foam cells positive for anti-CD68 antibody (anti-CD68 staining, $\times 400$; C), basal layer of the oral epithelium positive to KI-67 and negative for foam cells (anti-KI-67 staining, $\times 200$; D).

Alexandre Simões Garcia et al: Verruciform xanthoma in the hard palate: a case report and literature review. J Korean Assoc Oral Maxillofac Surg 2016

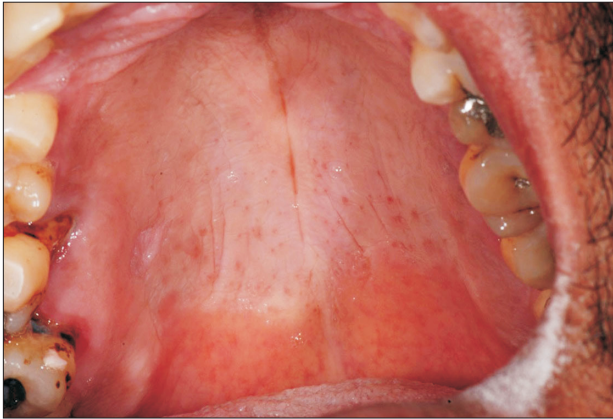

Fig. 3. Seven months of follow-up, no recurrences.
Alexandre Simões Garcia et al: Verruciform xanthoma in the hard palate: a case report and literature review. *J Korean Assoc Oral Maxillofac Surg* 2016

mostly individuals over 40 years^{4,8}. It can be confused clinically with verruca vulgaris, traumatic ulcers, and squamous cell carcinoma.

Histologically, it is characterized by hyperkeratosis, elongated rete pegs, and aggregates of foam cells in the submucosal stroma without epidermal atypia. Foam cells of verruciform xanthoma are of monocyte-macrophage lineage, based on intense cytoplasmic positivity for anti-CD68 and cathepsin B^{9,10}.

The hard palate is the second most common area affected by OVX⁴. The relationship of this lesion with local trauma can explain why the gums and hard palate are impacted. The trauma induced by cigarettes in this location may also be involved in this lesion. Interestingly, the only three reports of recurrent OVX are in the hard palate⁵⁻⁷. This finding reinforces that areas experiencing excessive trauma are more affected by OVX.

OVX usually presents as a small solitary, sessile, or pedunculated lesion with a rough, slightly elevated surface and tends to be asymptomatic. The prevalence of OVX is unknown, although a relative frequency rate of 0.025% to 0.05% has been reported in the literature^{2,11}. Such lesions occur most often on the gingiva, followed by hard palate, tongue, buccal mucosa, floor of the mouth, and soft palate⁴.

Philipsen et al.⁴ showed in a large survey that OVX are common in men below the age of 50 years. In the present case, the patient was a 43-year-old male smoker who presented with a 0.5 cm lesion in the hard palate of two months duration.

We found 12 studies in the literature reporting verruciform xanthoma in the hard palate^{6,8,12-21}. Articles without clinical information, immunohistochemical studies, multiple lesions,

or involving the soft palate were excluded. The results are shown in Table 1.

Men were twice as likely to be affected than women (2:1). Lesions were normally small (average size of lesions 0.85 cm); however, three OVX lesions were 2 cm or more. The lesion surface was mostly verrucous. Older patients in the 40 to 90 year age range (mean age, 54 years) were significantly more frequently affected than younger patients. Almost 63% of the patients were smokers (5 of the 8 cases).

This case reinforces that OVX in the hard palate presents as small, painless lesions and affects men below 50 years. The influence of smoking habits is discussed below.

The diagnostic hallmark of OVX is the presence of lipid-laden macrophages in the connective tissue between the epithelial ridges^{2,4,16}. An extensive immunohistochemical study showed that foam cells are of monocyte-macrophage lineage based on intense cytoplasmic positivity for anti-CD68 and cathepsin B⁹. Rawal et al.¹⁰ demonstrated that macrophages present in OVX are primarily reparative and resident, supporting the chronic reactive nature of OVX. In this case, a large number of xanthoma cells with clear cytoplasm and pyknotic nucleus were found. These cells were positive for CD6, confirming them as macrophages. The anti-KI-67 antibody was restricted to the basal layer of the epithelium, showing that the lesion was not malignant.

The pathogenesis of OVX remains unknown. Most patients with OVX do not have hyperlipidemia²². The mechanism of the accumulation of lipid-containing foam cells in the submucosa or dermis is also not clear².

An ultrastructural and immunohistochemical study showed that, after the development of OVX, oxidized low-density lipoprotein (ox-LDL) induces foam cell necrosis, and resident macrophages clean the debris and cyclically perpetuate VX²³. Ultrastructural and in situ hybridization have not shown an association between HPV and OVX, excluding a viral etiology for this lesion²⁴.

Metabolic abnormalities of lipids and lymphedema are associated with nonmucosal cutaneous verruciform xanthoma^{3,25}. The obstruction of lymphatic vessels results in accumulation of lipids in the connective tissue, and these lipids are scavenged by macrophages, producing xanthomas in patients with lymphedema²⁵.

Patients with CHILD syndrome show inactivity of an enzyme related with cholesterol synthesis and interestingly have been reported to have concomitant verruciform xanthoma²⁶.

The association of systemic diseases with cutaneous verruciform xanthoma but not OVX indicates that local trauma

Table 1. Clinical features of verruciform xanthoma in the hard palate

Author	Local	Sex	Age (yr)	Surface	Size (cm)	Evolution (mo)	Smoking
Hume et al. ¹² , 1980	Palatal gingiva	M	60	Verrucous	0.4	3	-
Neville and Weathers ¹³ , 1980	Palatal gingiva	M	59	-	1.0	6	No
	Palate lingual	F	45	-	0.4	-	-
Nowparast et al. ⁶ , 1981	Palate	M	56	-	-	4	-
	Palate	M	24	Papillary	0.7	-	-
	Palate	M	31	Papillary	1.5	-	-
	Palate	F	66	Verrucous	-	-	-
	Palate	M	62	Verrucous	0.3	-	-
	Palate	M	50	Papillary	1.2	-	-
	Palatal junction	F	73	Flat	0.7	-	-
	Palate	M	81	Flat	0.5	-	-
	Palate	F	67	Flat	-	-	-
	Palate	M	89	Verrucous	0.3	-	-
	Palate	F	75	Verrucous	0.3	-	-
	Palate	M	52	Verrucous	1.0	-	-
	Palate	M	77	Verrucous	0.4	-	-
	Palate	F	78	Verrucous	0.4	-	-
	Palate	F	71	Flat	0.5	-	-
Palate	F	39	Verrucous	1.3	-	-	
Palate	F	67	Verrucous	0.5	-	-	
Kakarantza-Angelopoulou et al. ⁸ , 1991	Palate	M	42	Rough	0.7	“Slowly”	-
Rhinow et al. ¹⁴ , 2003	Palate	-	46	Granular	2.0	-	Yes
Hu et al. ¹⁵ , 2005	Palate	M	48	Verrucous	0.3	48	Yes
Yu et al. ¹⁶ , 2007	Palatal gingiva	M	31	Papillary	0.5	-	No
	Palatal gingiva	M	39	Verrucous	0.7	-	Yes
Cheng et al. ¹⁷ , 2010	Palate	M	22	Rough	-	Unknown	-
Shahrabi Farahani et al. ¹⁸ , 2011	Palate	M	45	Granular	0.5	-	-
Ryu et al. ¹⁹ , 2013	Palatal gingiva	M	37	Verrucous/papillary	1.5	12	Yes
	Palatal gingiva	M	35	Verrucous/papillary	2.5	1	Yes
Aggarwal et al. ²⁰ , 2014	Palate	M	46	-	2.0	36	-
Bhattacharyya and Islam ²¹ , 2014	Palate	F	44	-	1.0	2	No
Present case	Palate	M	43	Verrucous	0.5	2	Yes

(M: male, F: female, -: not informed)

Alexandre Simões Garcia et al: Verruciform xanthoma in the hard palate: a case report and literature review. J Korean Assoc Oral Maxillofac Surg 2016

and inflammation are the most likely causes of OVX, since the epithelial cell degeneration caused by this condition releases lipid material that is scavenged by local macrophages. Studies have shown that the macrophages present in OVX are resident, mature, chronic inflammatory macrophages, confirming that is a chronic, slow-growing inflammatory lesion¹⁰.

These findings are consistent with the influence of smoking habits in the pathogenesis of OVX. Local trauma caused by cigarettes, especially in the hard palate, may be associated with OVX development. However, further studies need to be performed to confirm this association.

We did not find specific OVX surveys by location in the literature. The hard palate is the second most affected area, and local trauma caused by smoking can be a cause of this lesion. Knowledge of uncommon lesions in the mouth is extremely important for a correct diagnosis and treatment.

Conflict of Interest

No potential conflict of interest relevant to this article was reported.

ORCID

Alexandre Simões Garcia, <http://orcid.org/0000-0002-5630-1983>

Otávio Pagin, <http://orcid.org/0000-0002-3189-898X>

Paulo Sérgio da Silva Santos, <http://orcid.org/0000-0002-0674-3759>

Denise Tostes Oliveira, <http://orcid.org/0000-0001-6163-5526>

References

1. Shafer WG. Verruciform xanthoma. Oral Surg Oral Med Oral Pathol 1971;31:784-9.
2. Hegde U, Doddawad VG, Sreeshyla H, Patil R. Verruciform xanthoma: a view on the concepts of its etiopathogenesis. J Oral Max-

- illofac Pathol 2013;17:392-6.
3. Zegarelli DJ, Zegarelli-Schmidt EC, Zegarelli EV. Verruciform xanthoma. Further light and electron microscopic studies, with the addition of a third case. *Oral Surg Oral Med Oral Pathol* 1975;40:246-56.
 4. Philipsen HP, Reichart PA, Takata T, Ogawa I. Verruciform xanthoma--biological profile of 282 oral lesions based on a literature survey with nine new cases from Japan. *Oral Oncol* 2003;39:325-36.
 5. Iamaroon A, Vickers RA. Characterization of verruciform xanthoma by in situ hybridization and immunohistochemistry. *J Oral Pathol Med* 1996;25:395-400.
 6. Nowparast B, Howell FV, Rick GM. Verruciform xanthoma. A clinicopathologic review and report of fifty-four cases. *Oral Surg Oral Med Oral Pathol* 1981;51:619-25.
 7. Neville B. The verruciform xanthoma. A review and report of eight new cases. *Am J Dermatopathol* 1986;8:247-53.
 8. Kakarantza-Angelopoulou E, Nicolatou O, Anagnostopoulou S. Verruciform xanthoma of the palate: case report with electron microscopy. *J Oral Maxillofac Surg* 1991;49:409-12.
 9. Mostafa KA, Takata T, Ogawa I, Ijuhin N, Nikai H. Verruciform xanthoma of the oral mucosa: a clinicopathological study with immunohistochemical findings relating to pathogenesis. *Virchows Arch A Pathol Anat Histopathol* 1993;423:243-8.
 10. Rawal SY, Kalmar JR, Tatakis DN. Verruciform xanthoma: immunohistochemical characterization of xanthoma cell phenotypes. *J Periodontol* 2007;78:504-9.
 11. Buchner A, Hansen LS, Merrell PW. Verruciform xanthoma of the oral mucosa. Report of five cases and review of the literature. *Arch Dermatol* 1981;117:563-5.
 12. Hume WJ, Smith CJ, Franklin CD. Verruciform xanthoma. *Br J Oral Surg* 1980;18:157-61.
 13. Neville BW, Weathers DR. Verruciform xanthoma. *Oral Surg Oral Med Oral Pathol* 1980;49:429-34.
 14. Rhinow K, Kalz S, Gelderblom R, Reichart A. Verruciform xanthoma. *Mund Kiefer Gesichtschir* 2003;7:52-5.
 15. Hu JA, Li Y, Li S. Verruciform xanthoma of the oral cavity: clinicopathological study relating to pathogenesis. Report of three cases. *APMIS* 2005;113:629-34.
 16. Yu CH, Tsai TC, Wang JT, Liu BY, Wang YP, Sun A, et al. Oral verruciform xanthoma: a clinicopathologic study of 15 cases. *J Formos Med Assoc* 2007;106:141-7.
 17. Cheng YS, Wright J, Lucente J, McQuade MJ. Oral and maxillofacial pathology case of the month. Verruciform xanthoma. *Tex Dent J* 2010;127:126-7, 130-1.
 18. Shahrabi Farahani S, Treister NS, Khan Z, Woo SB. Oral verruciform xanthoma associated with chronic graft-versus-host disease: a report of five cases and a review of the literature. *Head Neck Pathol* 2011;5:193-8.
 19. Ryu DJ, Lee SH, Yuk JI, Kim HJ, Huh JK, Park KH. Verruciform xanthoma of the palatal gingiva: a report of two cases. *J Korean Assoc Oral Maxillofac Surg* 2013;39:292-6.
 20. Aggarwal S, Aggarwal A, Gill S, Bakshi Y, Singh HP. Verruciform xanthoma of oral cavity- a case report. *J Clin Diagn Res* 2014;8:FD11-2.
 21. Bhattacharyya I, Islam N. Diagnostic discussion. Verruciform xanthoma. *Today's FDA* 2014;26:49-51.
 22. Tang R, Kopp SA, Cobb C, Halpern AV. Disseminated verruciform xanthoma: a case report. *Cutis* 2014;93:307-10.
 23. Ide F, Obara K, Yamada H, Mishima K, Saito I, Kusama K. Cellular basis of verruciform xanthoma: immunohistochemical and ultrastructural characterization. *Oral Dis* 2008;14:150-7.
 24. Sah K, Kale AD, Hallikerimath S. Verruciform xanthoma: report of two cases and review on pathogenesis. *J Oral Maxillofac Pathol* 2008;12:41-4.
 25. Snider RL. Verruciform xanthomas and lymphedema. *J Am Acad Dermatol* 1992;27:1021-3.
 26. Bittar M, Happle R. CHILD syndrome avant la lettre. *J Am Acad Dermatol* 2004;50(2 Suppl):S34-7.