



# The effect of decompression as treatment of the cysts in the jaws: retrospective analysis

Sun-Tae Lee<sup>1</sup>, Su-Gwan Kim<sup>1</sup>, Seong-Young Moon<sup>1</sup>, Ji-Su Oh<sup>1</sup>, Jae-Seek You<sup>1</sup>, Jae-Sung Kim<sup>2</sup>

<sup>1</sup>Department of Oral and Maxillofacial Surgery, School of Dentistry, Chosun University,

<sup>2</sup>Department of Pre-Dentistry, College of Dentistry, Chosun University, Gwangju, Korea

**Abstract** (J Korean Assoc Oral Maxillofac Surg 2017;43:83-87)

**Objectives:** The purpose of this study is to evaluate the treatment efficacy of enucleation after decompression.

**Materials and Methods:** A total of 17 patients with cystic lesion of the jaw were treated with decompression followed by enucleation. Pre- and post-decompression panoramic radiographs were analyzed.

**Results:** The mean percentage of reduction after decompression was 64%. The reaction was graded as good (>80%) in five patients (29.4%), moderate (50%-80%) in nine patients (52.9%), and poor (<50%) in three patients (17.6%). The reduction rate of larger cystic lesions was faster than that of smaller lesions. However, the reduction rate was not affected by age. The duration of follow-up ranged from one to eight years. There were no complications, and one case recurred.

**Conclusion:** Decompression is an effective method for the initial treatment of jaw cysts.

**Key words:** Decompression, Jaw cysts, Odontogenic cyst

[paper submitted 2016. 2. 26 / revised 2016. 6. 3 / accepted 2016. 6. 24]

## I. Introduction

Jaw cysts are usually painless, but they can increase in size as they absorb neighboring structures. Enucleation generally induces bone regeneration within a cystic lesion less than 3 cm in diameter and eliminates the lesion; however, it is difficult to postoperatively predict lesion recurrence and bone regeneration in cases of larger cysts. For this reason, a surgeon can choose between conservative and aggressive treatments for a large, aggressive, cystic tumor<sup>1,2</sup>.

It has been reported that marsupialization and decompression, both of which are conservative treatments that create an opening to reduce pressure within a cystic cavity and induce

bone formation, generate few postoperative complications and produce great therapeutic effects<sup>3-6</sup>. These procedures not only provide good surgical access to smaller lesions, but they also preserve intraoral tissues, maintain pulp vitality, and reduce recurrence rates. For this reason, many surgeons prefer these methods for treating large cysts.

This study aimed to analyze and assess the therapeutic effects of decompression for patients who underwent decompression followed by enucleation.

## II. Materials and Methods

### 1. Subject screening

We reviewed the charts of patients who visited the Department of Oral and Maxillofacial Surgery at Chosun University Dental Hospital (Gwangju, Korea) and who had undergone enucleation after decompression. We collected data on their age and gender, location and size of the lesions, preoperative and postoperative histopathological findings, gap in time between decompression and enucleation, and variation in the size of the lesions, complications, and recurrence according to the time gap. Patients were excluded from group review

### Su-Gwan Kim

Department of Oral and Maxillofacial Surgery, School of Dentistry, Chosun University, 303 Pilmun-daero, Dong-gu, Gwangju 61452, Korea

TEL: +82-62-220-3819 FAX: +82-62-228-7316

E-mail: sgckim@chosun.ac.kr

ORCID: <http://orcid.org/0000-0002-0424-9984>

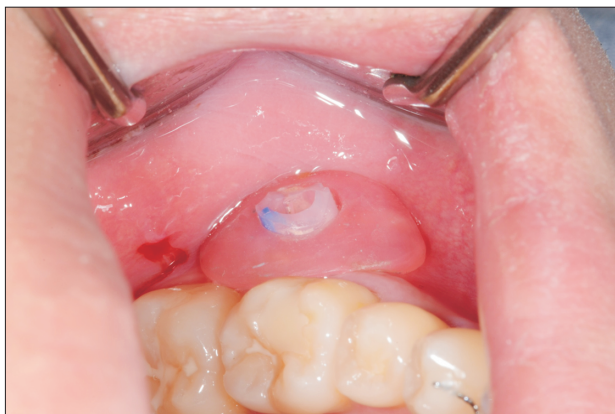©This is an open-access article distributed under the terms of the Creative Commons Attribution Non-Commercial License (<http://creativecommons.org/licenses/by-nc/4.0/>), which permits unrestricted non-commercial use, distribution, and reproduction in any medium, provided the original work is properly cited.

Copyright © 2017 The Korean Association of Oral and Maxillofacial Surgeons. All rights reserved.

if they had no radiological data, if they had cured soft tissues due to the failure to maintain the window, or if they had been observed for less than six months after enucleation. We measured the sizes of lesions in pre- and post-decompression panoramic photographs for each patient, measured width and length with a caliper, and multiplied them together to determine the lesion index (LI) with the aim of simplifying measurement of irregularly sized lesions. To determine the efficacy of decompression, LIs were divided into initial and final LIs, which were then graded on the basis of Nakamura et al.'s formula<sup>7</sup>. To assess the extent of reaction to decompression for each lesion, the difference between initial and final LIs was divided by the decompression period to measure and analyze the reduction rate in each period.

## 2. Treatment protocol

Before conducting a biopsy, clinical and radiographic data were used to determine if patients should undergo decompression. In decompression, the window was formed in the buccal alveolar bone region of the jaw, and a biopsy was conducted after excising some portion of the cyst wall. An individual obturator was made with 18-Fr Foley catheter and resin.(Fig. 1) After the treatment, patients were educated on how to wear and remove the device, and they were instructed to clean the device twice a day (morning and night) using saline solution. Panoramic radiographs were taken every two months for comparison with the baseline panoramic radiograph, and cyst enucleation was conducted when the size of the lesion was determined to no longer be decreasing.



**Fig. 1.** Intraoral view of an individual obturator inserted into a cystic cavity.

Sun-Tae Lee et al: The effect of decompression as treatment of the cysts in the jaws: retrospective analysis. J Korean Assoc Oral Maxillofac Surg 2017

## III. Results

In total, 17 patients (7 males and 10 females) were re-viewed, and their average age was 33.1 years (range, 13-76 years). One patient was diagnosed with nevoid basal cell carcinoma syndrome (NBCCS) and showed multiple keratocystic odontogenic tumors (KCOT) in the maxilla and mandible. Two of these cysts were treated with marsupialization.(Table 1)

Jaw cysts were observed in 10 patients (58.8%) in their teens or 20s, which was a higher rate compared to other age groups, and the sex ratio was 1:1.4 with seven males (41.2%) and 10 females (58.8%).(Fig. 2) Radiographic results showed that all lesions were unilocular and were either pushing or intruding into the surrounding structures (maxillary sinus or mandibular canal) in 15 patients (88.2%). Based on the results of the histopathologic examination, 10 patients were diagnosed with KCOT (58.8%), five patients with dentigerous cysts (DC) (29.4%), one patient with radicular cyst (RC) (5.9%), and one patient with nasopalatine duct cyst (5.9%). Only one patient (5.9%) was treated with marsupialization only, and 16 patients (94.1%) were treated with marsupialization followed by enucleation. There was no case where the preoperative histopathologic results changed after the operation.

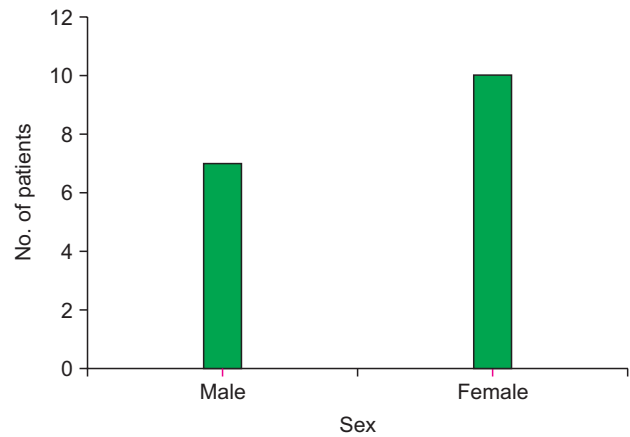
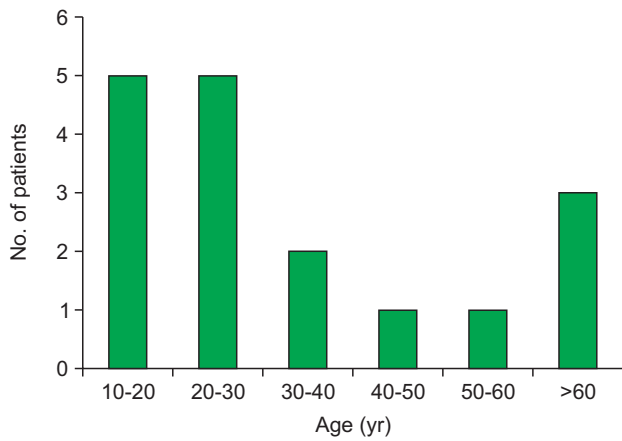
**Table 1.** Patient demographics and decompression data

Sex/age (yr)	Location	Diagnosis	Duration (mo)	Initial size <sup>1</sup> (mm)	Final size <sup>1</sup> (mm)
F/14	Mn.	DC	4	21.3	10.4
M/20	Mx.	DC	10	34.5	21.7
F/18	Mn.	NBCCS	7	23.8	13.9
	Mx.		7	30.4	19.0
F/76	Mx.	Radicular	6	29.6	25.1
F/19	Mn.	DC	3	22.2	12.6
M/13	Mn.	KCOT	10	31.8	5.3
F/70	Mn.	KCOT	8	30.4	13.9
F/20	Mn.	KCOT	12	48.1	11.5
F/35	Mn.	KCOT	16	74.1	32.8
M/20	Mn.	KCOT	9	49.2	30.1
F/28	Mx.	DC	6	34.2	15.9
F/50	Mn.	KCOT	6	38.8	16.8
F/29	Mn.	KCOT	7	43.8	18.3
M/37	Mn.	KCOT	4	34.7	24.7
M/40	Mx.	Nasopalatine	14	58.8	22.6
M/14	Mn.	KCOT	9	33.3	12.8
M/60	Mx.	DC	7	30.0	13.6

(F: female, M: male, Mn.: mandible, Mx.: maxilla, DC: dentigerous cyst, NBCCS: nevoid basal cell carcinoma syndrome, KCOT: keratocystic odontogenic tumor)

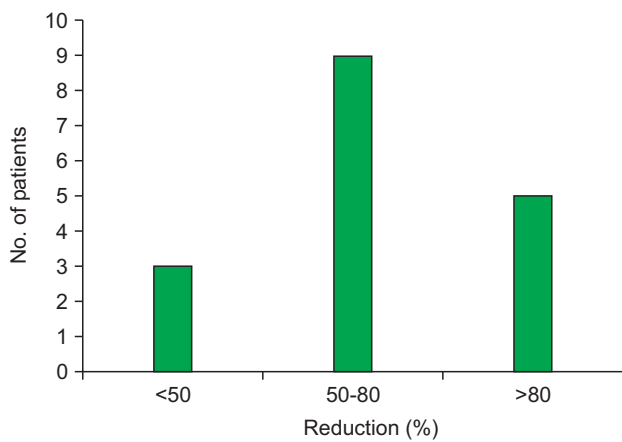
<sup>1</sup>Maximum diameter.

Sun-Tae Lee et al: The effect of decompression as treatment of the cysts in the jaws: retrospective analysis. J Korean Assoc Oral Maxillofac Surg 2017



**Fig. 2.** Age and sex distribution of 17 patients with cystic lesions.

Sun-Tae Lee et al: The effect of decompression as treatment of the cysts in the jaws: retrospective analysis. J Korean Assoc Oral Maxillofac Surg 2017



**Fig. 3.** Change in lesion size, measured by percentage of lesion area reduction.

Sun-Tae Lee et al: The effect of decompression as treatment of the cysts in the jaws: retrospective analysis. J Korean Assoc Oral Maxillofac Surg 2017

The average time of decompression was  $8.1 \pm 3.4$  months, with  $5.5 \pm 4.8$  months for a cyst in the mandible and  $8.3 \pm 3.1$  months for the maxilla. Thus, treatment time was shorter for lesions in the mandible. The average time of decompression based on lesion type was  $8.8 \pm 3.2$  months for KCOT and  $6.0 \pm 2.7$  months for DC, suggesting that KCOTs require approximately three more months of treatment. The LI was measured at an average of 1,349 mm before decompression and 463 mm after decompression, showing an average size decrease of 64% after decompression. According to Nakamura's formula, five patients (29.4%) showed a greater than 80% decrease in size, nine patients (52.9%) showed a 50%-80% decrease in size, and three patients (17.6%) showed a less than 50% decrease in size.(Fig. 3)

The mandible decreased by 10% more in size than the maxilla, and it had a 1.7-fold higher reduction rate in the

**Table 2.** Reduction ratio rated by clinical parameters

	Parameter	Reduction ratio (%)	Reduction rate (mm)
Location	Maxilla	57.0	72.24
	Mandible	67.7	124.69
Age	≤30 yr	70.0	107.22
	>30 yr	55.5	107.19
Sex	Male	70.0	104.02
	Female	60.0	109.23
Size	Large	69.4	136.53
	Small	50.4	61.12
Diagnosis	DC	62.6	81.20
	KCOT	70.0	131.84
	RC	28.0	39.25
	Nasopalatine duct cyst	51.0	34.14

(DC: dentigerous cyst, KCOT: keratocystic odontogenic tumor, RC: radicular cyst)

Sun-Tae Lee et al: The effect of decompression as treatment of the cysts in the jaws: retrospective analysis. J Korean Assoc Oral Maxillofac Surg 2017

same period. Also, when comparing size reduction based on patient age, the decrease was greater in patients in their teens or 20s compared to the other age groups, but the reduction rates were not significantly different. Males were observed to have a smaller final lesion size, while the reduction ratio was higher in females; however, no significant differences were observed. Additionally, larger lesions reduced faster than smaller ones, and KCOTs showed more positive results for decompression than other lesion types.(Table 2)

One patient's recovery was complicated by hypoesthesia after marsupialization, but this naturally recovered over time. The total follow-up period was 1 to 8 years, and 3 out of 17 patients were suspected recurrence. However, one patient was diagnosed with scar tissue after re-examination, and one patient was diagnosed with periapical cyst due to re-infection of an incomplete root canal treatment. A true recurrence ap-

peared on one NBCCS patient's left maxilla and is currently being followed-up after re-operation.

#### IV. Discussion

Since decompression was introduced as a conservative treatment for odontogenic cyst, many cases have been treated with decompression, and various studies have reported high success rates<sup>8,9</sup>. However, the reaction varies depending on the cyst. Anavi et al.<sup>10</sup> conducted decompression on 57 patients who were diagnosed with KCOT, DC, or RC, and no statistically significant differences in reduction rate were reported based on the histologic diagnosis. In present study, the reduction rate in KCOT was higher than the other cysts, with an average of 131.84 mm/month, with the final reduction being the highest. This is because KCOTs are aggressive, so the size of the lesion tends to be greater than that of other cystic lesions. According to this study, cases of LI larger than 1,000 mm showed twice the sensitivity of LI smaller than 1,000 mm. Therefore, in this study, KCOT patients seemed to have a higher sensitivity to decompression since the LI was larger than 1,000 mm.

There are no formal criteria for the decompression period or change in size; however, according to previous studies, a 65% reduction was reported when maintained for an average of 8.4 months. Additionally, an 81% reduction was observed when decompression was maintained for an average of 17.5 months<sup>9,11</sup>. Another study reported that it is preferable to perform enucleation if the size of the lesion after decompression decreases more than 50%-60%<sup>8</sup>.

In this study, the average decompression period was 8.1 months, and the lesions showed an average reduction of 64%. One of the patient's lesions completely disappeared after only marsupialization. These results are similar to those of previous studies.

The effects of decompression based on age are controversial, as it was reported that younger patients had higher reduction rates<sup>10</sup>, but it also was reported that decompression is not correlated with age<sup>12</sup>. The current belief is that age does not affect reduction rate. Therefore, even at older ages, if a large cystic lesion exists within the jaw, postoperative complications can be reduced by decreasing size via decompression.

Similar to marsupialization, decompression is known to have a high success rate. Brøndum and Jensen<sup>13</sup> performed enucleation after decompression in 12 patients with KCOT; during 7 to 17 years of follow-up, no recurrence was re-

ported. The present study also showed that recurrence was occurred in one patient. Such low recurrence rates were reported in many studies, and some of them reported biopsy results indicating that the histological characteristics of the residual cyst epithelium changed from parakeratinization to orthokeratinization or were no longer observed<sup>14</sup>. Based on these results, August et al.<sup>11</sup> reported that histological changes are likely to appear when decompression is maintained for longer than nine months, and he proposed a decompression period of at least nine months.

Various methods have been proposed to reduce error when radiographically measuring lesion size. This study used a panoramic radiograph to two-dimensionally evaluate the lesion by measuring the maximum vertical and horizontal widths of the lesion. This method is widely used because of ease, but it has a disadvantage in accuracy, as it two-dimensionally evaluates a three-dimensional lesion. Therefore, a recent method of measuring volume via three-dimensional analysis using a computer program was introduced<sup>15</sup>. However, this method requires a special program and skilled technique, so it can be difficult to apply clinically. Although plane analysis was performed in the present study due to lack of data for three-dimensional analysis, a more accurate analysis is expected once sufficient data is obtained. This study was limited in that statistical analysis was not performed due to lack of samples.

There is no standardized protocol for treating large cysts of the jaw. The ultimate goal is complete removal of the lesion and reduction of complications. Thus, when a lesion is large, reducing its size via decompression not only allows for conservative treatment, but it can also minimize complications.

#### V. Conclusion

According to this study, all patients treated with decompression were reported to have shown a reduction in lesion size and higher sensitivity with a larger lesion size. There was no difference in the effect of decompression based on age, and only one patient experienced recurrence of the cyst.

#### Conflict of Interest

No potential conflict of interest relevant to this article was reported.

## ORCID

Sun-Tae Lee, <http://orcid.org/0000-0003-1476-1006>  
Su-Gwan Kim, <http://orcid.org/0000-0002-0424-9984>  
Seong-Young Moon, <http://orcid.org/0000-0002-7513-4404>  
Ji-Su Oh, <http://orcid.org/0000-0002-8369-5025>  
Jae-Seek You, <http://orcid.org/0000-0001-7638-9583>  
Jae-Sung Kim, <http://orcid.org/0000-0002-3584-6351>

## References

1. Kolokythas A, Fernandes RP, Pazoki A, Ord RA. Odontogenic keratocyst: to decompress or not to decompress? A comparative study of decompression and enucleation versus resection/peripheral ostectomy. *J Oral Maxillofac Surg* 2007;65:640-4.
2. Dammer R, Niederdellmann H, Dammer P, Nuebler-Moritz M. Conservative or radical treatment of keratocysts: a retrospective review. *Br J Oral Maxillofac Surg* 1997;35:46-8.
3. Nakamura N, Higuchi Y, Tashiro H, Ohishi M. Marsupialization of cystic ameloblastoma: a clinical and histopathologic study of the growth characteristics before and after marsupialization. *J Oral Maxillofac Surg* 1995;53:748-54.
4. Eyre J, Zakrzewska JM. The conservative management of large odontogenic keratocysts. *Br J Oral Maxillofac Surg* 1985;23:195-203.
5. Pogrel MA. Decompression and marsupialization as a treatment for the odontogenic keratocyst. *Oral Maxillofac Surg Clin North Am* 2003;15:415-27.
6. Pogrel MA. Treatment of keratocysts: the case for decompression and marsupialization. *J Oral Maxillofac Surg* 2005;63:1667-73.
7. Nakamura N, Mitsuyasu T, Mitsuyasu Y, Taketomi T, Higuchi Y, Ohishi M. Marsupialization for odontogenic keratocysts: long-term follow-up analysis of the effects and changes in growth characteristics. *Oral Surg Oral Med Oral Pathol Oral Radiol Endod* 2002;94:543-53.
8. Marker P, Brøndum N, Clausen PP, Bastian HL. Treatment of large odontogenic keratocysts by decompression and later cystectomy: a long-term follow-up and a histologic study of 23 cases. *Oral Surg Oral Med Oral Pathol Oral Radiol Endod* 1996;82:122-31.
9. Enislidis G, Fock N, Sulzbacher I, Ewers R. Conservative treatment of large cystic lesions of the mandible: a prospective study of the effect of decompression. *Br J Oral Maxillofac Surg* 2004;42:546-50.
10. Anavi Y, Gal G, Miron H, Calderon S, Allon DM. Decompression of odontogenic cystic lesions: clinical long-term study of 73 cases. *Oral Surg Oral Med Oral Pathol Oral Radiol Endod* 2011;112:164-9.
11. August M, Faquin WC, Troulis MJ, Kaban LB. Dedifferentiation of odontogenic keratocyst epithelium after cyst decompression. *J Oral Maxillofac Surg* 2003;61:678-83.
12. Rao S, Rao S. Decompression as a treatment for odontogenic cystic lesions of the jaw. *J Oral Maxillofac Surg* 2014;72:1231.
13. Brøndum N, Jensen VJ. Recurrence of keratocysts and decompression treatment. A long-term follow-up of forty-four cases. *Oral Surg Oral Med Oral Pathol* 1991;72:265-9.
14. Forssell K, Sainio P. Clinicopathological study of keratinized cysts of the jaws. *Proc Finn Dent Soc* 1979;75:36-45.
15. Shudou H, Sasaki M, Yamashiro T, Tsunomachi S, Takenoshita Y, Kubota Y, et al. Marsupialisation for keratocystic odontogenic tumours in the mandible: longitudinal image analysis of tumour size using 3D visualised CT scans. *Int J Oral Maxillofac Surg* 2012;41:290-6.