



Removal of submandibular calculi by surgical method and hydraulic power with curved needle: a case report

Seong-Ho Cho¹, Ji-Deuk Han¹, Jung-Han Kim¹, Shi-Hyun Lee², Ji-Bong Jo², Chul-Hoon Kim¹, Bok-Joo Kim¹

¹Department of Oral and Maxillofacial Surgery, Department of Dentistry, Dong-A University Hospital,

²Department of Dentistry, Graduate School of Medicine, Dong-A University, Busan, Korea

Abstract (J Korean Assoc Oral Maxillofac Surg 2017;43:182-185)

Sialolithiasis, the most common salivary gland pathology, is caused by calculi in the gland itself and its duct. While patients with small sialoliths can undergo conservative treatment, those with standard-size or larger sialoliths require sialolithotomy. In the present case study, we removed two sialoliths located beneath the mucosa in the posterior and anterior regions of Wharton's duct, respectively. For the posterior calculus, we performed sialolithotomy via an intra-oral approach; thereafter, the small anterior calculus near the duct orifice was removed by hydraulic power. This method has not previously been reported. There were no complications either during the operation or postoperatively, and the salivary function of the gland remained normal.

Key words: Salivary gland calculi, Sialolithiasis, Sialoliths, Submandibular gland, Hydraulic power

[paper submitted 2016. 7. 9 / revised 2016. 8. 27 / accepted 2016. 9. 16]

I. Introduction

Sialolithiasis, the most common salivary gland pathology, is caused by calculi in the gland itself and its duct¹. Gland swelling and pain are the chief complaints of presenting patients^{2,3}. Most salivary gland calculi occur in the submandibular gland (83%), followed by the parotid (10%), sublingual and minor salivary glands (7%)⁴. Calculus size varies from less than 1 mm to a few centimeters⁵. Most salivary calculi are smaller than 10 mm; giant ones, larger than 15 mm and occurring only rarely, are known as sialoliths^{2,6}.

While patients with small sialoliths can undergo conservative treatment, those with standard-size or larger sialoliths require sialolithotomy^{5,7,8}. Most submandibular calculi, located

in the distal third of the duct, are removed surgically via direct incision to the stone^{5,7,9-11}. This procedure is relatively simple to perform, and does not often result in complications¹⁰. Sialoliths that are sufficiently small and near the duct orifice can be manipulated and removed. Another minimally invasive method is using sialogogues with gland massage to promote salivation and flush the small sialoliths to the duct orifice^{7,8,12}. Carelessness during this treatment, however, can cause rupture of the duct¹².

In the present case study, we removed two sialoliths located beneath the mucosa in the posterior and anterior regions of Wharton's duct, respectively. For the posterior calculus, we performed a sialolithotomy via an intra-oral approach; thereafter, the small anterior calculus near the duct orifice was removed by hydraulic power. Postoperatively, the patient's symptoms disappeared, and there have been no complications since.

II. Case Report

A 21-year-old female patient presented with a chief complaint of a firm mass on the right side of the floor of the mouth and uncomfortable swallowing for the preceding 4 months. She had no pain, fever, chills or lymph node swell-

Bok-Joo Kim

Department of Oral and Maxillofacial Surgery, Department of Dentistry, Dong-A University Hospital, 26 Daesingongwon-ro, Seo-gu, Busan 49201, Korea

TEL: +82-51-240-5475 FAX: +82-51-241-5475

E-mail: omsbjkim@dau.ac.kr

ORCID: <http://orcid.org/0000-0002-7482-8738>

©This is an open-access article distributed under the terms of the Creative Commons Attribution Non-Commercial License (<http://creativecommons.org/licenses/by-nc/4.0/>), which permits unrestricted non-commercial use, distribution, and reproduction in any medium, provided the original work is properly cited.

Copyright © 2017 The Korean Association of Oral and Maxillofacial Surgeons. All rights reserved.

This study was supported by a grant of Dong-A University Medical Research Institute.

ing. Intra-oral examination by bimanual palpation revealed a small, firm, and non-tender swelling of the anterior floor of the mouth as well as a large, firm and non-tender swelling in the region opposite #38. Panoramic radiography and cone-beam computed tomography confirmed two calcified lesions in the posterior and anterior regions of the right Wharton's duct, respectively.(Fig. 1) The final diagnosis was sialolithiasis in the right Wharton's duct.

The posterior sialolith was removed intra-orally by sialolithotomy under general anesthesia, incising directly to the stone along the longitudinal axis of the duct and cautiously avoiding the nearby lingual nerve.(Fig. 2) The duct, which was 6 mm in diameter (Fig. 3), was left open, enabling successful, complication-free removal of the anterior sialolith by hydraulic power using a 50-mL syringe with a curved 18-gauge needle.(Fig. 4, 5) After inserting the needle into the open duct, the syringe was used to spout saline water to flush

the small sialolith. Based on the saline that came from the duct orifice, we checked that the front of the sialolith was removed. The postoperative radiography was clear, indicating no remaining sialoliths. After one week and then again at two months, the patient was reviewed to assess gland's salivary function, which proved normal.(Fig. 6) To date, after 2 years, the patient has been asymptomatic, showing no recurrence.

III. Discussion

Sialolithiasis is the most common pathology of the salivary glands¹. The precise pathogenesis is still mostly unknown; however, for treatment of sialolithiasis of the Wharton's duct, there are various methods available, the selection of which depends on the calculi location and size as well as the likeli-

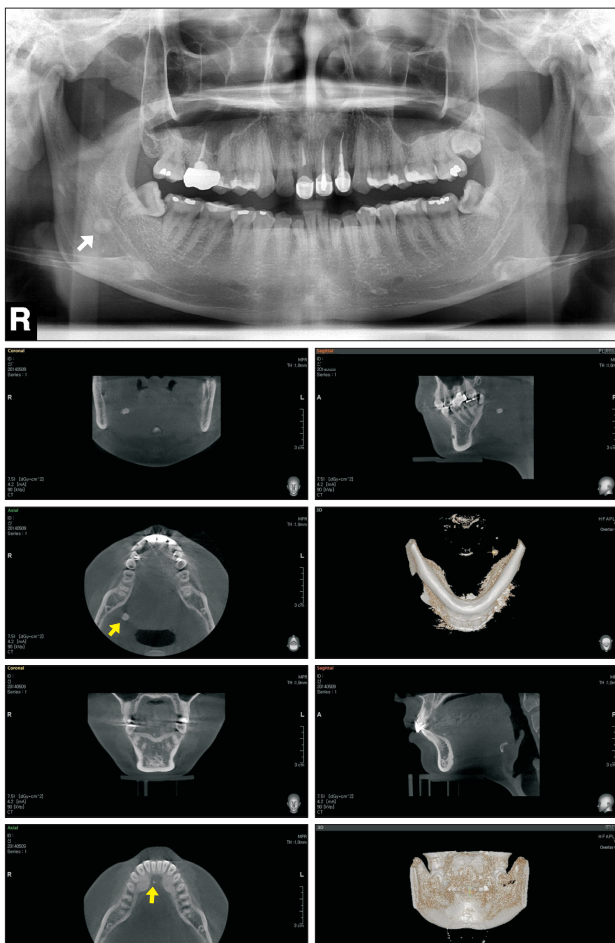


Fig. 1. Preoperative radiographs showing 2 sialoliths. Arrows presenting radiopaque structures.
Seong-Ho Cho et al: Removal of submandibular calculi by surgical method and hydraulic power with curved needle: a case report. J Korean Assoc Oral Maxillofac Surg 2017

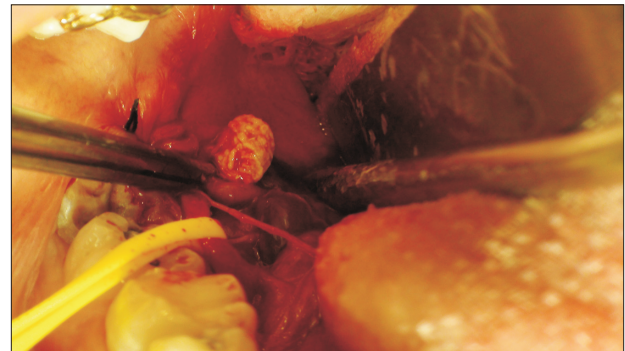

Fig. 2. Intraoperative photograph showing removal of sialolith from Wharton's duct.
Seong-Ho Cho et al: Removal of submandibular calculi by surgical method and hydraulic power with curved needle: a case report. J Korean Assoc Oral Maxillofac Surg 2017

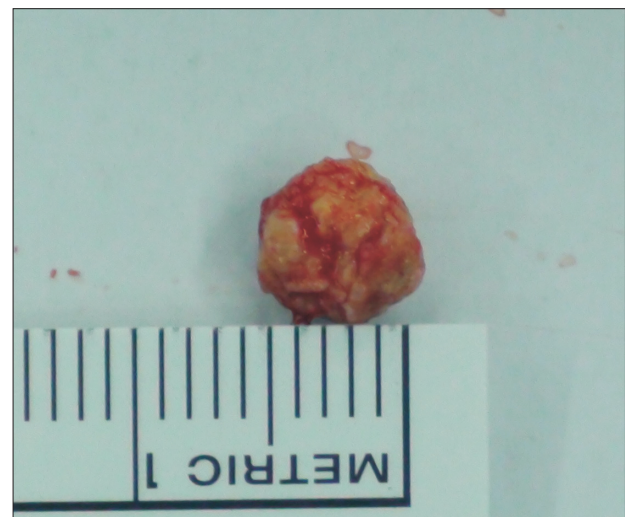


Fig. 3. Excised sialolith.
Seong-Ho Cho et al: Removal of submandibular calculi by surgical method and hydraulic power with curved needle: a case report. J Korean Assoc Oral Maxillofac Surg 2017

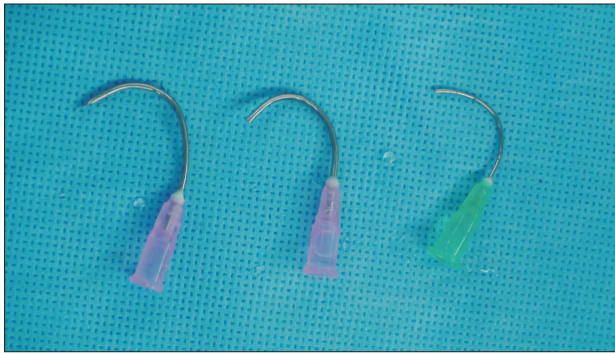


Fig. 4. Curved 18-gauge needles.
Seong-Ho Cho et al: Removal of submandibular calculi by surgical method and hydraulic power with curved needle: a case report. J Korean Assoc Oral Maxillofac Surg 2017

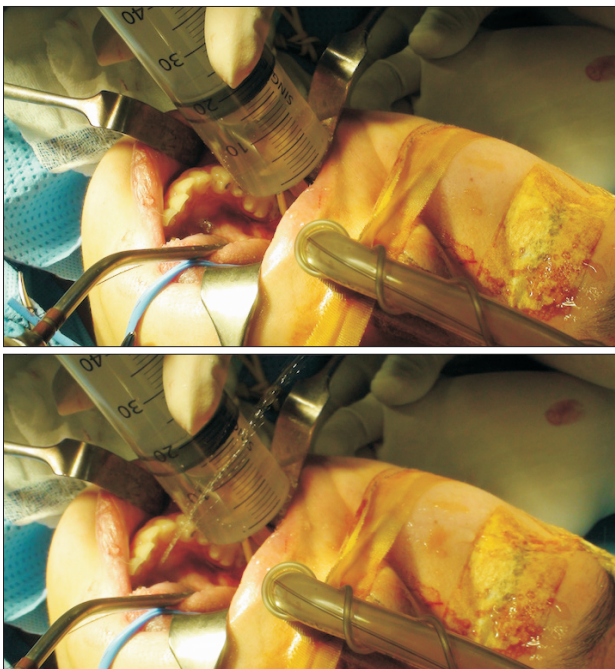


Fig. 5. Intraoperative photographs showing successful sialolith removal by hydraulic power.
Seong-Ho Cho et al: Removal of submandibular calculi by surgical method and hydraulic power with curved needle: a case report. J Korean Assoc Oral Maxillofac Surg 2017

hood of complications based on careful consideration of the patient's specific condition and symptoms¹²⁻¹⁴.

The available methods range from conservative management to surgery⁵. The non-invasive options include hydration of the patient, prescription of sialogogues, and gland massage, all of which can be helpful in promoting salivation and consequent flushing of the calculus^{7,12}. As for minimally invasive treatment, manipulation using lacrimal probes and dilators to open the duct orifice is useful in order to milk the calculus, manipulate it forward, and then remove it⁷. The invasive, surgical approach entails incision along the longitudi-

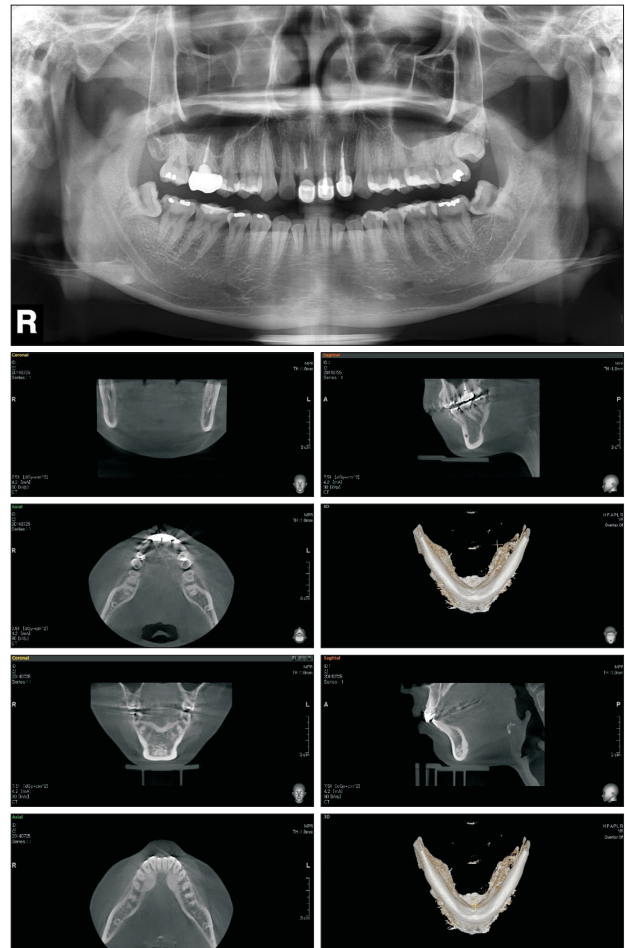


Fig. 6. Postoperative radiographs showing no sialoliths.
Seong-Ho Cho et al: Removal of submandibular calculi by surgical method and hydraulic power with curved needle: a case report. J Korean Assoc Oral Maxillofac Surg 2017

nal axis of the Wharton's duct directly onto the stone, most of which are submandibular calculi located in the duct's distal-third region^{7,8}.

This paper presents a case report of a patient with two sialoliths in the right Wharton's duct. One sialolith, located posteriorly in the distal third of the duct, was surgically excised by sialolithotomy, after which the other, located anteriorly near the orifice, was removed through the duct by hydraulic power. The former surgical method is required to remove large stones in the back of the duct. Then, the least invasive method possible should be used for removal of any stones blocking the duct that are smaller than the diameter of the duct. Careless use of a lacrimal probe is likely to result in rupture of the duct, so we needed a new, easier and safer approach. We chose to try hydraulic power because it is less invasive than a lacrimal probe.

The use of hydraulic power is limited in that it requires another incision and the diameter of the stone should be less

than the diameter of the duct. Removal of only a small stone, located anteriorly near the orifice, can be achieved with conventional methods. Our future work will focus on determining indications for the use of hydraulic power method for less invasive removal of sialoliths.

This method has not been reported previously. There were no complications either during the operation or postoperatively, and the salivary function of the gland remained normal.

Conflict of Interest

No potential conflict of interest relevant to this article was reported.

ORCID

Seong-Ho Cho, <http://orcid.org/0000-0003-0933-953X>

Ji-Deuk Han, <http://orcid.org/0000-0002-8797-1883>

Jung-Han Kim, <http://orcid.org/0000-0002-3469-6136>

Shi-Hyun Lee, <http://orcid.org/0000-0002-5433-9849>

Ji-Bong Jo, <http://orcid.org/0000-0003-2163-9447>

Chul-Hoon Kim, <http://orcid.org/0000-0002-2492-174X>

Bok-Joo Kim, <http://orcid.org/0000-0002-7482-8738>

References

1. Kim MC, Min SY, Kim JY, Ahn JY, Kim HG, Park KH. A giant sialolith in a wharton's duct: a case report. *J Korean Assoc Maxillofac Plast Reconstr Surg* 2005;27:93-6.
2. Rai M, Burman R. Giant submandibular sialolith of remarkable size in the comma area of Wharton's duct: a case report. *J Oral Maxillofac Surg* 2009;67:1329-32.
3. Lustmann J, Regev E, Melamed Y. Sialolithiasis. A survey on 245 patients and a review of the literature. *Int J Oral Maxillofac Surg* 1990;19:135-8.
4. Taher AA. The incidence and composition of salivary stones (sialolithiasis) in Iran: analysis of 95 cases--a short report. *Singapore Dent J* 1989;14:33-5.
5. Choi WS, Yoon HJ, Lee SH. Giant sialolithiasis of the submandibular gland: a case report. *J Korean Assoc Oral Maxillofac Surg* 2010;36:141-4.
6. Bodner L. Giant salivary gland calculi: diagnostic imaging and surgical management. *Oral Surg Oral Med Oral Pathol Oral Radiol Endod* 2002;94:320-3.
7. Nahlieli O, Shacham R, Zagury A, Bar T, Yoffe B. The ductal stretching technique: an endoscopic-assisted technique for removal of submandibular stones. *Laryngoscope* 2007;117:1031-5.
8. Siddiqui SJ. Sialolithiasis: an unusually large submandibular salivary stone. *Br Dent J* 2002;193:89-91.
9. Chung IK, Kim JR, Kim UK, Shin SH, Kim YD, Byun JH, et al. A clinical study of submandibular gland excision. *J Korean Assoc Oral Maxillofac Surg* 2004;30:545-50.
10. Combes J, Karavidas K, McGurk M. Intraoral removal of proximal submandibular stones--an alternative to sialadenectomy? *Int J Oral Maxillofac Surg* 2009;38:813-6.
11. Baurmash HD. Submandibular salivary stones: current management modalities. *J Oral Maxillofac Surg* 2004;62:369-78.
12. Sunder VS, Chakravarthy C, Mikkilinine R, Mahoorkar S. Multiple bilateral submandibular gland sialolithiasis. *Niger J Clin Pract* 2014;17:115-8.
13. Sutay S, Erdag TK, Ikiz AO, Guneri EA. Large submandibular gland calculus with perforation of the floor of the mouth. *Otolaryngol Head Neck Surg* 2003;128:587-8.
14. Chan EK, Patel ND. Giant calculus of the submandibular salivary duct. *Ear Nose Throat J* 2006;85:306, 308.