



# New method for an evaluation of the esthetical improvements resulting from a mandibular angle reduction

Joo-Hwan Kim, Se-Jin Han, Moon-Young Kim

*Department of Oral and Maxillofacial Surgery, College of Dentistry, Dankook University, Cheonan, Korea*

**Abstract** (J Korean Assoc Oral Maxillofac Surg 2017;43:239-246)

**Objectives:** This paper proposes Han's ratio as an objective and quantitative comparative result obtained from pre and postoperative data in patients with a mandibular angle reduction.

**Materials and Methods:** Thirty patients, 12 men and 18 women, who visited the Department of Oral and Maxillofacial Surgery with the chief complaints of skeletal mandibular prognathism and prominent mandibular angle were selected. The subjects were classified into 3 groups according to the types of surgical procedures involved. Group A consisted of patients who underwent mandibular angle resection and mandibular setback. Group B was comprised of patients with mandibular angle resection, mandibular setback and genioplasty. Group C consisted of patients with mandibular angle resection, mandibular setback, Le Fort I osteotomy, and genioplasty. The landmarks placed in pre and postoperative frontal photographs were used to obtain the Han's ratio in each group. The Han's ratios were compared pre- and postoperation and according to the surgical techniques applied.

**Results:** Of the 3 groups who had undergone a mandibular angle resection, all showed a statistically significant increase in Han's ratio. On the other hand, there was no statistically significant difference based on the surgical techniques used.

**Conclusion:** The ratio of the lateral lower face proposed in this study is a potential indicator of postoperative esthetic enhancement in mandibular angle reduction surgery.

**Key words:** Mandibular angle, Orthognathic surgery, Surgery, Plastics, Facial analysis

[paper submitted 2017. 3. 9 / revised 2017. 5. 12 / accepted 2017. 5. 26]

## I. Introduction

Square faces due to prominent mandibular angles of varying degrees are often treated with plastic surgery in modern societies where oval faces with symmetrical and small overall facial outlines are considered esthetically pleasing.

Since brachycephalic or mesocephalic faces are typical of Asians, whereas dolichocephalic faces are typical of Caucasians, reduction of mandibular angles and zygomas resulting in oval face contours is widespread among Asians<sup>1</sup>.

Although factors leading to a prominent mandibular angle

can be subdivided into 2 groups, i.e., congenital and developmental (e.g., bruxism), no exact cause has been identified so far, despite several studies<sup>2</sup>.

Numerous studies have been conducted on the cause, since the terms, masseter muscle hypertrophy or benign masseteric hypertrophy, were coined for a prominent unilateral or bilateral mandibular angle<sup>3,4</sup>, and improvement in surgical techniques have been made. Surgical corrections have been carried out since the late 1980s<sup>5</sup>. Techniques for the reduction of a mandibular angle are classified as masseter muscle reduction and mandibular bone reduction; the latter is preferred to the former by surgeons due to its many advantages<sup>5,6</sup>. While curved osteotomy of the mandibular angle is by far the most widely used technique, lateral cortical osteotomy of the mandibular angle and ramus is recently gaining popularity<sup>7</sup>. Indications, pros and cons as well as various procedures for both techniques have been described in detail.

In spite of numerous reports on the surgical technique for mandibular angle reduction, only a few studies have been conducted to evaluate patient postoperative satisfaction and esthetic improvements. Since there is a lack of established

### Se-Jin Han

*Department of Oral and Maxillofacial Surgery, College of Dentistry, Dankook University, 119 Dandae-ro, Dongnam-gu, Cheonan 31116, Korea*  
TEL: +82-41-550-1996 FAX: +82-41-551-8988  
E-mail: hanimplant@dankook.ac.kr  
ORCID: <http://orcid.org/0000-0003-4949-4462>

© This is an open-access article distributed under the terms of the Creative Commons Attribution Non-Commercial License (<http://creativecommons.org/licenses/by-nc/4.0/>), which permits unrestricted non-commercial use, distribution, and reproduction in any medium, provided the original work is properly cited.

Copyright © 2017 The Korean Association of Oral and Maxillofacial Surgeons. All rights reserved.

standards for the esthetic mandibular angle, the patient's request is the primary determinant in the operative plan. In other words, postoperative satisfaction and the demands of each patient are the most critical criteria in mandibular angle reduction. However, unclear understanding between the surgeon and the patients' esthetic demands may bring about unexpected outcomes. Moreover, a patient's misperception of self may lead to disappointment with the result of the treatment. Lack of standardized preoperative and postoperative assessment methods may result in such situations. Thus, an objective and systematic manner of evaluation and diagnosis is required.

Therefore, this study was conducted to test Han's ratio as an objective and quantitative method obtained from pre- and postoperative data in patients requesting mandibular angle reduction. Considering that the outline of oval shaped mandibles resembles an inverted triangle, favorable soft tissue landmarks were determined and quantified in order to compare the amount of reduction in patients who have undergone mandibular reduction surgery<sup>8</sup>.

## II. Materials and Methods

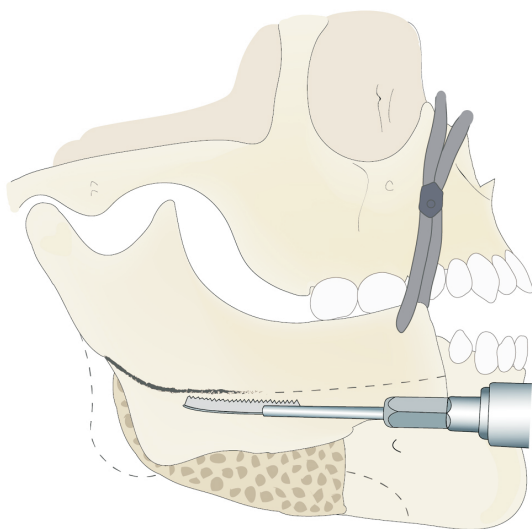
### 1. Patients

Thirty patients, including 12 men and 18 women were selected from 175 patients who came to the Department of Oral and Maxillofacial Surgery, Dankook University Dental Hos-

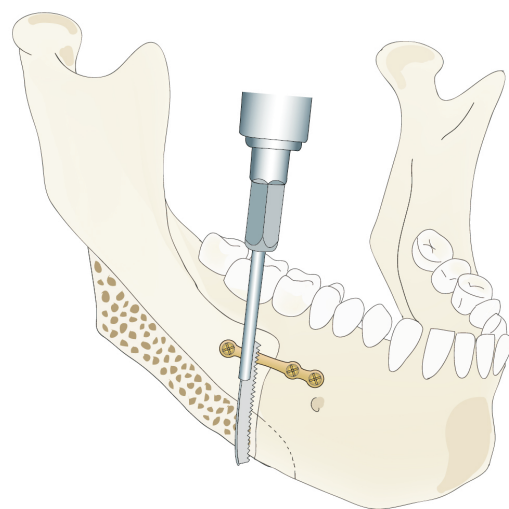
pital (Cheonan, Korea) from January 2007 to March 2012 with chief complaints of skeletal mandibular prognathism and prominent mandibular angle. Subjects were carefully chosen with the following criteria: (1) patients who had undergone both orthodontic and orthognathic surgery and (2) patients capable of 1 month presurgical and 3 to 6 months postsurgical follow-up. Due to the retrospective nature of this study, it was granted written exemption by the Dankook University Dental Hospital's Institutional Review Board. The written informed consent was obtained from all patients.

Mandibular angle reduction along with bilateral sagittal split ramus osteotomy with or without genioplasty in the mandible and advancement of the maxilla with or without Le Fort I osteotomy was conducted. Subjects were classified into 3 groups according to the types of surgical procedures involved. Group A consisted of 9 patients who had mandibular angle reduction and mandibular setback was achieved only with mandibular angle resection and bilateral sagittal split osteotomy; Group B consisted of 12 patients with mandibular angle resection, bilateral sagittal split ramus osteotomy and genioplasty; and Group C consisted of 9 patients with mandibular angle resection, bilateral sagittal split ramus osteotomy, Le Fort I osteotomy and genioplasty.

Moreover, in order to establish an unbiased standard, 82 Korean females who ranked high in beauty pageants from 2002 to 2011 were chosen as the control group.



**Fig. 1.** Schematic drawing of curved osteotomy using reciprocating saw after sagittal split ramus osteotomy.  
*Joo-Hwan Kim et al: New method for an evaluation of the esthetical improvements resulting from a mandibular angle reduction. J Korean Assoc Oral Maxillofac Surg 2017*



**Fig. 2.** Diagram of osteotomy design under the mental foramen after fixation of proximal segment to distal segment of mandible.  
*Joo-Hwan Kim et al: New method for an evaluation of the esthetical improvements resulting from a mandibular angle reduction. J Korean Assoc Oral Maxillofac Surg 2017*

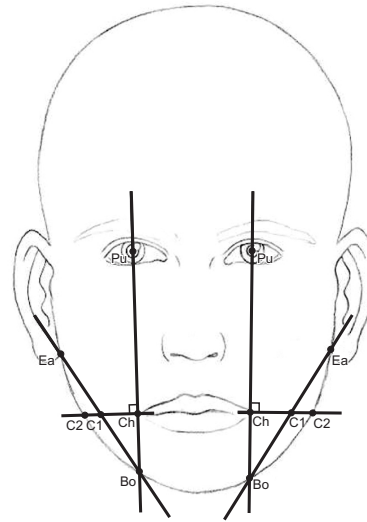
## 2. Surgical technique

Curved ostectomy or lateral cortical ostectomy was performed for mandibular angle resection. Curved ostectomy involved bilateral sagittal splitting ramus osteotomy in which the proximal section was anteriorly displaced, followed by a gently curved ostectomy with a reciprocation saw starting from the posterior border of the mandible to the lower border of the mandibular body. At this point, the modified method for mandibular angle reduction was done. The line of resection was extended below the mental foramen for a shallower look in the lower lateral face. (Fig. 1, 2) Sharp resection margins were subsequently rounded with a round bur<sup>5</sup>. For lateral cortical ostectomy, the mandible was cut transversely at the mandibular occlusal level with the reciprocating saw and the cut extended antero-inferiorly along the lateral cortical bone to reach the first molar and at that point the mandible was vertically split. Segments were separated with a chisel and sharp margins were also smoothed with the round bur.

## 3. Analysis method for frontal facial photographs

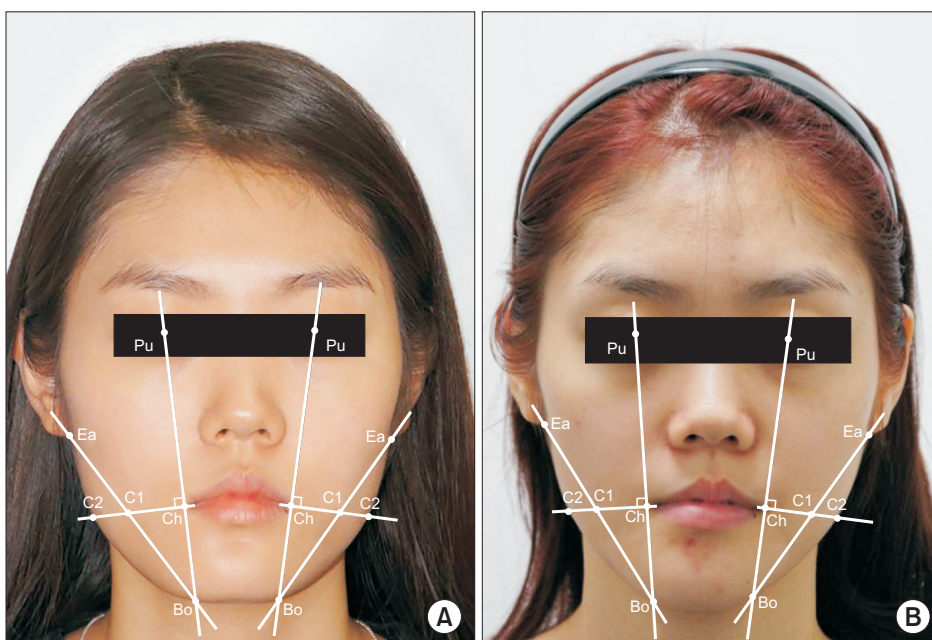
Frontal facial photos of patients were taken within 1 week before and 3 to 6 months after surgical correction. Subjects were instructed to stay still with their Frankfort horizontal plane (FH plane) parallel to the ground with both lips relaxed and closed naturally in centric occlusion. Then, photos were taken in a usual manner and saved in JPEG format. Utilizing the Adobe Photoshop ver. 14.0 program (Adobe Systems,

Mountain View, CA, USA), the distance between each selected landmark was measured and ratios were obtained. The amount of discrepancy was assessed by cross-comparison of the ratios representative of each phase. As shown in Fig. 3 and 4, landmarks and measurements used in the present study were as follows.



**Fig. 3.** Liner measurements and reference landmarks used in this study. (Pu: midpoint of pupil, Ch: most lateral point between upper and lower lip, C1: intersection of a line drawn from Ch perpendicular to Po-Bo and a line between Ba-Bo, C2: intersection of a line drawn from Ch perpendicular to Po-Bo and mandibular outline, Bo: mandibular outline, Ea: intersection of outlines of face and earlobe)

Joo-Hwan Kim et al: New method for an evaluation of the esthetical improvements resulting from a mandibular angle reduction. *J Korean Assoc Oral Maxillofac Surg* 2017



**Fig. 4.** Liner measurements and reference landmarks are showing in the preoperative (A) and postoperative (B) frontal facial photographs. Refer to Fig. 3 for the definition of landmarks.

Joo-Hwan Kim et al: New method for an evaluation of the esthetical improvements resulting from a mandibular angle reduction. *J Korean Assoc Oral Maxillofac Surg* 2017

- 1) Landmarks and dimensions
  - (1) Pu: midpoint of pupil
  - (2) Ch: most lateral point between upper and lower lip
  - (3) Bo: mandibular outline
  - (4) Ea: intersection of outlines of face and earlobe
  - (5) C1: intersection of a line drawn from Ch perpendicular to Po-Bo and a line between Ba-Bo
  - (6) C2: intersection of a line drawn from Ch perpendicular to Po-Bo and mandibular outline
- 2) Linear measurements
  - (1) Distance between Ch–C1
  - (2) Distance between Ch–C2

$$\text{Han's ratio} = \frac{\text{Ch}-\text{C1}}{\text{Ch}-\text{C2}}$$

#### 4. Statistical analysis

Preoperative and postoperative means and standard deviations were obtained from each patient group and the Wilcoxon signed rank test was performed to verify significance. In addition, the Mann-Whitney test at a significance level of 5% was conducted to verify significant differences between groups. PASW Statistics ver. 18.0 (IBM Co., Armonk, NY, USA) was used. Average values and standard deviations were calculated for beauty pageant winners.

### III. Results

Postoperative Han's ratio was significantly increased compared to the preoperative Han's ratio in groups, A, B, and C. (Tables 1-3) The magnitude of the increase in the Han's ratio was not statistically different between groups ( $P > 0.05$ ). Representative cases of frontal facial photos and cephalometric radiographs of each group are shown in Fig. 5-7.

The average and standard deviation of Han's ratio acquired from 82 Korean beauty pageant winners were  $0.688 \pm 0.06$  on the right and  $0.696 \pm 0.05$  on the left.

**Table 1.** Mean and standard deviation of Group A (angle reduction+BSSRO) and Wilcoxon signed rank test results

	Preoperative	Postoperative	Pre-post
Right	0.668±0.0091	0.691±0.0100	*
Left	0.671±0.0128	0.687±0.0094	*

(BSSRO: bilateral sagittal splitting ramus osteotomy)  
\* $P < 0.05$ .

Joo-Hwan Kim et al: New method for an evaluation of the esthetical improvements resulting from a mandibular angle reduction. J Korean Assoc Oral Maxillofac Surg 2017

### IV. Discussion

A recent worldwide trend in maxillofacial reconstruction focuses on cosmetic surgeries primarily aimed at esthetic enhancement of individuals, unlike the past when the mainstream of treatment was reconstruction of facial deformities induced by malignant cancer or trauma. This is not a transient phenomenon but rather a transition owing to the demands of contemporary esthetically-minded patients. In fact, the range of surgery has been gradually broadened to meet the changing needs of patients more specifically, such as jaw and facial contouring surgery, predominantly including the correction of mandibular prognathism.

A face with a prominent mandibular angle makes a strong and masculine impression on others, so it is not preferred among Asians, including Koreans. Moreover, for genetic and racial reasons, Asians tend to have a wider lower face than Caucasians and as a result, mandibular angle reduction is more common in the East than in the West<sup>9</sup>.

The average bigonial distance of Korean women is 117.8 to 125.25 mm whereas that of Caucasian women is 105 to 109 mm<sup>10</sup>. Thus, a prominent mandibular angle is not a pathologic phenomenon but instead a problem that merely requires an esthetic manner of approach. Standards of beauty have historically been established respectively in western and eastern society. However, since modern times, the spread of the western centered culture worldwide has resulted in western

**Table 2.** Mean and standard deviation of Group B (angle reduction+BSSRO+genioplasty) and Wilcoxon signed rank test results

	Preoperative	Postoperative	Pre-post
Right	0.649±0.0275	0.683±0.0143	*
Left	0.645±0.0330	0.680±0.0132	*

(BSSRO: bilateral sagittal splitting ramus osteotomy)  
\* $P < 0.05$ .

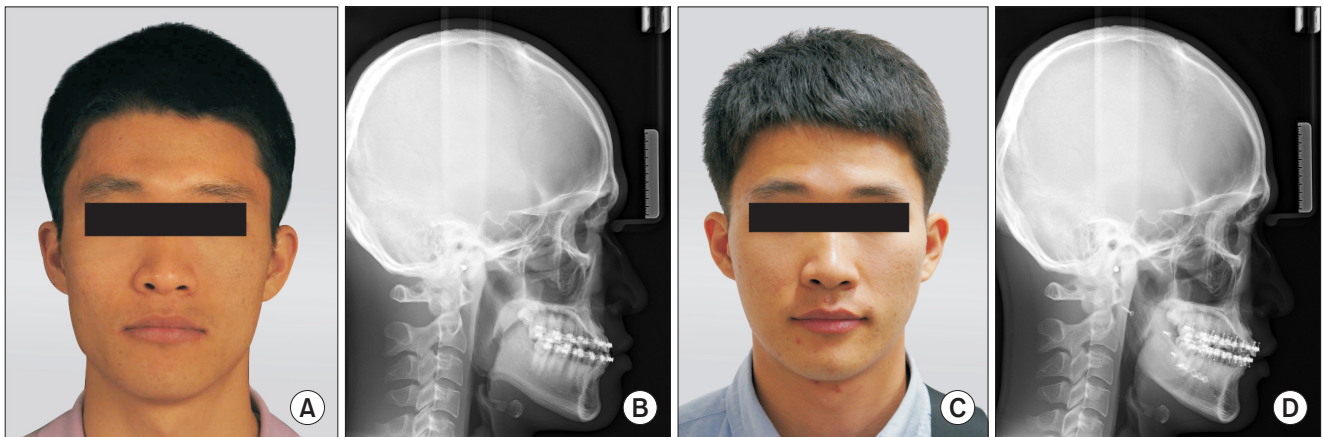
Joo-Hwan Kim et al: New method for an evaluation of the esthetical improvements resulting from a mandibular angle reduction. J Korean Assoc Oral Maxillofac Surg 2017

**Table 3.** Mean and standard deviation of Group C (angle reduction+BSSRO+Le Fort I osteotomy+ genioplasty) and Wilcoxon signed rank test results

	Preoperative	Postoperative	Pre-post
Right	0.653±0.0188	0.682±0.0211	*
Left	0.657±0.0149	0.683±0.0188	*

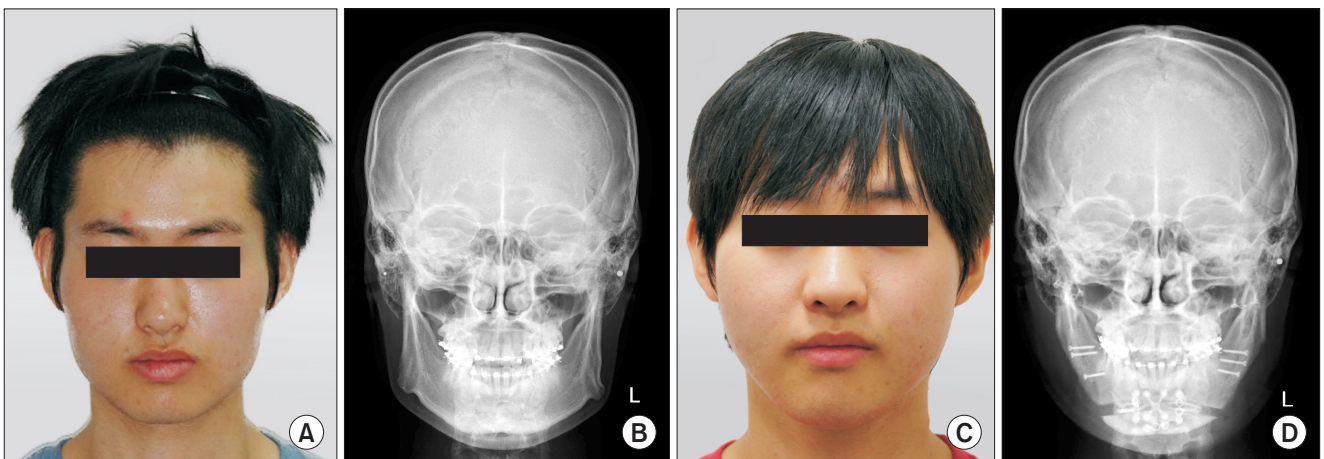
(BSSRO: bilateral sagittal splitting ramus osteotomy)  
\* $P < 0.05$ .

Joo-Hwan Kim et al: New method for an evaluation of the esthetical improvements resulting from a mandibular angle reduction. J Korean Assoc Oral Maxillofac Surg 2017



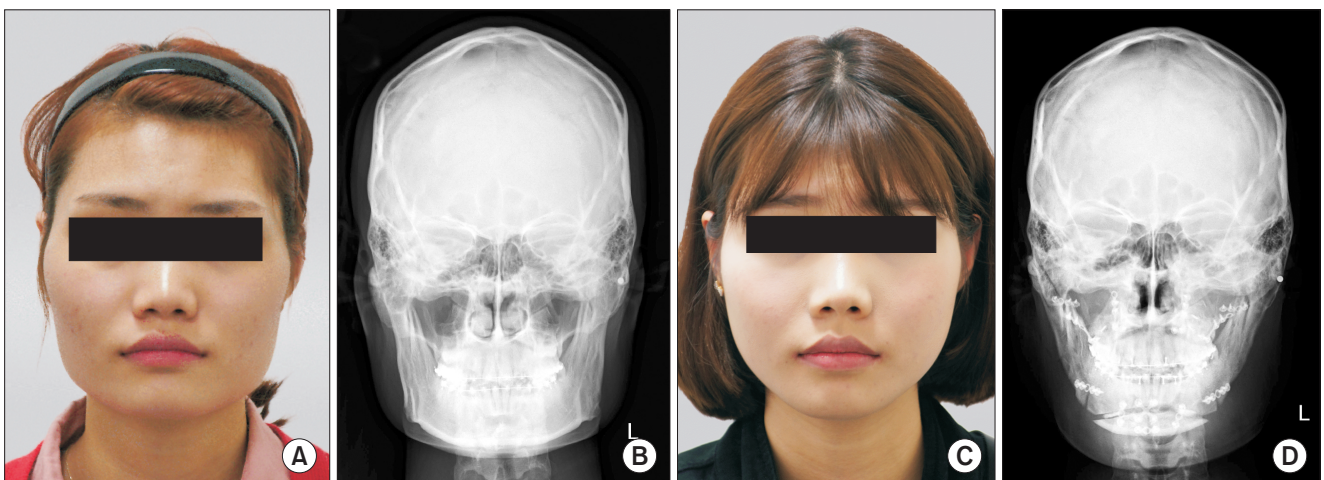**Fig. 5.** Preoperative (A, B) and postoperative (C, D) changes of a frontal facial photograph and cephalometric lateral radiograph in Group A. The ratio increased from 0.67 to 0.72 after the surgery.

Joo-Hwan Kim et al: New method for an evaluation of the esthetical improvements resulting from a mandibular angle reduction. *J Korean Assoc Oral Maxillofac Surg* 2017



**Fig. 6.** Preoperative (A, B) and postoperative (C, D) changes of a frontal facial photograph and cephalometric posteroanterior radiograph in Group B. The ratio increased from 0.60 to 0.68 after the surgery.

Joo-Hwan Kim et al: New method for an evaluation of the esthetical improvements resulting from a mandibular angle reduction. *J Korean Assoc Oral Maxillofac Surg* 2017



**Fig. 7.** Preoperative (A, B) and postoperative (C, D) changes of a frontal facial photograph and cephalometric posteroanterior radiograph in Group C. The ratio increased from 0.65 to 0.71 after the surgery.

Joo-Hwan Kim et al: New method for an evaluation of the esthetical improvements resulting from a mandibular angle reduction. *J Korean Assoc Oral Maxillofac Surg* 2017

standards of beauty dominating the East as well. When faces of 72 Korean-American women were scored by 10 other Korean-Americans using a visual analogue scale (VAS) of appearance, the highest rated were more similar to Western faces than that of the average Korean<sup>11</sup>. In the same sense, Asians with wide a interangular dimension consider narrower bigonial distance, typical of Caucasians, charming and desire mandibular angle reduction.

Baek et al.<sup>5</sup> who first suggested the modern concept of mandibular angle reduction, concluded that a prominent mandibular angle is a relatively common esthetic problem and the cause lies in inferoposterior projection of the angular portion of the mandible rather than muscle hypertrophy. In addition, Legg<sup>12</sup> reported that the prominent angles are attributed to racial differences, with hypertrophy of the masseter muscle predominant in Caucasians and bony projection in Asians.

Improvement in surgical techniques and research of causes have continued since the introduction of terms including prominent unilateral or bilateral angle, masseter muscle hypertrophy or benign masseteric hypertrophy.

Surgical correction by an extraoral approach was initially performed by Gurney<sup>13</sup> with excision of the lateral portion of the hypertrophic masticatory muscle, followed by Adams<sup>14</sup> with skin incision and finally the first intraoral approach by Converse<sup>15</sup>. Popular current techniques include curved osteotomy and lateral cortical osteotomy, originally introduced by Baek et al.<sup>5,16</sup> in 1989 and 1994, respectively.

In spite of many reports on surgical techniques for mandibular angle reduction, studies on preoperative diagnosis and postoperative assessment are relatively scarce.

The gonial angle is the most critical part in the profile, especially in curved osteotomy, since patients with an initially large gonial angle may show an even larger angle and thus an abnormal and unnatural contour after the procedure<sup>7</sup>. The mean mandibular angle in Koreans is  $128.71^{\circ} \pm 3.87^{\circ}$  and the mandibular plane-sella nasion (MP-SN) is  $32.69^{\circ} \pm 6.11^{\circ}$ <sup>17,18</sup>. Meanwhile, Jin<sup>7</sup> insisted that mandibular ramus to body length ratio should also be considered important for profile analysis. When the length of the body is longer than that of the ramus, only a slight increase in mandibular angle brings about a very awkward appearance. Thus, enlargement of the mandibular angle is not favorable in either the case of mandibular prognathism with a long ramus length or mandibular recession with a short body length.

Since Baek et al.<sup>16</sup> pointed out that the frontal as well as the profile view are crucial for the diagnosis and assessment of mandibular angle, diagnosis drawn from both sides has be-

come a general procedure<sup>19</sup>.

Han and Kim<sup>9</sup> measured bitemporal, bizygomatic and bigonial distance and calculated their ratios. He reported that ideally the bitemporal and bigonial distance should be equal and narrower than the bizygomatic distance by 10%. However, this is merely a concept of linear measurement and carries some disadvantages. Ambiguous criteria for nonbiased assessment of esthetic enhancement and an inability to evaluate facial asymmetry are examples of shortcomings in the evaluation of treatment results.

Barnett and Whitaker<sup>20</sup> proposed a three-dimensional (3D) method for midface and lower face evaluation. Six landmarks were chosen and connected with lines and eventually constituted planes. However, this method is quite complicated and difficult to use in the clinical setting. Recently, computer-aided surgical simulation improved presurgical work-up efficiency. It also provided an opportunity to illustrate multidimensional correction at the skeletal and soft tissue levels. CT scanning images are needed for this, but due to economical and ethical issues, CT scanning images are not used every time. Instead, two-dimensional films are commonly used for post-orthognathic surgery follow-up visits. In clinical practice, there are limits to the 3D analysis of patient faces before and after operations. Therefore, in this study we suggested a simple and fast method to quantitatively analyze the differences in the pre- and postoperative mandibular angles using frontal facial photographs only.

The evaluation of facial symmetry should be carried out on the facial soft tissue of actual patients and not radiographs. Radiographic shape of bones cannot reflect real facial structure because of variation in the thickness of the masseter muscle. Moreover, it should be noted that a shorter than average bigonial distance may make a face look more beautiful<sup>7</sup>.

As to the assessment of patient satisfaction level after treatment, only a few studies have adopted objective methods such as the VAS to estimate patient aesthetic satisfaction. Choi et al.<sup>21</sup> conducted a survey with 20 questions and reported that 97% of the patients who underwent mandibular reduction surgery were satisfied with the results.

In most studies, esthetic satisfaction was assessed in a subjective manner, for example satisfactory or unsatisfactory. The results revealed that a considerable number of patients were satisfied with the esthetic outcome of their operation. However, such studies may have been biased, since most were retrospective studies on the patient group and no established criteria for radiographic or clinical success existed.

In the present study, Han's ratio was obtained and com-

pared to evaluate postoperative esthetic enhancement in exact numerical values, rather than patient subjective satisfaction level. A Han's ratio of approximately 1.0 indicates a more oval shaped lower face line. Although the standard of beauty is obviously a subjective notion, 82 winners of Korean beauty pageants from 2002 to 2011 can be presumed to represent the recent standard of beauty in Korea. Han's ratio was measured in their frontal facial photos and the mean values were 0.688 on the right and 0.696 on the left.

All 3 groups, i.e., Group A (mandibular angle reduction and mandibular setback osteotomy), Group B (mandibular angle resection, bilateral sagittal split ramus osteotomy and genioplasty), and Group C (mandibular angle resection, bilateral sagittal split ramus osteotomy, Le Fort I osteotomy and genioplasty), demonstrated an increase in Han's ratio. This data supported Han and Kim<sup>9</sup> who reported a postoperative decrease of bigonial distance by an average of 12.3 mm in 12 patients after mandibular angle osteotomy, as compared to preoperative data.

There were no significant differences in preoperative and postoperative Han's ratio for each group i.e., control, Group A, and the experimental, Group B or Group C. Thus, we assumed that using a frontal view for preoperatively planned anteroposterior movement of the maxilla and the chin played little role in postoperative esthetic improvement resulting from a reduced mandibular angle.

Han's ratio proposed in the present study can be easily calculated by placing landmarks on frontal facial images. Moreover, it can be obtained separately on the right and left to analyze the degree of correction of facial asymmetry between preoperative diagnosis and postoperative evaluation. Meanwhile, since only frontal evaluations are possible with this method, supplementary lateral assessments of angle are required.

Whitaker<sup>17</sup> pointed out that applying a plain and consistent method in every case is incorrect because of the ambiguity inherent in the evaluation of facial esthetics. In fact, enhancement of Han's ratio does not necessarily lead to esthetic improvement. In addition, overall facial balance and harmony with the nose, eyes and adjacent structures must be taken into consideration.

## V. Conclusion

The Han's ratio suggested in this study is potentially a valuable indicator of postoperative esthetic enhancement in mandibular angle reduction surgery.

## Conflict of Interest

No potential conflict of interest relevant to this article was reported.

## ORCID

Joo-Hwan Kim, <http://orcid.org/0000-0002-1248-9152>

Se-Jin Han, <http://orcid.org/0000-0003-4949-4462>

Moon-Young Kim, <http://orcid.org/0000-0001-9596-7481>

## References

1. Satoh K. Mandibular contouring surgery by angular contouring combined with genioplasty in orientals. *Plast Reconstr Surg* 1998;101:461-72.
2. Coffey RJ. Unilateral hypertrophy of the masseter muscle. *Surgery* 1942;11:815.
3. Rončević R. Masseter muscle hypertrophy: aetiology and therapy. *J Oral Maxillofac Surg* 1986;14:344-8.
4. Goodwin DP, Calnan JS, McBride JA. Benign hypertrophy of the masseter muscles associated with hypofibrinogenemia. A case report. *Br J Plast Surg* 1967;20:441-5.
5. Baek SM, Kim SS, Bindiger A. The prominent mandibular angle: preoperative management, operative technique, and results in 42 patients. *Plast Reconstr Surg* 1989;83:272-80.
6. Yang DB, Park CG. Mandibular contouring surgery for purely aesthetic reasons. *Aesthetic Plast Surg* 1991;15:53-60.
7. Jin H. Misconceptions about mandible reduction procedures. *Aesthetic Plast Surg* 2005;29:317-24.
8. Jin H, Kim BG. Mandibular angle reduction versus mandible reduction. *Plast Reconstr Surg* 2004;114:1263-9.
9. Han K, Kim J. Reduction mandibuloplasty: osteotomy of the lateral cortex around the mandibular angle. *J Craniofac Surg* 2001;12:314-25.
10. Lee Y, Han K, Kang J. Korean standards of craniomaxillofacial skeleton. *J Korean Soc Plast Reconstr Surg* 1994;21:438-51.
11. Choe KS, Sclafani AP, Litner JA, Yu GP, Romo T 3rd. The Korean American woman's face: anthropometric measurements and quantitative analysis of facial aesthetics. *Arch Facial Plast Surg* 2004;6:244-52.
12. Legg JW. Enlargement of the temporal and masseter muscle on both sides. *Trans Pathol Soc* 1980;31:361-6.
13. Gurney CE. Chronic bilateral benign hypertrophy of the masseter muscles. *Am J Surg* 1947;73:137-9.
14. Adams WM. Bilateral hypertrophy of the masseter muscle; an operation for correction; case report. *Br J Plast Surg* 1949;2:78-81.
15. Converse JM. Deformity of the jaws. In: Converse JM, ed. *Reconstructive plastic surgery*. Philadelphia: Saunders; 1977:1404.
16. Baek SM, Baek RM, Shin MS. Refinement in aesthetic contouring of the prominent mandibular angle. *Aesthetic Plast Surg* 1994;18:283-9.
17. Whitaker LA. Aesthetic contouring of the facial support system. *Clin Plast Surg* 1989;16:815-23.
18. Cho JH, Han KH, Kang JS. Normal anthropometric values and standardized templates of Korean face and head. *J Korean Soc Plast Reconstr Surg* 1993;20:995-1005.
19. Kim SK, Han JJ, Kim JT. Classification and treatment of prominent mandibular angle. *Aesthetic Plast Surg* 2001;25:382-7.

20. Barnett A, Whitaker LA. Facial form analysis of the lower and middle face. *Plast Reconstr Surg* 1986;78:158-65.
21. Choi BK, Goh RC, Moaveni Z, Lo LJ. Patient satisfaction after zygoma and mandible reduction surgery: an outcome assessment. *J Plast Reconstr Aesthet Surg* 2010;63:1260-4.