



Stepwise verification of bone regeneration using recombinant human bone morphogenetic protein-2 in rat fibula model

Jung-Woo Nam^{1,2}, Hyung-Jun Kim^{1,3,4}

¹Department of Oral and Maxillofacial Surgery, Yonsei University College of Dentistry, Seoul,
²Department of Oral and Maxillofacial Surgery, Wonkwang University Sanbon Hospital, Gunpo,
³Oral Cancer Research Institute and ⁴Research Institute for Dental Biomaterials & Bioengineering,
Yonsei University College of Dentistry, Seoul, Korea

Abstract (J Korean Assoc Oral Maxillofac Surg 2017;43:373-387)

Objectives: The purpose of this study was to introduce our three experiments on bone morphogenetic protein (BMP) and its carriers performed using the critical sized segmental defect (CSD) model in rat fibula and to investigate development of animal models and carriers for more effective bone regeneration.

Materials and Methods: For the experiments, 14, 16, and 24 rats with CSDs on both fibulae were used in Experiments 1, 2, and 3, respectively. BMP-2 with absorbable collagen sponge (ACS) (Experiments 1 and 2), autoclaved autogenous bone (AAB) and fibrin glue (FG) (Experiment 3), and xenogenic bone (Experiment 2) were used in the experimental groups. Radiographic and histomorphological evaluations were performed during the follow-up period of each experiment.

Results: Significant new bone formation was commonly observed in all experimental groups using BMP-2 compared to control and xenograft (porcine bone) groups. Although there was some difference based on BMP carrier, regenerated bone volume was typically reduced by remodeling after initially forming excessive bone.

Conclusion: BMP-2 demonstrates excellent ability for bone regeneration because of its osteoinductivity, but efficacy can be significantly different depending on its delivery system. ACS and FG showed relatively good bone regeneration capacity, satisfying the essential conditions of localization and release-control when used as BMP carriers. AAB could not provide release-control as a BMP carrier, but its space-maintenance role was remarkable. Carriers and scaffolds that can provide sufficient support to the BMP/carrier complex are necessary for large bone defects, and AAB is thought to be able to act as an effective scaffold. The CSD model of rat fibula is simple and useful for initial estimate of bone regeneration by agents including BMPs.

Key words: Bone regeneration, Bone morphogenetic proteins, Carrier, Autoclaved autogenous bone, Rat fibula

[paper submitted 2017. 7. 22 / revised 2017. 9. 14 / accepted 2017. 9. 20]

I. Introduction

Maxillofacial bone loss due to trauma, deformity, infection, or tumor ablation surgery requires reconstruction of bone defects and can causing many problems concerning aesthet-

ics, function, and psycho-social factors. Autogenous bone graft (autograft) is known to have the best prognosis due to its adequate osteogenesis, though many bone substitutes have been developed and used¹⁻³. In spite of this strong point, an autograft requires an additional operation at the donor site, causing issues including pain, scar, increased risk of infection, extension of the recovery period, and supply amount, limiting its use in the clinic⁴⁻⁷. For that reason, development of new bone substitutes is needed, and growth factors like bone morphogenetic proteins (BMPs) have been developed, mass produced, and clinically applied. In addition, proper drug carriers are required to make effective clinical use of the growth factors. Various materials including absorbable collagen sponge (ACS) and hydroxyapatite are used as BMP carriers clinically, but they are insufficient to achieve the

Hyung-Jun Kim

Department of Oral and Maxillofacial Surgery, Yonsei University College of Dentistry, 50-1 Yonsei-ro, Seodaemun-gu, Seoul 03722, Korea
TEL: +82-2-2228-3132 FAX: +82-2-2227-8256
E-mail: kimoms@yuhs.ac
ORCID: <http://orcid.org/0000-0002-3364-9995>

© This is an open-access article distributed under the terms of the Creative Commons Attribution Non-Commercial License (<http://creativecommons.org/licenses/by-nc/4.0/>), which permits unrestricted non-commercial use, distribution, and reproduction in any medium, provided the original work is properly cited.

Copyright © 2017 The Korean Association of Oral and Maxillofacial Surgeons. All rights reserved.

osteogenesis capacity of BMP. Therefore, much research on BMP carriers and concentration are ongoing. Since the mid-2000s, Department of Oral and Maxillofacial Surgery, Yonsei University College of Dentistry has performed several step-by-step experiments regarding bone regeneration capacity and carriers of BMP-2 using mass-produced recombinant human BMP-2 (rhBMP-2) through prokaryotic expression systems like *Escherichia coli* (ErhBMP-2) and two different animal models.

The first choice of animal for verification of BMP bone regeneration capacity is the rat. Rats are relatively inexpensive, plentiful, and hardy, making them excellent models for the initial testing of bone repair materials⁸. Rabbits are the largest animals in the small animal category requiring local animal ethical committee approval, so they are commonly used for screening bone graft materials prior to testing in larger animal models⁹. The sites used in rats and rabbits for evaluation of bone graft materials are calvaria, mandible, and long bones (femur, fibula)⁸. We evaluated the bone regeneration capacity of rhBMP-2 by forming critical sized segmental defects (CSDs) in the fibulae of rats and the radii of rabbits. CSD refers to a bone defect large enough that spontaneous healing does not occur, and it is known that a bone defect of about 6 mm including the periosteum in rat fibula and rabbit radius corresponds to a CSD of bone⁸.

In our study, Experiment 1 was performed with BMP-2 and ACS as a BMP carrier to evaluate bone regeneration capacity of BMP-2 in a CSD model of rat fibula. Experiment 2 was performed with BMP-2/ACS and xenogenic bone (porcine bone) in the same animal model for comparison of bone regeneration capacity between the materials. Experiment 3 used two completely different BMP carriers, autoclaved autogenous bone (AAB) and fibrin glue (FG) and was also performed in the rat fibula model. Based on these experiments, in Experiment 4, the bone regeneration capacities of AAB and BMP/BMP carrier complexes were evaluated through the CSD model of rabbit radius¹⁰.(Table 1)

The purpose of this study was to introduce our three experiments on BMP and BMP carriers performed using a rat fibula CSD model and to investigate development of animal models and carriers for more effective bone regeneration.

II. Materials and Methods

1. Animals

In Experiments 1, 2, and 3, 14, 16, and 24 8-week-old male

Table 1. Study design of four experiments for bone regeneration evaluation using BMP and BMP carriers

Animal model	Group	BMP (µg)	No. of sites	F/U period (wk)	Assessment methods	Purpose	Note
Experiment 1 Rat (fibula)	Exp. ErhBMP-2+ACS	10	14	2, 8	Gross finding, radiography,	To evaluate the ability for regeneration of bone using ErhBMP-2	
	Con. ACS only		14		Micro-CT,		
Experiment 2 Rat (fibula)	Exp. ErhBMP-2+ACS	10	16	4, 8	histomorphology	To compare ErhBMP-2 with xenogenic bone (CollaOss) for regeneration of bone	
	Exp. CollaOss ¹	0.25 (cc)	16				
Experiment 3 Rat (fibula)	Exp. ErhBMP-2+AAB	10	12	2, 4, 8		To evaluate and compare AAB and FG as BMP carriers	One rat in Group B (FG) died shortly after operation
	Con. AAB only		12				
Experiment 4 ² Rabbit (radius)	Exp. ErhBMP-2+FG	10	12			To validate the effects of AAB and FG on regeneration of bone	
	Con. FG only		12				
Experiment 4 ² Rabbit (radius)	Exp. ErhBMP-2+AAB+ACS	50	8	6, 12		To validate the effect of AAB as scaffold in rabbit	
	Exp. ErhBMP-2+AAB+FG	50	8				
	Con. AAB only		8			To evaluate and compare FG and ACS as BMP carriers in rabbit	

(BMP: bone morphogenetic protein, Exp.: experimental group, Con.: control group, ErhBMP-2: *Escherichia coli*-derived recombinant human BMP-2, ACS: absorbable collagen sponge, AAB: autoclaved autogenous bone, FG: fibrin glue, F/U: follow-up, Micro-CT: microtomography)

¹CollaOss: porcine bone and collagen (Bioland, Korea).

²Experiment 4 was already published in the article of Choi et al. (Maxillofac Plast Reconstr Surg 2014;36:94-102)¹⁰.

Experiment 1: the effect of ErhBMP-2/ACS on bone regeneration in a critical sized segmental defect in the rat fibula. Experiment 2: the effect of collagen-combined xenogenic bone (CollaOss) and ErhBMP-2/ACS on bone regeneration in a critical-size segmental defect in the rat fibula. Experiment 3: comparison of AAB and FG as BMP carriers for bone regeneration in a critical sized segmental defect in the rat fibula. Experiment 4: the bone regenerative properties of AAB as a scaffold and comparison of ErhBMP-2/AAB/ACS and ErhBMP-2/AAB/FG for bone regeneration in a critical sized segmental defect in the rabbit radius.

Sprague-Dawley (SD) rats weighting 250 to 300 g were used, respectively. The rats were maintained in plastic cages in a 12-hour light/12-hour dark cycle at a temperature of 21°C. They were provided water and standard feed pellets *ad libitum*. Animal selection, management, surgical protocols, and preparations were conducted in accordance with the guidelines approved by the Institutional Animal Care and Use Committee of the Department of Laboratory Animal Medicine, Medical Research Center, Yonsei University College of Medicine (approval no. 08-079, 10-075, and 2012-0155).

2. Agents and biomaterials

In all experiments, ErhBMP-2 (10 µg; BioAlpha Inc., Seongnam, Korea [Experiments 1 and 3] and CowellBMP; Cowellmedi, Busan, Korea [Experiment 2]) was used. In Experiment 1, ACS (Teruplug; Terumo Co., Tokyo, Japan) was used as a stand-alone carrier control. In Experiment 2, 0.25 cc of xenogenic bone (CollaOss; Bioland, Seoul, Korea) composed of porcine bone and collagen and ACS (Ateloplug; Bioland) as a BMP carrier were used. In Experiment 3, AAB (the segmented fibula bones of rats, autoclaved at 123°C, 0.2 MPa for 10 minutes) and FG (Tisseel; Baxter AG, Wien, Austria) were used as BMP carriers.

3. Surgical procedure and experimental design

In Experiments 1, 2, and 3, rats were sedated by intramuscular injection with Zoletil (0.06 mg/kg; Virbac, Carros, France) and Rumpun (0.04 mg/kg; BayerKorea, Seoul, Korea). Preparation for surgery such as shaving, scrubbing with 10% povidone-iodine solution, and local anesthesia with lidocaine including 1:100,000 epinephrine was performed. After skin incisions, the fibula bones were exposed, and bony defects with a critical size of 6 mm were created by segmenting both fibula bones of all SD rats⁸.(Fig. 1)

In Experiment 1, ACS dipped in 0.1 mg/mL ErhBMP-2 0.1 mL was applied to the right fibula defect for the experimental group, while only ACS was applied on the left for the control group.(Fig. 2. A)

In Experiment 2, there were two experimental groups using two different bone graft materials, xenogenic bone and rhBMP-2/ACS. The experiment used the control group of Experiment 1. In the first experimental group, 10 µg (0.1 mg/mL, 0.1 mL) of ErhBMP-2 with ACS was applied to the right side of the rat fibula. In the second experimental group, 0.25 cc of xenogenic bone (CollaOss) soaked in saline for more than 40 seconds was inserted on the left side of the rat fibula. (Fig. 2. B)

In Experiment 3, the animals were divided into two equal groups; Group A who received AAB as a BMP carrier and

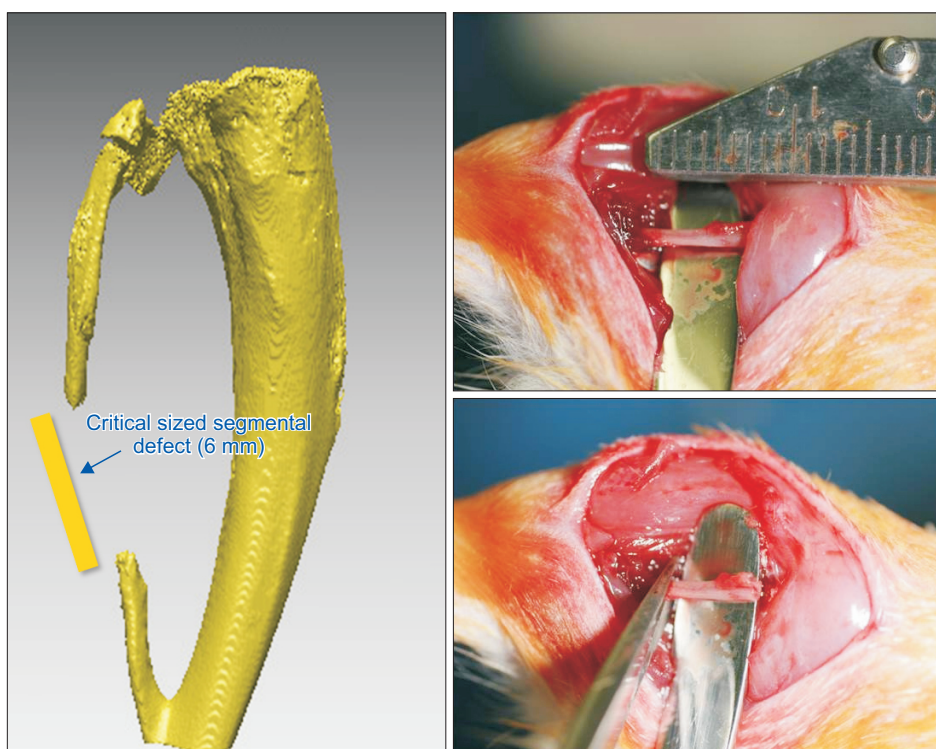


Fig. 1. A critical sized segmental defect of 6 mm was formed in rat fibula model.

Jung-Woo Nam et al: Stepwise verification of bone regeneration using recombinant human bone morphogenetic protein-2 in rat fibula model. *J Korean Assoc Oral Maxillofac Surg* 2017

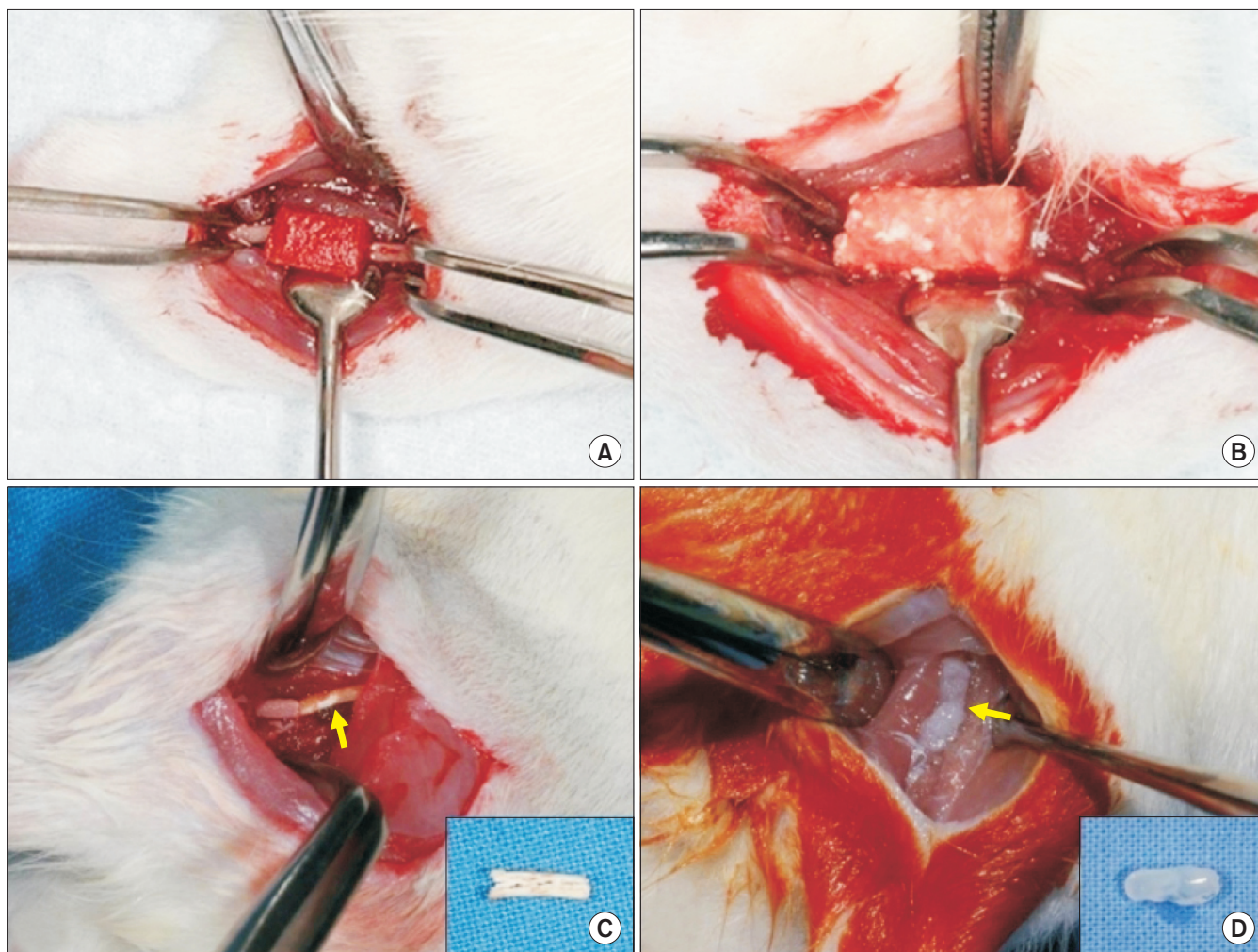


Fig. 2. Experimental sites of rat fibulae in Experiments 1-3. A. Absorbable collagen sponge with/without recombinant human bone morphogenetic protein-2 (rhBMP-2) in Experiments 1 and 2. B. Xenogenic bone (CollaOss; Bioland, Korea) in Experiment 2. C. Autoclaved autogenous bone (arrow, inset) with/without rhBMP-2 in Group A of Experiment 3. D. Fibrin glue block (arrow, inset) with/without rhBMP-2 in Group B of Experiment 3.

Jung-Woo Nam et al: Stepwise verification of bone regeneration using recombinant human bone morphogenetic protein-2 in rat fibula model. J Korean Assoc Oral Maxillofac Surg 2017

Group B who received FG for the same purpose. In the experimental group, the rhBMP-2 with carrier (AAB for Group A and FG for Group B) was inserted on the right fibula, while only the carrier was inserted on the left fibula in the control group. In Group A, the segmented fibula bones were autoclaved at 123°C, 0.2 MPa for 10 minutes, and they were repositioned to their original location within the muscle cuff. (Fig. 2. C) Only at the right experimental site, AAB was split, and ErhBMP-2 (0.2 mg/mL, 0.05 mL) was dropped into the rift with a micropipette. In Group B, FG blocks, sized 1.5×1.5×6.0 mm, were prefabricated and were positioned at the defect sites of the fibula.(Fig. 2. D) Only for the right experimental site, FG blocks including rhBMP-2 (0.2 mg/mL, 0.05 mL) were prepared.

Suturing was performed layer by layer with 4-0 Vicryl

(Ethicon, Somerville, NJ, USA) maintaining the muscle cuff in all experiments.

4. Histologic procedures and evaluation methods

In Experiment 1, seven rats were sacrificed in a CO₂ asphyxiation chamber at each the second and eighth weeks after the operation. In Experiment 2, eight rats were sacrificed at the fourth and eighth weeks. In Experiment 3, four rats were sacrificed at the second, fourth, and eighth weeks.

Regenerated bone at the operative site was assessed through gross, radiographic, and histomorphological evaluation. The legs of rats including fibula, tibia, and soft tissue were evaluated on plain X-ray (voltage=60 kV, current=70 mA, exposure=0.08 s) and micro-CT (microtomography,

SkyScan 1076; SkyScan, Kontich, Belgium; resolution=18 μm , voltage=100 kV, current=100 μA , filter=0.5 mm aluminum, exposure=1,180 ms, rotation step=0.500°/360° rotation). Three-dimensional reconstruction images of regenerated bone were acquired through the NRecon (reconstruction software; SkyScan). Additionally, in Experiments 1, 2, and 3, the density of regenerated fibula bone was compared with that of the ipsilateral tibia or residual native fibula using the DataViewer program (SkyScan).

The experimental sites were removed and fixed at 4°C in 4% paraformaldehyde/0.01 M phosphate-buffered saline (pH 7.4) for 24 hours. They were decalcified using formic acid-sodium formate at room temperature and then embedded in

paraffin. Serial, 7- μm -thick sections were cut, stained using H&E, and examined by optical and polarized microscopy.

III. Results

1. Gross and radiographic findings

All experimental groups using BMP-2 showed complete union of segmental bony defects with various amounts of regenerated bone. The 2-week groups showed ectopic, excessive, and irregular newly formed bone, and Group A of Experiment 3 had very excessive generated bone in the bony defects. In the 4-week groups using BMP-2, the size

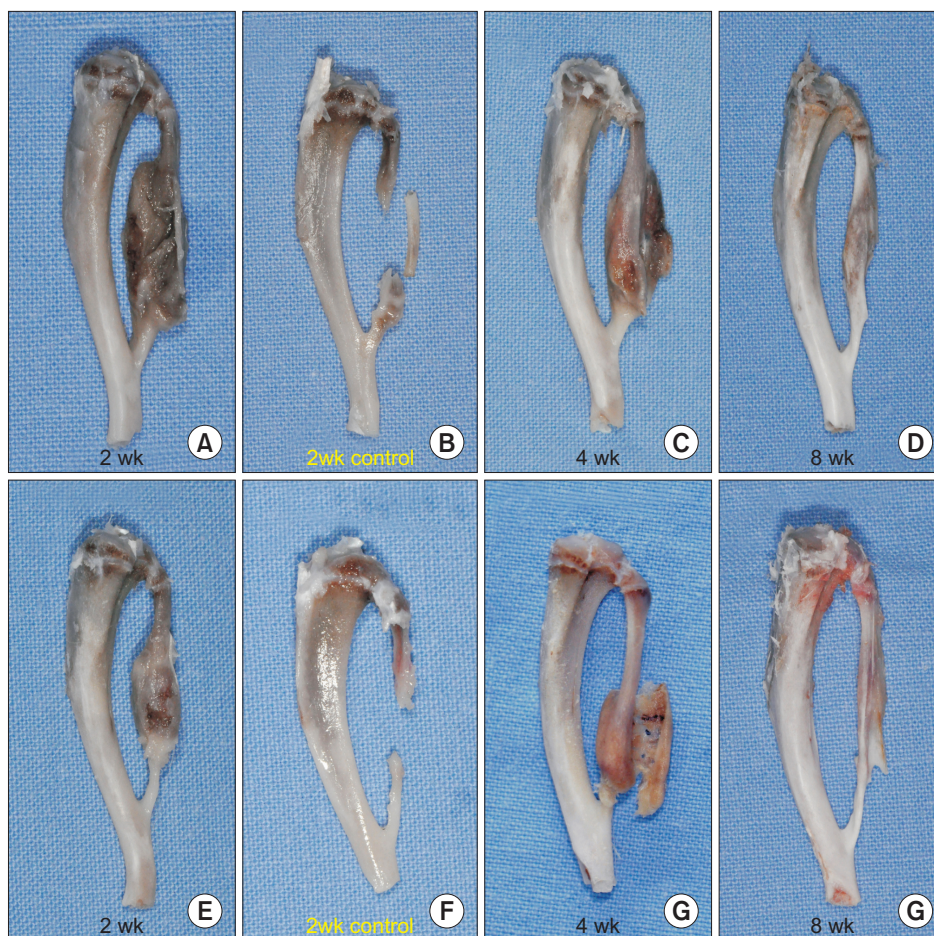

Fig. 3. Gross findings in Experiment 3 (A-D: Group A, E-H: Group B). A, C, D. The 2-, 4-, 8-week experimental groups with rhBMP-2/AAB. Complete bony unions were observed in all groups. The 2-week group showed an ectopic irregular and very excessive generated bone, but the amount of newly formed bone decreased over time through remodeling. E, G, H. The 2-, 4-, 8-week experimental groups with rhBMP-2/FG. Complete bony unions were observed in all groups as Group A. However, the new bone of the 2-week group was formed within relatively limited area comparing with Group A. In the 4-week group, similar or more newly formed bone was observed than in the 2-week group, and ectopic bony growth was also seen. In the 8-week group, a complete union having significantly diminishing the amount of regenerated bone than in the 4-week group was seen. B, F. The 2-week control groups with AAB or FG only. B. Non-union was observed between AAB and the residual fibula ends. F. Segmental bony defect remained on the fibula. (rhBMP-2: recombinant human bone morphogenetic protein-2, AAB: autoclaved autogenous bone, FG: fibrin glue)

Jung-Woo Nam et al: Stepwise verification of bone regeneration using recombinant human bone morphogenetic protein-2 in rat fibula model. *J Korean Assoc Oral Maxillofac Surg* 2017

of regenerated bone was significantly less than that of the 2-week groups except Group B of Experiment 3, which showed a similar amount of newly formed bone and ecto-

pic bony growth. The 8-week groups using BMP-2 showed significantly smaller amounts of newly regenerated bone, which was relatively regular and smooth and very similar in

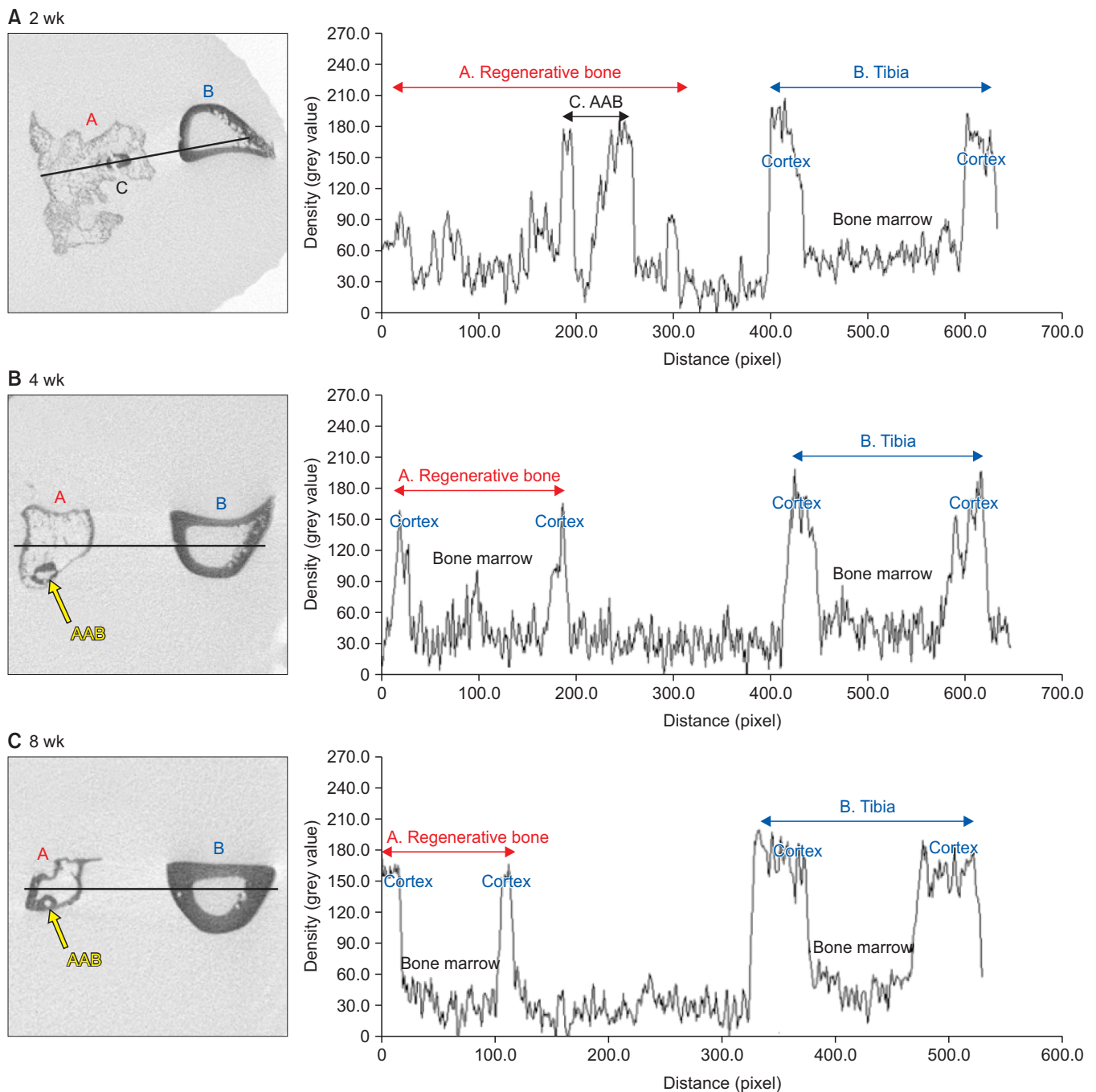


Fig. 4. Microtomography (micro-CT) findings in the experimental groups of Group A in Experiment 3. Comparison of the bone density between the tibia and the newly formed fibula using Micro-CT images. A. The 2-week group; A high-density bi-cortical bone and a low-density regular bone marrow was observed on the adjacent tibia, in contrast with the newly formed fibula bone, which showed an irregular pattern. A high-density bi-cortical bone was also observed on grafted autoclaved autogenous bone (AAB) area. B. The 4-week group; The newly formed fibula bone showed a similar bone density pattern as the adjacent tibia with lower intensity of its cortical portion. Both also showed a low-dense and regular bone marrow. C. The 8-week group; Compared with the 4-week group, the distribution of the bone density was similar to normal bone. The formation of a regular and low-dense cancellous bone was noticeable between the two peaks traced by the cortex of the newly formed bone.

Jung-Woo Nam et al: Stepwise verification of bone regeneration using recombinant human bone morphogenetic protein-2 in rat fibula model. J Korean Assoc Oral Maxillofac Surg 2017

shape and structure to that of the original fibula. On the other hand, all control groups using only carriers including ACS, AAB, FG showed no bony union on the segmental defects except for some of the 8-week groups with AAB or FG. Some 8-week control group with AAB showed bony unions

between repositioned AABs and residual fibulae when AAB was maintained in its original position. Half of the 8-week control group with FG showed near complete bony regeneration of the segmented fibula.(Fig. 3)

On micro-CT images of experimental groups using BMP-

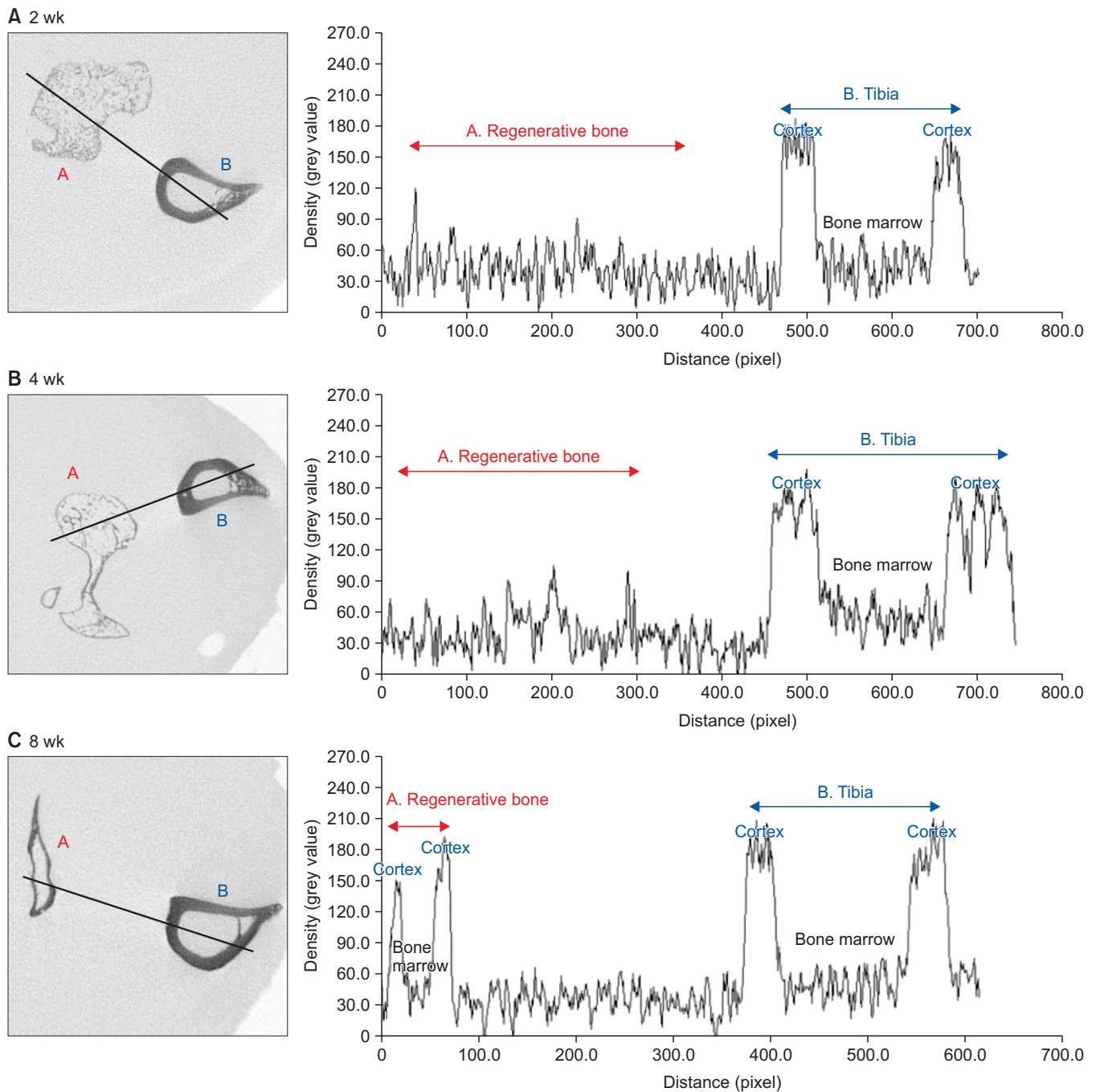


Fig. 5. Microtomography (micro-CT) findings in the experimental groups of Group B in Experiment 3. Comparison of the bone density between the tibia and the newly formed fibula using Micro-CT images. A. The 2-week group; In the adjacent tibia, a high dense cortical bone was seen as well as a regular and less dense inner cancellous bone. In the fibula site, an over-regenerated bone with an irregular bone density was observed. B. The 4-week group; Same findings as the 2-week experimental group with no remarkable change in bone density. C. The 8-week group; The density pattern of the newly formed fibula, composed of the cortical bone and bone marrow, was similar to that of the adjacent tibia.

Jung-Woo Nam et al: Stepwise verification of bone regeneration using recombinant human bone morphogenetic protein-2 in rat fibula model. *J Korean Assoc Oral Maxillofac Surg* 2017

2, the bone density of newly formed bone was comparatively low and irregular, unlike the adjacent tibia and residual fibula having high bone density of the cortex and low and regular density of bone marrow in the 2-week experimental groups. This pattern gradually changed to match that of the adjacent tibia and residual fibula, until near normal bone density patterns of long bones of low and regular bone marrow between high density cortical bones were observed in all 8-week groups. Specifically, the newly formed bone of the 4-week group showed a similar pattern of bone density as the 2-week group in Group B of Experiment 3.(Fig. 4, 5)

Unlike BMP-2 experiments, there was no bony union between porcine bone block and fibula bone in Experiment 2. Xenograft materials were maintained with their original shape at the experimental sites, were fixed in position with weak fibrous connections, and showed a slightly smaller amount in the 8-week group. On micro-CT images of xenograft groups of Experiment 2, the density of grafted bone was

irregular and high, different from normal fibula bone in all groups.(Fig. 6)

2. Histomorphological findings

In the 2-week experimental groups, newly formed fibula bone composed of immature woven bone, fibrous tissue, and numerous blood vessels was observed at the bony defect site. In Group A of Experiment 3, simultaneous bone remodeling surrounding the transplanted AAB was also observed. In Group B of Experiment 3, at low magnification, relatively regular and limited new bone formation was observed with progressive endochondral ossification in both borders between the existing fibula and the newly formed bone. In the 4-week groups using BMP-2, continuous connecting cortical bone was noticeable between remaining fibula bone and the newly formed bone, and the inner part was gradually replaced by bone marrow. In the 8-week groups using BMP-2, com-

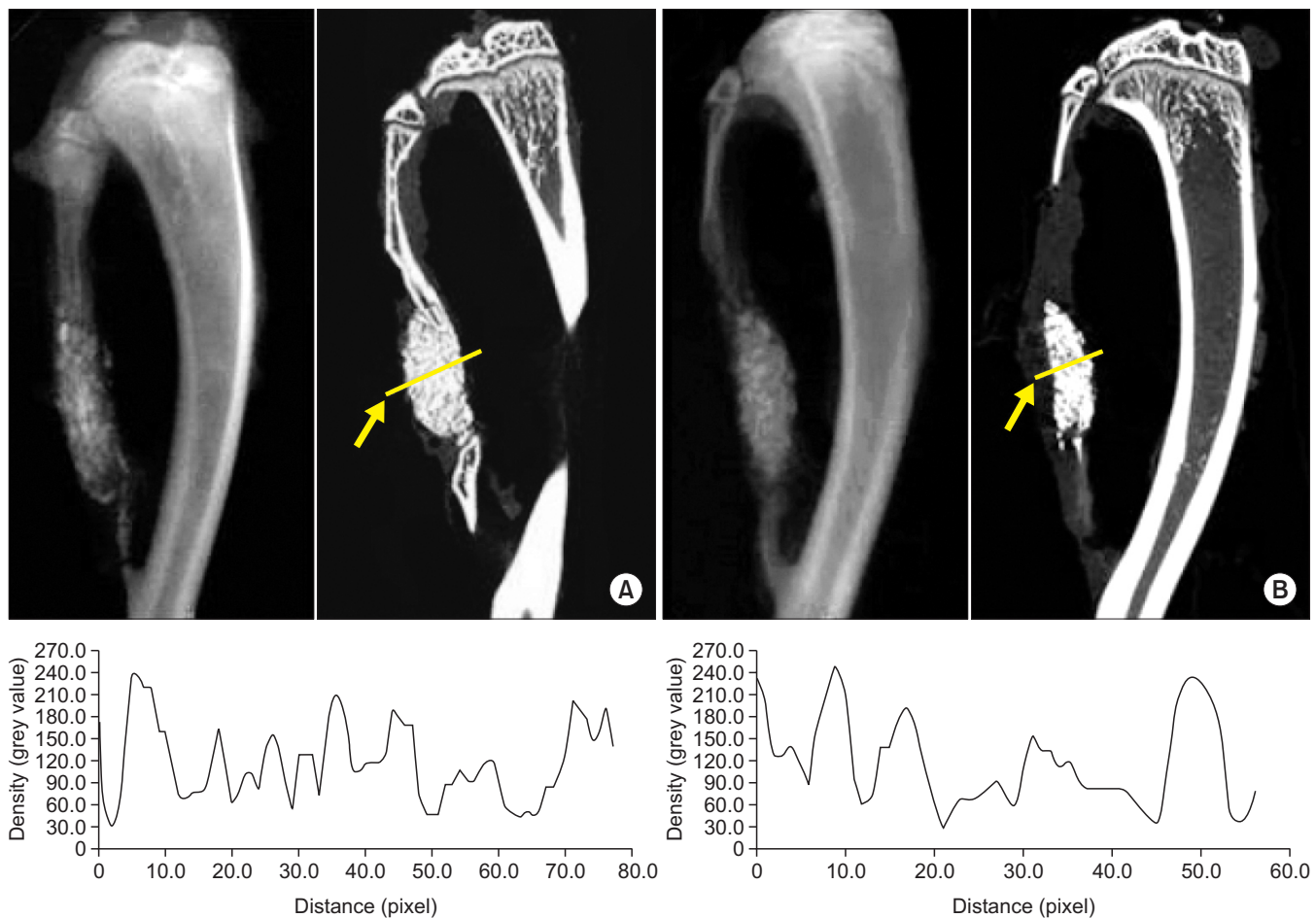


Fig. 6. Radiographic and microtomography findings in the xenograft groups in Experiment 2. A. The 4-week group; An irregular density of grafted material was observed (arrow). B. The 8-week group; Reduced grafted material with similar density pattern to the 4-week groups was observed (arrow).

Jung-Woo Nam et al: Stepwise verification of bone regeneration using recombinant human bone morphogenetic protein-2 in rat fibula model. J Korean Assoc Oral Maxillofac Surg 2017

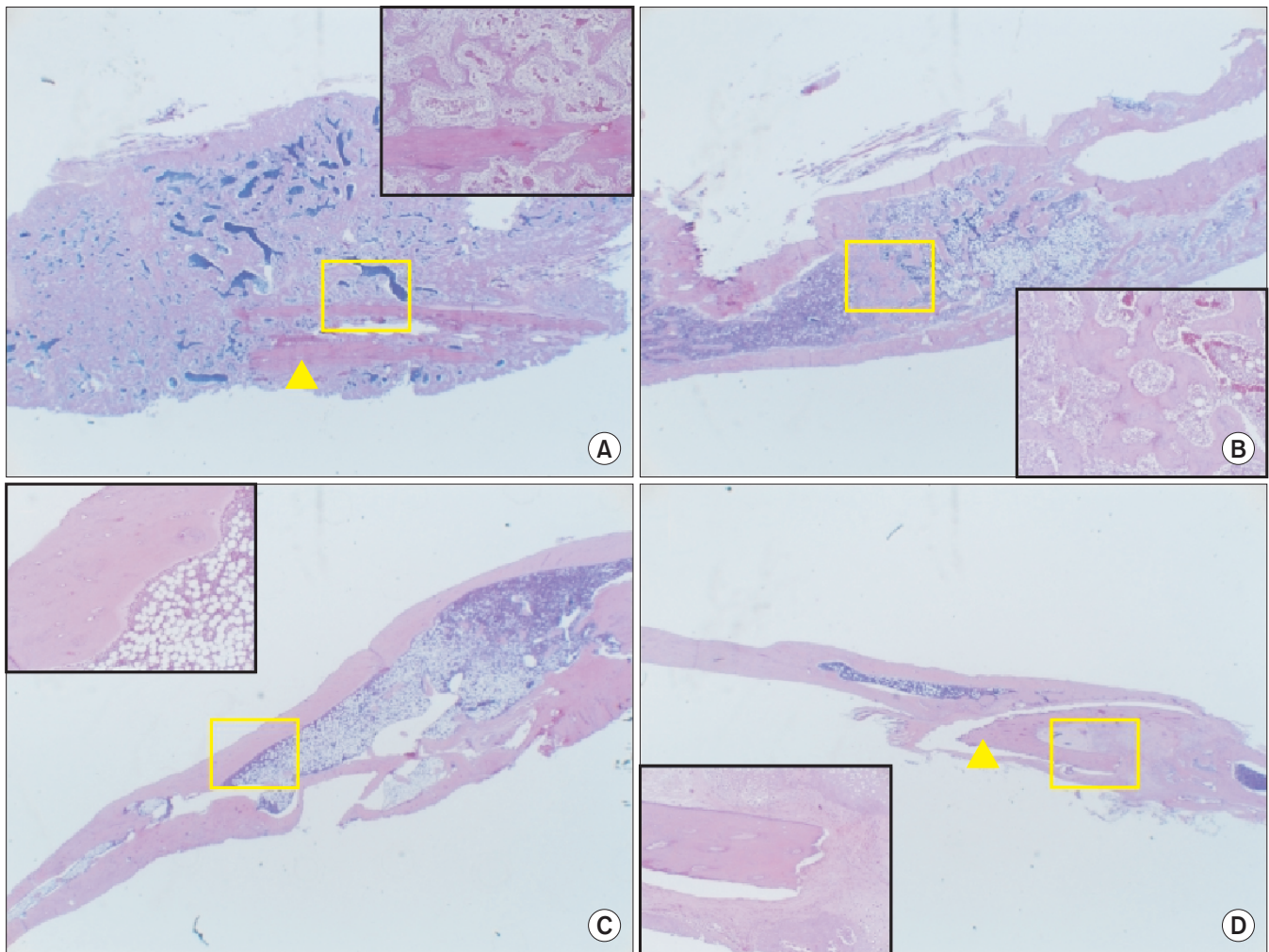


Fig. 7. Histomorphologic findings in Group A of Experiment 3 (H&E staining, A-D: $\times 10$, inset: $\times 100$). A. The 2-week experimental group; The formation of immature woven bone and simultaneous bone remodeling, surrounding the transplanted autoclaved autogenous bone (AAB) were observed (arrowhead). B. The 4-week experimental group; A continuous connecting cortical bone was noticeable between remaining fibula bone and newly formed bone and the inner part was gradually replaced by bone marrow. C. The 8-week experimental group; A complete union between the regenerated bone and the pre-existing fibula was observed with a continuous and homogeneous connection of the bone marrow and cortical bone. D. The 8-week control group; A complete union between the newly formed bone and the remaining fibula was observed. The new bone formation and ossification progress were seen surrounding the grafted AAB (arrowhead). *Jung-Woo Nam et al: Stepwise verification of bone regeneration using recombinant human bone morphogenetic protein-2 in rat fibula model. J Korean Assoc Oral Maxillofac Surg 2017*

plete union of bone defects, which showed continuous and homogeneous connection of the bone marrow and cortical bone, was observed, similar to the original fibula bone shape. Some 8-week control groups using only AAB or FG in Experiment 3 also showed complete union between the newly formed bone and the remaining fibula.(Fig. 7, 8)

In the xenograft group in Experiment 2, both 4- and 8-week groups showed no bony connection and only grafted bone material between the cut ends of fibula in low magnification. In high magnification, the grafted materials were seen with phagocytes and some woven bone formation. The fibrous unions were observed among particles of CollaOss and between CollaOss and fibula bone in both groups, but larger

amounts were noted in the 8-week group than the 4-week group. No aggregation of inflammatory cells was found in this group.

IV. Discussion

BMPs, a subfamily of transforming growth factor- β superfamily, are one of the most capable cytokines present in tissues and organs and play a role in development and regeneration of bone. Since first described by Urist in 1965, BMP has been shown to possess bone regeneration capacity and stability through preclinical experiments in various animal models^{7,11-13}. The Food and Drug Administration (FDA) ap-

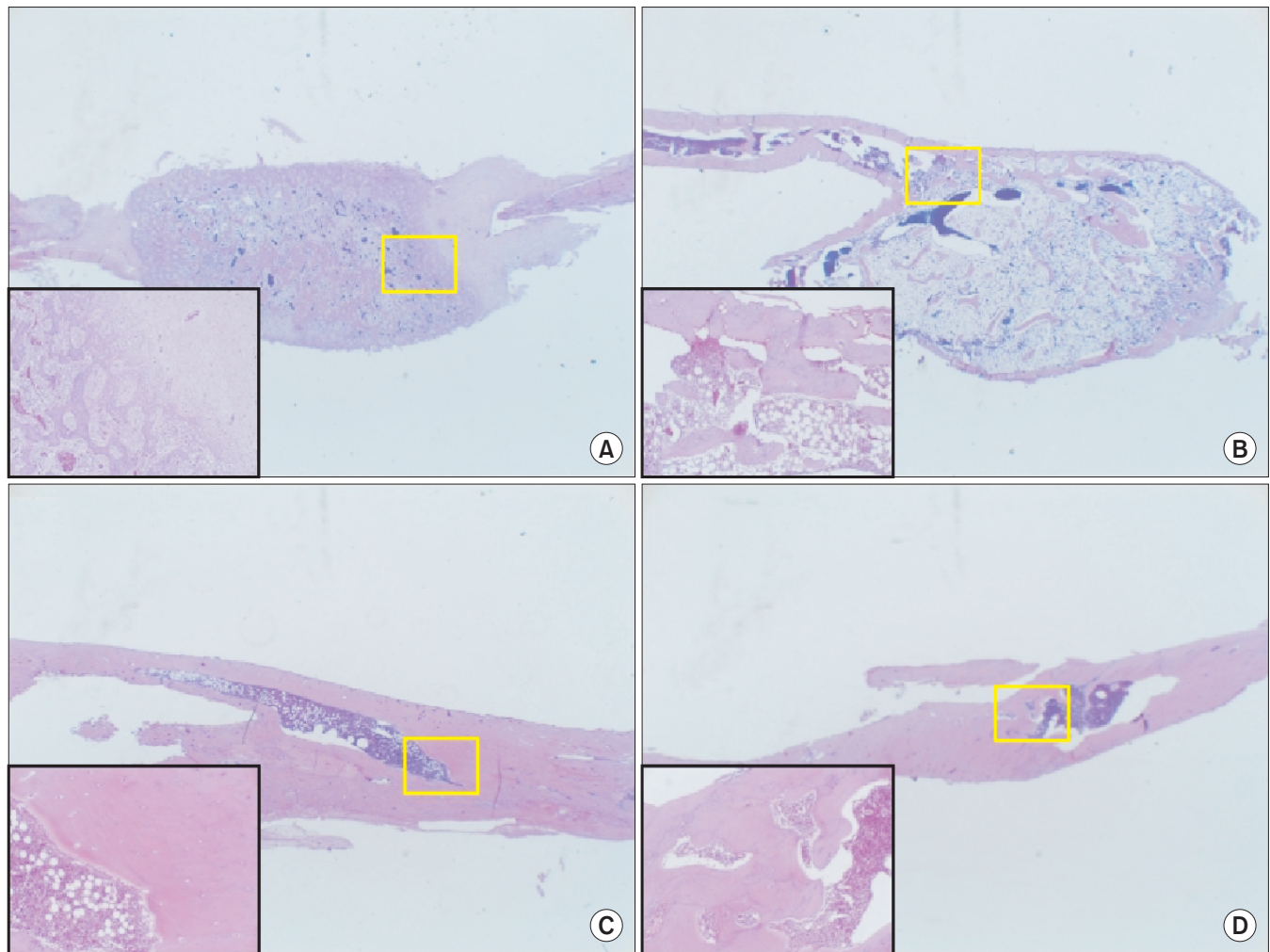


Fig. 8. Histomorphologic findings in Group B of Experiment 3 (H&E staining, A-D: $\times 10$, inset: $\times 100$). A. The 2-week experimental group; The newly formed bone was observed including endochondral ossification in the both borders near the existing fibula. B. The 4-week experimental group; The cortical layer of the newly formed bone showed a similar continuity as the remaining fibula. The inner part was gradually replaced by bone marrow. C, D. The 8-week experimental and control groups; Both experimental and control groups showed complete unions of the fibula defects.

Jung-Woo Nam et al: Stepwise verification of bone regeneration using recombinant human bone morphogenetic protein-2 in rat fibula model. J Korean Assoc Oral Maxillofac Surg 2017

proved the use of rhBMP-2 in spinal fusion (2000) and in open tibial fracture surgery (2004). In the oral and maxillofacial area, the application of rhBMP-2 for sinus augmentation and localized alveolar ridge augmentation was approved by the FDA in 2007^{6,7,13}. In the past, it was difficult to clinically use rhBMP, most of which was produced in mammalian cells such as Chinese hamster ovary cells, for reconstruction of bone defects because of low productivity and high cost^{12,14}. However, continued attempts finally produced rhBMP using a prokaryotic expression system of *E. coli* and evaluated biologically produced rhBMP with greater than 98% purity. The bone regeneration capacity of this material was verified *in vivo*, so mass production of rhBMP with a low price was made possible^{12,14}.

BMPs have a very short half-life of 1 to 4 hours, and they are reduced by 30% at an early stage since they undergo incomplete emission at higher than physiological concentration. In contrast to *in vitro* experiments, which can induce a cellular response with a small amount of BMP, rapid degradation of BMP and insufficient and inadequate tissue regeneration were observed in *in vivo* experiments. Because this action is not specific to bone tissue, proper BMP delivery systems are required for application to any sites in order to produce new bone in the desired shape¹⁵⁻¹⁸. The primary role of the BMP delivery system is to maintain growth factors in bone defect sites according to anatomical size, position, and vascularity of the defect site for regeneration and recovery of bone. It should allow the regenerative tissue forming cells to migrate

to the tissue defect site and to proliferate and differentiate¹⁵⁻¹⁷. Two requirements for these BMP carriers are ‘localized’ and ‘release-controlled’ delivery^{15,16}, and additional essential factors such as safety, efficiency, convenience, and economics should be satisfied for clinical application of BMP. Therefore, many types of delivery materials have been studied.

BMP carrier materials can be classified largely into four types—natural polymers, inorganic materials, synthetic biodegradable polymers, and composites. Natural polymers include collagen, currently used in clinics, and FG, alginate, and chitosan. Although they have several advantages including high biocompatibility, natural affinity for BMPs, and absorbable into physiological body fluids, they have disadvantages of immunogenicity, vection, and difficulty of sterilization. Inorganic materials are similar to bone and have benefits of osteoconduction capacity and affinity for BMPs, but they also have disadvantages of fragility, difficulty of manipulation, and heat emission in some materials. Calcium phosphate cements, bioactive glass, hydroxyapatite, hyaluronic acid, and tricalcium phosphates are included in this category. Synthetic biodegradable polymers include polylactic acid (PLA), polyglycolide (PLG), poly-L-lactic acid (PLLA), poly D, and L-lactide-co-glycolic acid (PLGA). Excellent mechanical and chemical properties and ease of manipulation and sterilization are advantages of these materials, but they can have problems with inflammatory response, restriction of biological function, and decreased local tissue acidity (pH). Finally, composites are made by combination of such material as different biomolecules, but the production process is difficult^{16,17}.

Among these many carrier materials, ACS is the most widely used in clinics, and many satisfactory results from BMP/ACS complexes have been reported for reconstruction of bone defects^{4-7,13,19}. ACS, a BMP carrier of natural origin, has merits of collagen binding to BMP and immediate infiltration by cells and reformation to bone tissue¹⁸. A large number of *in vivo* studies and clinical experiments of BMP/ACS have been conducted, showing successful results similar to those with autogenous bone graft¹⁶. However, ACS also has some limitations for clinical application such as insufficient ability of space maintenance, difficulty in manipulation, and problems of immunogenicity. In fact, it was reported that 20% of patients who were treated with rhBMP-2/ACS showed anti-type I collagen antibodies because of its xenogenic nature^{16,18}.

The action of FG, another material used as a carrier, is similar to the last step of the coagulation pathway and utilizes

the mechanism of fibrin clotting, as fibrin-fibronectin and thrombin are mixed, regardless of the patient’s coagulation process. FG has the effect of promoting hemostasis, tissue adhesion, and wound healing, and some studies found that fibrin clots supported growth, adhesion, migration, and differentiation of osteoblasts *in vitro*^{20,21}. On the other hand, there are opposing reports that FG suppressed the process of bony healing or formation²². The use of FG as a BMP carrier has been introduced, and relatively successful results were reported in several studies. The efficacy of FG as a BMP carrier was demonstrated to some degree, and there are clinical advantages in areas such as osteoconduction capacity, *in vivo* absorption, convenience of use, and ability to control bone growth by slowly releasing BMP compared to ACS. However, FG also lacks the ability to maintain space against compression of soft tissue, which can interfere with formation of new bone and tissues. Therefore, improvement of FG application methods or its use combined with other biological materials is needed to use FG as an effective BMP carrier²⁰⁻²⁴.

Although surgeons currently use rigid frames such as mesh type metal plates to maintain space for bone regeneration when they use ACS as a BMP carrier, this often requires secondary surgeries for complications following insertion of graft materials, as well as functional and aesthetic rehabilitation²⁵. If the removed bone can be used as a BMP carrier for immediate reconstruction by repositioning after eradicating pathological tissues or infection sources, there are several expected advantages in the healing process, function, aesthetics, and ease of operation²⁶⁻³⁰. Although AAB has not been introduced as a BMP carrier, it is a useful technique that has been used clinically for patients with open fractures, tumors, or infectious disease since the first use of heat-treated bone as a graft material by Gallie in 1918 and the reimplantation of AAB in an osteosarcoma patient by Orell in 1937^{25,26}. The efficacy of AAB has been verified through many clinical and pre-clinical studies. Based on previous findings, there are some considerations for use of AAB as follows.

First, the autoclaved bone can preserve not only osteoconductivity, but also osteoinductivity depending on the temperature of autoclaving. There is no limitation to use as an allograft or autograft due to control of infection from virus or bacteria and destruction of tumor cells. It also has a satisfactory mechanical property^{26,27,29-34}. Furthermore, when AAB is used as an autograft, there is no need to consider antigenicity or donor sites, and it can be easy to use. It can enable reconstruction of bone defects with original appearance, so it has excellent functional and aesthetic advantages²⁸⁻³⁰. However,

Table 2. Relative comparison of the amount of bone regeneration on segmental defects of fibulae in rats; Experiments 1, 2, and 3

Experiment	Group	Materials	2-wk	4-wk	8-wk
1	Exp.	BMP-2+ACS	+++		++
	Con.	ACS only	0		0
2	A	Exp. BMP-2+ACS		++/+++	++
	B	Exp. CollaOss ¹		0/+	0/+
3	A	Exp. BMP-2+AAB	++++	+++	++
		Con. AAB only	0	-/0	+/>++
	B	Exp. BMP-2+FG	+++/>++++	+++/>++++	++
		Con. FG only	0	-/0	+/>++

(Exp.: experimental group, Con.: control group, BMP: bone morphogenetic protein, ACS: absorbable collagen sponge, AAB: autoclaved autogenous bone, FG: fibrin glue)

¹CollaOss: porcine bone and collagen (Bioland, Korea).

0: no change of size of segmental bony defects, -: widening of segmental bony defects by resorption of cut ends of fibulae, +: new bone formation without complete unions of segmental bony defects, ++: complete unions of segmental bony defects with newly formed bone, similar to original shape of fibulae, +++: complete unions of segmental bony defects with overgrowing newly formed bone (mild), ++++: complete unions of segmental bony defects with overgrowing newly formed bone (more than mild).

Experiment 1: the effect of ErhBMP-2/ACS on bone regeneration in a critical sized segmental defect in the rat fibula.

Experiment 2: the effect of collagen-combined xenogenic bone (CollaOss) and ErhBMP-2/ACS on bone regeneration in a critical-size segmental defect in the rat fibula; Group A: BMP-2/ACS group, Group B: CollaOss group.

Experiment 3: comparison of AAB and FG as BMP carriers for bone regeneration in a critical sized segmental defect in the rat fibula; Group A: AAB group (with/without BMP-2), Group B: FG group (with/without BMP-2).

Jung-Woo Nam et al: Stepwise verification of bone regeneration using recombinant human bone morphogenetic protein-2 in rat fibula model. J Korean Assoc Oral Maxillofac Surg 2017

re-implantation of contaminated devitalized bone can cause infection or osteomyelitis, so AAB should not be applied in all cases and should be chosen only after considering risk of infection, age, and occupation of patients; the status of contaminated bone fragments; the possibility for autograft or allograft; the degree of importance of complete reduction of bone in order to maintain anatomical structure and function; and the patient's wishes²⁸. Focusing on these points, BMP bone regeneration capacity was evaluated using AAB as a BMP carrier in Experiment 3 of this study.

Through the three experiments presented in this study, we established the following findings.

1. The effect of BMP-2 for bone regeneration (Table 2)

1) Bone regeneration capacity of BMP-2

Excellent bone regeneration capacity was confirmed through Experiments 1-3. All experimental groups showed significant bone formation compared to the control groups. Although there was a slight difference depending on the BMP carrier, a pattern was generally observed that the volume of regenerated bone was reduced by remodeling after initially forming excessive bone. Especially in Group A of Experiment 3, which used AAB as a carrier with low BMP retention, excessive ectopic bone formation was observed, and we ascertained the osteoinduction capacity of BMP. Histomorphologically, the new bone formation appeared simultaneously at the sites of applied BMP-2/carrier complex,

and the interior of regenerated bone was replaced with bone marrow, while the periphery was corticated gradually, forming a lamellar structure with time. This process was similar to the growth process of long bone in which the bone matures from a primary ossification center to a medullary cavity with surrounding compact bone. Bone density analysis with micro-CT showed that the bone newly generated by BMP was similar to the surrounding normal bone, which had a very dense outer cortical bone and a bone marrow cavity with low regular density.

2) Comparison with xenogenic bone graft material

In Experiment 2, through comparison with other bone graft materials, we were able to confirm the significant bone formation capacity of BMP-2. The compared bone graft material was porcine bone, which is one of the most widely clinically used materials with bovine bone^{35,36}. Bones of these animals are mainly composed of carbonated hydroxyapatite and type I collagen, similar to human bone in biochemical structure³⁷. Therefore, use of these xenograft materials can improve the healing mechanism by minimizing the absorption of existing bone and working as a scaffold for newly forming bone³⁵. Bovine bone is the oldest and the most popular xenogenic bone, but it has a potential risk of variant Creutzfeldt-Jakob disease (vCJD). Porcine bone has a relatively low risk of vCJD, so it has recently been in wider use. In our experiment, there was a significant difference of degree of bone formation between the groups of BMP-2/ACS and CollaOss, and it was

thought to be due to osteoinduction capacity.

2. Evaluation of biomaterials for a BMP carrier (Table 2)

1) ACS

The ACS showed relatively good capacity for bone regeneration when it was used as a BMP carrier in Experiment 1 and Experiment 2. In the 2-week experimental group, complete bony union of the defect was observed with slightly excessive newly formed bone. It tended to be gradually remodeled, changing appearance and internal structure similar to the original fibula shape in the 4- and 8-week experimental groups. On the other hand, in the control group using ACS only, there was no significant change of bony defects in both the 2- and 8-week groups.

2) FG

In Experiment 3, it was observed that FG as a BMP carrier satisfied the essential conditions of localization and release-control of BMP to some extent. In the 2-week experimental group, relatively less newly formed bone with a nearly regular shape was observed compared to Group A, using AAB as a BMP carrier. A similar amount of new bone was observed in the 4-week experimental group as in the 2-week group, unlike Group A. It was considered that continuous bone formation appeared on confined sites around the graft material due to local slow extrication of rhBMP-2 from FG, compared to AAB. In the 8-week experimental group, the volume of newly formed bone was significantly less compared to the 4-week group, and it was considered as a result following remodeling of newly generated bone like other experimental groups. On the other hand, in the control experiments, the 2- and 4-week groups showed persistent bony defects, while 2 rats of the 8-week group showed comparatively favorable regeneration of bony defect sites, though the shapes of lamellar bone and the marrow cavity were not definite compared to the experimental groups. This result illustrates the osteoconductive capacity of the FG, and the inability of FG to maintain space for bone regeneration was thought to cause incomplete bone regeneration in the other 2 rats.

3) AAB

AAB was used as a BMP carrier in Experiment 3 in order to focus on its 'space maintenance' ability, while its 'release control' was not expected to be adequate. In the 2-week experimental group, excessive bone formation by rhBMP-2 was observed, but its size diminished gradually in the 4- and

8-week groups. The excessive ectopic new bone formation was thought to be caused by uncontrolled release of a large quantity of BMP into the surroundings rather than the intended local sites in the early stage after grafting rhBMP-2/AAB. In the 4- and 8-week experimental groups, the amount gradually decreased and the shape regularized through active bone remodeling. On the other hand, in the 2-week control group, separation of AAB segments and residual fibulae were observed, while weak fibrous unions between AABs and fibulae were seen in the 4-week control group. In the 8-week control group, newly formed bones around some of repositioned AAB segments to bony defect sites, well maintained original position in muscle cuff, were formed showing bony unions including slight fibrous unions. This was thought to prove the osteoconduction capacity of AAB. If researchers fixed AAB segments after repositioning, most individuals would show similar results.

Additionally, in the subsequent experiment (Experiment 4)¹⁰ using rabbits for application of the combined BMP/carrier/scaffold, we concluded through quantitative analysis using micro-CT and histomorphological analysis that AAB itself had osteoconduction capacity, and that the osteoinduction capacity of BMP-2 was more effective when using ACS than FG as a carrier. In addition, application of the combination of BMP-2/ACS with AAB as a scaffold showed favorable results for bone defect healing. However, when internal fixation was carried out on rabbit radial bone, healing was delayed rather than accelerated because the bone was small and had a thin cortex, causing difficulty with internal fixation, and it induced occlusion of bone marrow. Therefore, further consideration of animal models and methods for BMP-2 experiments is necessary.

V. Conclusion

Through stepwise animal experiments of rhBMP-2, we could ascertain the bone regeneration capacity of BMP-2 and future study directions for clinically extended applications. BMP is much more stable and demonstrates an excellent ability for bone regeneration compared to xenogenic (porcine) bone graft material because of its osteoinduction capacity, but efficacy can be significantly different depending on its carrier. In addition to BMP carriers, scaffolds can provide enough support for the BMP complex that is required for large bone defect sites, and AAB is thought to be a suitable substitute.

For application of BMP/carrier/scaffold complex to the oral and maxillofacial area, jaw experimental models of large

animal are necessary because of jaw reconstruction difficulty due to masticatory stresses, possibility of contamination with oral microbial flora, and appearance⁸. In conjunction with the development of new bone graft materials such as BMP and ideal carriers, the development of jaw experimental models in large animals is necessary for verification of new bone material complex application in clinical practice.

Conflict of Interest

No potential conflict of interest relevant to this article was reported.

ORCID

Jung-Woo Nam, <http://orcid.org/0000-0002-3445-5690>

Hyung-Jun Kim, <http://orcid.org/0000-0002-3364-9995>

References

1. Boyne PJ. Osseous reconstruction of the maxilla and the mandible: surgical techniques using titanium mesh and bone mineral. *Implant Dentistry* 1998;7:378-9.
2. Hausamen JE, Neukam FW. Transplantation of bones. *Eur Arch Otorhinolaryngol Suppl* 1992;1:163-77.
3. Hopp SG, Dahners LE, Gilbert JA. A study of the mechanical strength of long bone defects treated with various bone autograft substitutes: an experimental investigation in the rabbit. *J Orthop Res* 1989;7:579-84.
4. Dickinson BP, Ashley RK, Wasson KL, O'Hara C, Gabbay J, Heller JB, et al. Reduced morbidity and improved healing with bone morphogenic protein-2 in older patients with alveolar cleft defects. *Plast Reconstr Surg* 2008;121:209-17.
5. Fallucco MA, Carstens MH. Primary reconstruction of alveolar clefts using recombinant human bone morphogenic protein-2: clinical and radiographic outcomes. *J Craniofac Surg* 2009;20 Suppl 2:1759-64.
6. Herford AS. rhBMP-2 as an option for reconstructing mandibular continuity defects. *J Oral Maxillofac Surg* 2009;67:2679-84.
7. Herford AS, Boyne PJ. Reconstruction of mandibular continuity defects with bone morphogenetic protein-2 (rhBMP-2). *J Oral Maxillofac Surg* 2008;66:616-24.
8. Hollinger JO, Kleinschmidt JC. The critical size defect as an experimental model to test bone repair materials. *J Craniofac Surg* 1990;1:60-8.
9. Mapara M, Thomas BS, Bhat KM. Rabbit as an animal model for experimental research. *Dent Res J (Isfahan)* 2012;9:111-8.
10. Choi EJ, Kang SH, Kwon HJ, Cho SW, Kim HJ. Bone healing properties of autoclaved autogenous bone grafts incorporating recombinant human bone morphogenetic protein-2 and comparison of two delivery systems in a segmental rabbit radius defect. *Maxillofac Plast Reconstr Surg* 2014;36:94-102.
11. Boyne PJ, Marx RE, Nevins M, Triplett G, Lazaro E, Lilly LC, et al. A feasibility study evaluating rhBMP-2/absorbable collagen sponge for maxillary sinus floor augmentation. *Int J Periodontics Restorative Dent* 1997;17:11-25.
12. Lee JH, Kim CS, Choi KH, Jung UW, Yun JH, Choi SH, et al. The induction of bone formation in rat calvarial defects and subcutaneous tissues by recombinant human BMP-2, produced in *Escherichia coli*. *Biomaterials* 2010;31:3512-9.
13. McKay WF, Peckham SM, Badura JM. A comprehensive clinical review of recombinant human bone morphogenetic protein-2 (INFUSE Bone Graft). *Int Orthop* 2007;31:729-34.
14. Kübler NR, Reuther JF, Faller G, Kirchner T, Ruppert R, Sebald W. Inductive properties of recombinant human BMP-2 produced in a bacterial expression system. *Int J Oral Maxillofac Surg* 1998;27:305-9.
15. Haidar ZS, Hamdy RC, Tabrizian M. Delivery of recombinant bone morphogenetic proteins for bone regeneration and repair. Part A: current challenges in BMP delivery. *Biotechnol Lett* 2009;31:1817-24.
16. Haidar ZS, Hamdy RC, Tabrizian M. Delivery of recombinant bone morphogenetic proteins for bone regeneration and repair. Part B: delivery systems for BMPs in orthopaedic and craniofacial tissue engineering. *Biotechnol Lett* 2009;31:1825-35.
17. Issa JP, Bentley MV, Iyomasa MM, Sebald W, De Albuquerque RF. Sustained release carriers used to delivery bone morphogenetic proteins in the bone healing process. *Anat Histol Embryol* 2008;37:181-7.
18. Jung RE, Weber FE, Thoma DS, Ehrbar M, Cochran DL, Hammerle CH. Bone morphogenetic protein-2 enhances bone formation when delivered by a synthetic matrix containing hydroxyapatite/tricalciumphosphate. *Clin Oral Implants Res* 2008;19:188-95.
19. Wikesjö UM, Qahash M, Huang YH, Xiropaidis A, Polimeni G, Susin C. Bone morphogenetic proteins for periodontal and alveolar indications; biological observations--clinical implications. *Orthod Craniofac Res* 2009;12:263-70.
20. Han DK, Kim CS, Jung UW, Chai JK, Choi SH, Kim CK, et al. Effect of a fibrin-fibronectin sealing system as a carrier for recombinant human bone morphogenetic protein-4 on bone formation in rat calvarial defects. *J Periodontol* 2005;76:2216-22.
21. Hong SJ, Kim CS, Han DK, Cho IH, Jung UW, Choi SH, et al. The effect of a fibrin-fibronectin/beta-tricalcium phosphate/recombinant human bone morphogenetic protein-2 system on bone formation in rat calvarial defects. *Biomaterials* 2006;27:3810-6.
22. Patel VV, Zhao L, Wong P, Kanim L, Bae HW, Pradhan BB, et al. Controlling bone morphogenetic protein diffusion and bone morphogenetic protein-stimulated bone growth using fibrin glue. *Spine (Phila Pa 1976)* 2006;31:1201-6.
23. Kim HJ, Kang SW, Lim HC, Han SB, Lee JS, Prasad L, et al. The role of transforming growth factor-beta and bone morphogenetic protein with fibrin glue in healing of bone-tendon junction injury. *Connect Tissue Res* 2007;48:309-15.
24. Patel VV, Zhao L, Wong P, Pradhan BB, Bae HW, Kanim L, et al. An in vitro and in vivo analysis of fibrin glue use to control bone morphogenetic protein diffusion and bone morphogenetic protein-stimulated bone growth. *Spine J* 2006;6:397-403; discussion 404.
25. Lee JG, Lee EW. Healing process of the reimplanted autoclaved autogenous mandible in adult dogs. *J Korean Assoc Oral Maxillofac Surg* 1993;19:514-32.
26. Böhm P, Springfield R, Springer H. Re-implantation of autoclaved bone segments in musculoskeletal tumor surgery. Clinical experience in 9 patients followed for 1.1-8.4 years and review of the literature. *Arch Orthop Trauma Surg* 1998;118:57-65.
27. Ito T, Sakano S, Sato K, Sugiura H, Iwata H, Murata Y, et al. Sensitivity of osteoinductive activity of demineralized and defatted rat femur to temperature and duration of heating. *Clin Orthop Relat Res* 1995;(316):267-75.
28. Kao JT, Comstock C. Reimplantation of a contaminated and devitalized bone fragment after autoclaving in an open fracture. *J Orthop Trauma* 1995;9:336-40.
29. Sugiura H, Yamamura S, Sato K, Katagiri H, Nishida Y, Nakashima H, et al. Remodelling and healing process of moderately heat-treated bone grafts after wide resection of bone and soft-tissue tumors. *Arch Orthop Trauma Surg* 2003;123:514-20.
30. von Wilmsowsky C, Schwarz S, Kerl JM, Srour S, Lell M, Felszeghy E, et al. Reconstruction of a mandibular defect with autogenous, autoclaved bone grafts and tissue engineering: an in vivo

- pilot study. *J Biomed Mater Res A* 2010;93:1510-8.
31. Izawa H, Hachiya Y, Kawai T, Muramatsu K, Narita Y, Ban N, et al. The effect of heat-treated human bone morphogenetic protein on clinical implantation. *Clin Orthop Relat Res* 2001;(390):252-8.
 32. Smith WS, Struhl S. Replantation of an autoclaved autogenous segment of bone for treatment of chondrosarcoma. Long-term follow up. *J Bone Joint Surg Am* 1988;70:70-5.
 33. Shimizu K, Masumi S, Yano H, Fukunaga T, Ikebe S, Shin S. Revascularization and new bone formation in heat-treated bone grafts. *Arch Orthop Trauma Surg* 1999;119:57-61.
 34. Shin S, Yano H, Fukunaga T, Ikebe S, Shimizu K, Kaku N, et al. Biomechanical properties of heat-treated bone grafts. *Arch Orthop Trauma Surg* 2005;125:1-5.
 35. Crespi R, Capparè P, Gherlone E. Comparison of magnesium-enriched hydroxyapatite and porcine bone in human extraction socket healing: a histologic and histomorphometric evaluation. *Int J Oral Maxillofac Implants* 2011;26:1057-62.
 36. Scarano A, Piattelli A, Perrotti V, Manzon L, Iezzi G. Maxillary sinus augmentation in humans using cortical porcine bone: a histological and histomorphometrical evaluation after 4 and 6 months. *Clin Implant Dent Relat Res* 2011;13:13-8.
 37. Figueiredo M, Henriques J, Martins G, Guerra F, Judas F, Figueiredo H. Physicochemical characterization of biomaterials commonly used in dentistry as bone substitutes--comparison with human bone. *J Biomed Mater Res B Appl Biomater* 2010;92:409-19.