



## Oral lesions associated with human immunodeficiency virus in 75 adult patients: a clinical study

Antoine Berberi<sup>1</sup>, Georges Aoun<sup>2</sup>

Departments of<sup>1</sup>Oral and Maxillofacial Surgery and<sup>2</sup>Oral Medicine and Diagnosis, School of Dentistry, Lebanese University, Beirut, Lebanon

**Abstract** (J Korean Assoc Oral Maxillofac Surg 2017;43:388-394)

**Objectives:** The objective of this study was to investigate the presence of oral lesions in human immunodeficiency virus/acquired immunodeficiency syndrome (HIV/AIDS) patients in a descriptive cross-sectional study, and to establish their presence according to levels of CD4+ cells (including the CD4+/CD8+ cell ratio).

**Materials and Methods:** A total of 75 patients infected with HIV were included. Oral lesions were observed and classified using World Health Organization classification guidelines. Potential correlations between the presence and severity of oral lesions and CD4+ cells, including the CD4+/CD8+ cell ratio, were studied.

**Results:** The most frequent oral lesion detected was oral pseudomembranous candidiasis (80.0%), followed by periodontal disease (40.0%), herpetic lesions (16.0%), hairy leukoplakia (16.0%), gingivitis (20.0%), oral ulceration (12.0%), Kaposi's sarcoma (8.0%), and non-Hodgkin's lymphoma (4.0%). The CD4+ count was <200 cells/mm<sup>3</sup> in 45 cases (60.0%), between 200-500 cells/mm<sup>3</sup> in 18 cases (24.0%), and >500 cells/mm<sup>3</sup> in 12 cases (16.0%). The mean CD4+ count was 182.18 cells/mm<sup>3</sup>. The mean ratio of CD4+/CD8+ cells was 0.26. All patients showed at least one oral manifestation.

**Conclusion:** There was no correlation between the CD4+/CD8+ cell ratio and the presence of oral lesions. The severity of the lesions was more pronounced when the CD4+ cell count was less than 200 cells/mm<sup>3</sup>.

**Key words:** Acquired immunodeficiency syndrome, CD4+, HIV, Oral lesions

[paper submitted 2017. 7. 22 / revised 2017. 9. 12 / accepted 2017. 9. 20]

### I. Introduction

Acquired immunodeficiency syndrome (AIDS) is the disease of the immune system triggered by infection with human immunodeficiency virus (HIV). The virus will gradually destroy the immune system, which makes it difficult for the body to fight infections<sup>1</sup>. This leaves the patient vulnerable to opportunistic infections<sup>2</sup>. HIV/AIDS constitutes a worldwide pandemic<sup>1,2</sup>.

In 2015, approximately 36.7 million people (34.0-39.8 million people) had HIV worldwide, and 2.1 million people

(1.8-2.4 million people) became newly infected with HIV. As of December 2015, 17 million people living with HIV were accessing antiretroviral therapy. In 2015, 1.1 million people (0.94-1.3 million people) died from AIDS<sup>3</sup>.

The late expression of HIV infection is characterized by state of complete immunodeficiency, caused by diminished CD4+ (cluster of differentiation 4) cells<sup>4</sup>. Thus, the CD4+ cell level serves as a marker of disease progression<sup>4,5</sup>. Within the evolution of disease, the CD4+ cell count generally decreases about 30%, whereas the CD8+ (cluster of differentiation 8) cell count may increase about 40%. This results in an inverted CD4+/CD8+ cell ratio that is usually less than 1 (while the normal ratio may vary between 0.9 and 3.7)<sup>6,7</sup>.

There are 40 known oral lesions of AIDS according to the European Economic Community<sup>5,7</sup>. There are two main classification systems for these oral lesions associated with HIV (HIV-OL). The first is based on the HIV-OL etiology: lesions are classified as bacterial, viral, fungal, neoplastic, or other. In 1993, the EC-Clearinghouse on Oral Problems Related to HIV Infection and the WHO Collaborating Centre on Oral Manifestations of the Immunodeficiency Virus reached con-

#### Antoine Berberi

Department of Oral and Maxillofacial Surgery, School of Dentistry, Lebanese University, Campus Rafic Hariri, Hadath 5208-116, Lebanon

TEL: +961-3-731173 FAX: +961-4-533060

E-mail: anberberi@gmail.com

ORCID: <http://orcid.org/0000-0002-7658-1361>

© This is an open-access article distributed under the terms of the Creative Commons Attribution Non-Commercial License (<http://creativecommons.org/licenses/by-nc/4.0/>), which permits unrestricted non-commercial use, distribution, and reproduction in any medium, provided the original work is properly cited.

Copyright © 2017 The Korean Association of Oral and Maxillofacial Surgeons. All rights reserved.

sensus on a new classification system for the oral manifestations of HIV infection. This system classifies HIV-OLs into three groups: lesions strongly associated with HIV infection, lesions less commonly associated with HIV infection, and lesions seen in HIV infection<sup>6</sup>. Oral lesions may be associated with acute pain, incompetence to swallow, and difficulty in eating. They may also compromise facial appearance. In immune-compromised patients, *Candida* species can generate a variety of oral lesions ranging from localized to disseminated candidiasis<sup>8,9</sup>. Oral candidiasis is the most frequent feature of AIDS in the mouth, with a prevalence of 70% to 90%<sup>8-10</sup>. Hairy leukoplakia, non-Hodgkin's lymphoma, and Kaposi's sarcoma have a wide association with HIV infection and are labeled as AIDS-defining conditions<sup>11-13</sup>. In some cases, enlargement of the parotid glands and adenopathy can be observed during head and neck examination of HIV-infected patients<sup>13-15</sup>.

Aside from their diagnostic importance, oral lesions may be of prognostic importance for the development of AIDS. They can serve as clinical correlates with CD4+ and CD8+ cell counts<sup>16-18</sup>. CD4+ T-cells are the main target of HIV; their diminution severely limits a patient's immune capacity<sup>19</sup>. When the CD4+ lymphocyte count decreases to a point where new CD4+ cell production is insufficient, the immune system yields to the clinical manifestation of AIDS<sup>4,20,21</sup>. While measuring CD4+ and CD8+ cell counts requires a laboratory blood analysis, the identification of oral lesions can be done during physical examination.

The aim of this study was to evaluate the oral lesions of 75 HIV/AIDS patients, in order to assess their correlation with CD4+ cell counts (including the CD4+/CD8+ cell ratio).

## II. Materials and Methods

A total of 75 patients with HIV/AIDS were assessed in a descriptive, cross-sectional study spanning two years. Relationships between oral lesions, CD4+ and CD8+ cell counts, and the CD4+/CD8+ cell ratio were investigated. All procedures performed in studies involving human participants were in accordance with the ethical standards of the institutional and/or national research committee and with the 1964 Helsinki declaration and its later amendments or comparable ethical standards. Ethical Committee of Saint-Antoine Hospital was obtained (no. 94REIM0201), and informed consent was obtained from all individual participants included in the study.

Patient records from the Odontology Unit of Saint-Antoine

Hospital were initially checked, and selected patients were asked to visit the unit for further examination. Each patient's medical history was noted, and a physical examination of the head and neck area and oral cavity was performed. The medical record, physical examination, demographic data, and laboratory tests were then assessed. Based on the findings of the physical inspection and laboratory tests, patients were prescribed essential medication, and follow-up visits were considered.

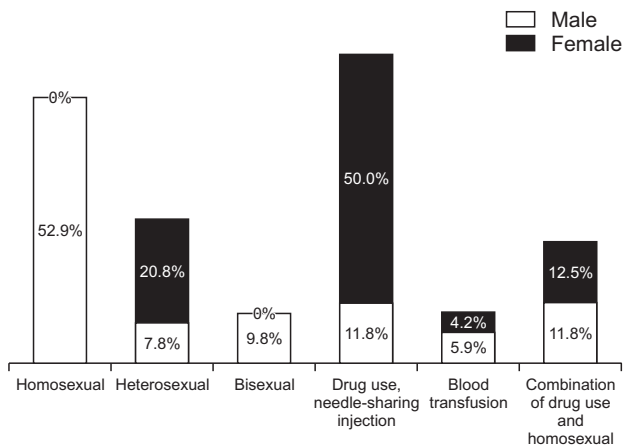
One qualified practitioner carried out all oral examinations. Extra-oral and intra-oral areas were examined first, followed by intra-oral tissues removed for pathology. Biopsies were taken for histological diagnosis only when needed. The assessment of oral lesions was implemented using the EC-Clearinghouse guidelines established in conjunction with the World Health Organization in 1993<sup>6</sup>. When multiple lesions were observed in the same patient, each lesion was considered independently for analysis.

*Candida* colonization was identified by isolation of *Candida* species from the oral cavity. A single oral swab was collected from each study participant. Swabs were cultured on Sabouraud's dextrose agar with chloramphenicol (0.5 g/L). Plates were incubated at 37°C in aerobic conditions and observed daily for one week.

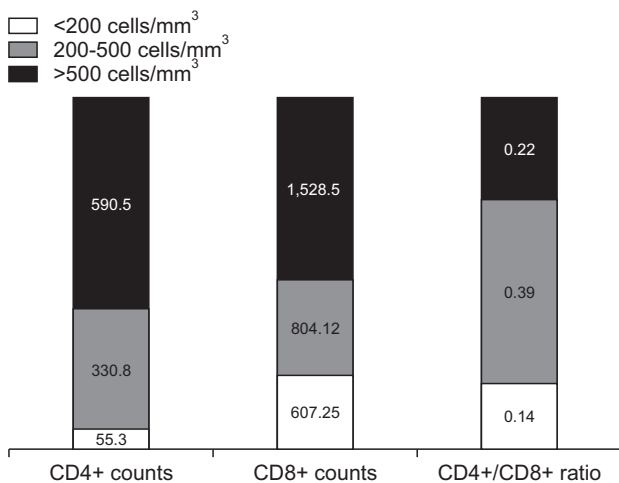
CD4+ and CD8+ cell counts were also analyzed. Based on the World Health Organization classification system for immunodeficiency<sup>3</sup>, patients with CD4+ cell counts >500 cells/mm<sup>3</sup> were classified as "marginally" immunodeficient; patients with CD4+ cell counts 200-500 cells/mm<sup>3</sup> were classified as "mildly" immunodeficient; and patients with CD4+ cell counts <200 cells/mm<sup>3</sup> were classified as "severely" immunodeficient. Collected data were analyzed using the SPSS ver. 16.0 (SPSS Inc., Chicago, IL, USA). Statistical variables included patient demographics (social demographics, age, and gender), types of oral lesions present, the amount of CD4+ cells, and the CD4+/CD8+ cell ratio.

## III. Results

Of the 75 patients, 51 patients (68.0%) were males and 24 patients (32.0%) were females. The median age in this study group was 38 years (range, 22-54 years). Of the patients, 44 patients had a history of sexual exposure to HIV, 18 patients had a history of sharing intravenous needles, 9 patients had a history of both sexual exposure and sharing intravenous needles, and 4 patients had a history of blood transfusion. (Fig. 1)



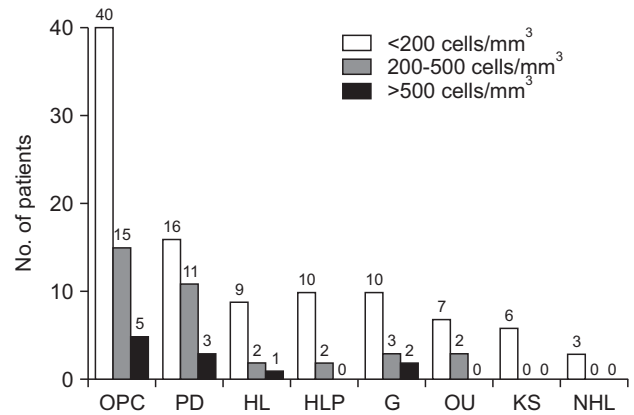
**Fig. 1.** Distribution by gender and way of contamination. Antoine Berberi et al: Oral lesions associated with human immunodeficiency virus in 75 adult patients: a clinical study. J Korean Assoc Oral Maxillofac Surg 2017



**Fig. 2.** Distribution of CD4+ cells, CD8+ cells, and the CD4+/CD8+ cell ratio. Antoine Berberi et al: Oral lesions associated with human immunodeficiency virus in 75 adult patients: a clinical study. J Korean Assoc Oral Maxillofac Surg 2017

The CD4+ count was <200 cells/mm<sup>3</sup> in 45 cases, 200-500 cells/mm<sup>3</sup> in 18 cases, and >500 cells/mm<sup>3</sup> in 12 cases. The mean CD4+ cell count was 158.75 cells/mm<sup>3</sup> in males and 144.50 cells/mm<sup>3</sup> in females.(Fig. 2) The median duration of antiretroviral therapy-mediated viral suppression was 3 years (range, 3 months to 4 years).

The distribution of oral lesions and the CD4+ cell counts of HIV-infected patients are shown in Fig. 3. All patients showed at least one oral manifestation. The most common oral lesion identified was oral pseudomembranous candidiasis (OPC, accounting for 80.0%), followed by periodontal disease (PD, 40.0%), herpetic lesions (HL, 16.0%), hairy leukoplakia (HLP, 16.0%), gingivitis (G, 20.0%), oral ulceration (OU, 12.0%), Kaposi's sarcoma (KS, 8.0%), and non-



**Fig. 3.** Distribution of oral lesions and CD4+ cell counts. (OPC: oral pseudomembranous candidiasis, PD: periodontal disease, HL: herpetic lesions, HLP: hairy leukoplakia, G: gingivitis, OU: oral ulceration, KS: Kaposi's sarcoma, NHL: non-Hodgkin's lymphoma) Antoine Berberi et al: Oral lesions associated with human immunodeficiency virus in 75 adult patients: a clinical study. J Korean Assoc Oral Maxillofac Surg 2017

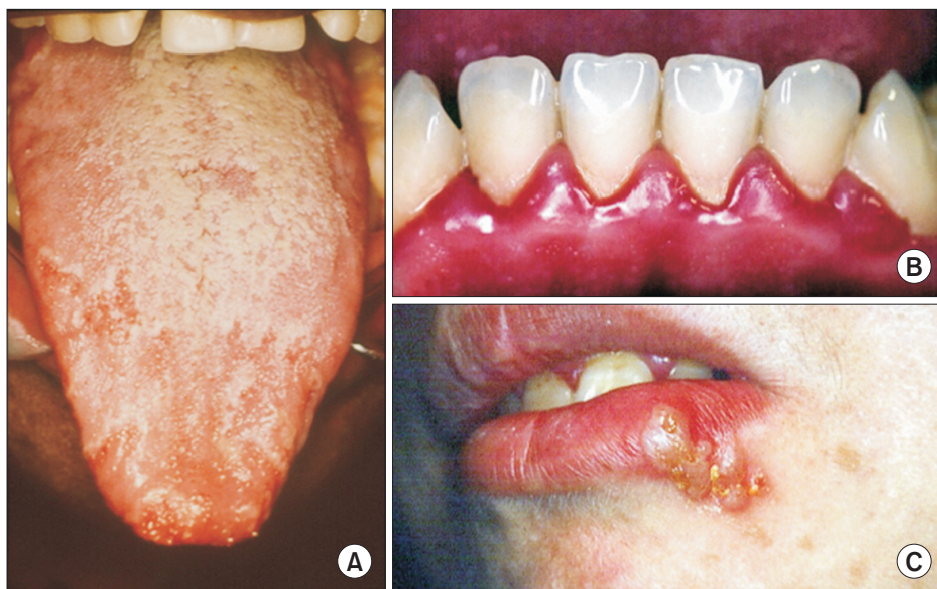Hodgkin's lymphoma (NHL, 4.0%).(Fig. 4-7)

Five different clinical presentations of OPC were observed on examination. Pseudomembranous (P) OPC was the most common clinical presentation (34/60 cases), followed by erythematous (E) OPC (7/60 cases), angular cheilitis (AC) (8/60 cases), a combination of AC and E (5/60 cases), and a combination of AC, E, and P (6/60 cases).(Fig. 8) *Candida albicans* was the most frequent species isolated (82% of cases), *Candida tropicalis* was isolated in 10% of cases, and *Candida glabrata* was isolated in 8% of cases.

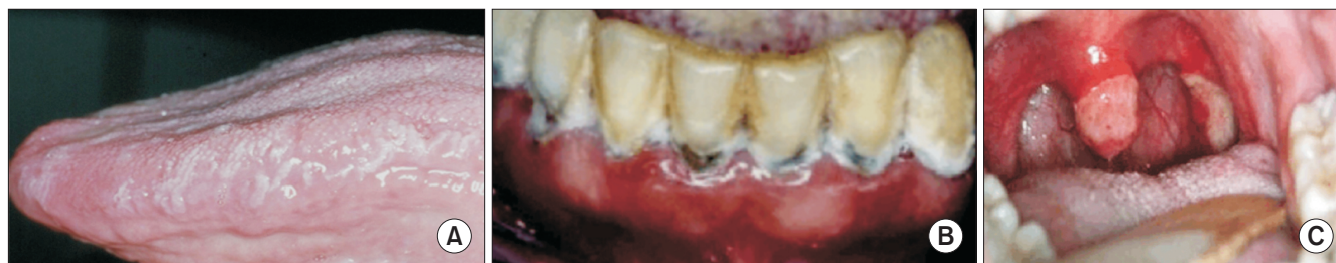#### IV. Discussion

Oral lesions are common findings in HIV-infected patients, and OPC is the most prevalent lesion type. The major reason for the development of oral lesions is the destruction of the immune system, and specifically the destruction of CD4+ lymphocytes<sup>18</sup>. CD8+ T-cells play a crucial role in controlling HIV replication during the early phase of infection. HIV-specific CD8+ T-cells are targeted toward the dominant viral variant, and their emergence is associated with a rapid fall in viral load before the development of an antibody response<sup>18</sup>.

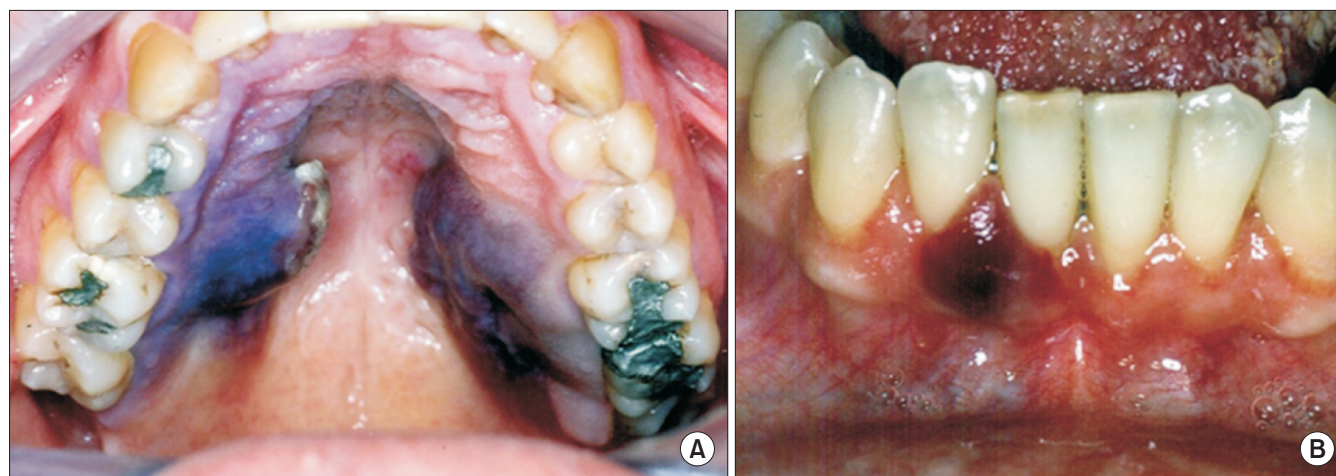
HIV infection is characterized by a progressive decrease in the absolute number of circulating CD4+ cells and in the CD4+/CD8+ cell ratio. In this study, no correlation was found between the CD4+/CD8+ cell ratio and oral lesions. But a strong correlation was found between the CD4+ cell count and oral lesions. The explanation for these findings could be related to the anti-viral treatments given to patients. In untreated HIV infection, CD8+ cell counts increase as CD4+



**Fig. 4.** Clinical appearance of oral lesions. A. Pseudomembranous candidiasis of the tongue. B. Swelling and redness of the gums as a clinical sign of periodontal disease. C. Herpetic lesion-type vesicles on the lower lip.  
*Antoine Berberi et al: Oral lesions associated with human immunodeficiency virus in 75 adult patients: a clinical study. J Korean Assoc Oral Maxillofac Surg 2017*



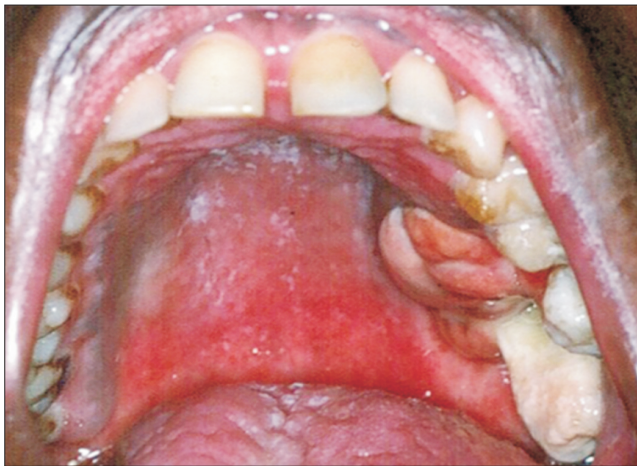**Fig. 5.** A. Hairy leukoplakia of the lateral border of the tongue. B. Ulcerous-necrotic material of the gums as a clinical sign of gingivitis. C. Ulcerations localized on the uvula and the lateral walls of the tonsils.  
*Antoine Berberi et al: Oral lesions associated with human immunodeficiency virus in 75 adult patients: a clinical study. J Korean Assoc Oral Maxillofac Surg 2017*



**Fig. 6.** A. Bilateral, dark purple tumor in the internal part of the palatal area, representing Kaposi's sarcoma. B. Localized tumefaction of the papillae, diagnosed as Kaposi's sarcoma.  
*Antoine Berberi et al: Oral lesions associated with human immunodeficiency virus in 75 adult patients: a clinical study. J Korean Assoc Oral Maxillofac Surg 2017*

cell counts decline<sup>22</sup>. During antiretroviral therapy, some individuals achieving CD4<sup>+</sup> cell counts above 500 cells/mm<sup>3</sup> experience a simultaneous decline in CD8<sup>+</sup> cell counts, lead-

ing to a normal CD4<sup>+</sup>/CD8<sup>+</sup> cell ratio. Among HIV-negative adults, inversion of the CD4<sup>+</sup>/CD8<sup>+</sup> cell ratio (below 1.0) predicts all-cause mortality and is considered part of the im-



**Fig. 7.** Tumefaction in a palatal position with maxillary tooth displacement, revealed by biopsy to be non-Hodgkin's lymphoma. Antoine Berberi et al: Oral lesions associated with human immunodeficiency virus in 75 adult patients: a clinical study. J Korean Assoc Oral Maxillofac Surg 2017

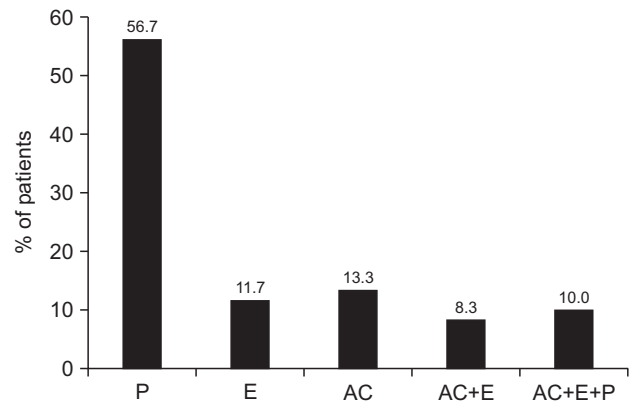
munogenicity phenotype<sup>23-27</sup>. In the setting of untreated HIV infection, the CD4+/CD8+ cell ratio predicts progression to AIDS<sup>24</sup>.

In this study, the average age of the patients was 38 years, and males were predominant (68% vs 32%). Thus, a high level of HIV/AIDS was found among youthful patients. Sexual contact was the main route of HIV transmission (58.7% of cases), followed by shared intravenous needles (24.0%) and blood transfusions (5.3%). Infection of females was primarily through shared intravenous needles, while males were more commonly infected through sexual contact.

The most common oral lesion identified was OPC (accounting for 80.0% of cases, 60/75), followed by PD (40.0%, 30/75), HL (16.0%, 12/75), HLP (16.0%, 12/75), G (20.0%, 15/75), OU (12.0%, 9/75), KS (8.0%, 6/75), and NHL (4.0%, 3/75). *Candida* species were isolated from the oral cavity in 76% of cases. Similar figures have been recorded by Thompson et al.<sup>28</sup>, Castro et al.<sup>29</sup>, and Lin et al.<sup>30</sup>.

In our study, 60.0% of the oral lesions were in patients with CD4+ cell counts <200 cells/mm<sup>3</sup>. This is consistent with previous studies, in which HIV patients with CD4+ cell counts <200 cells/mm<sup>3</sup> had more oral lesions<sup>16,18,21</sup>.

An inverse correlation between CD4+ cell counts and the presence of oral mucosal lesions in HIV-infected patients has been reported<sup>8,21,25,26</sup>. Similarly, the present study has found a significant inverse correlation between CD4+ cell counts and the prevalence of oral lesions in HIV-infected patients. The distribution of OPC lesions according to CD4+ cell counts (73% of lesions were in patients with CD4+ cell counts <200 cells/mm<sup>3</sup>) has been a common observation in other studies



**Fig. 8.** Distribution of oral pseudomembranous candidiasis types. (P: pseudomembranous, E: erythematous, AC: angular cheilitis) Antoine Berberi et al: Oral lesions associated with human immunodeficiency virus in 75 adult patients: a clinical study. J Korean Assoc Oral Maxillofac Surg 2017

as well<sup>19</sup>. This indicates that the occurrence of oral lesions in HIV patients could be helpful in determining immunological status. This finding also corresponds with reports that CD4+ cell reduction is strongly associated with a high viral load<sup>18</sup>. For these reasons, clinicians and physicians are regarding oral lesions as useful for the diagnosis and detection of infection progression<sup>18,26</sup>.

The main factor associated with the development of oral opportunistic lesions is the CD4+ cell count<sup>20</sup>. The onset of oral candidiasis and oral hairy leukoplakia is indicated by a sustained reduction in the CD4+ blood cell count together with a sharp increase in viral load<sup>10</sup>. Moniaci et al.<sup>8</sup> observed that oral lesions found among 737 persons infected with HIV in Italy were significantly associated with CD4+ cell counts <300 cells/mm<sup>3</sup>. In a study on 43 HIV-positive subjects in Greece, Kolokotronis et al.<sup>9</sup> reported that oral hairy leukoplakia was associated with CD4+ cell counts <200 cells/mm<sup>3</sup>. And Adurogbangba et al.<sup>27</sup>, by analyzing oral lesions and CD4+ cell counts in 81 HIV-positive and 31 HIV-negative subjects in Nigeria, found that CD4+ cell counts <500 cells/mm<sup>3</sup> were significantly associated with pseudomembranous candidiasis and angular cheilitis. Similarly, the present study has revealed that the presence of oral candidiasis and hairy leukoplakia are associated with CD4+ cell counts <200 cells/mm<sup>3</sup>.

The Centers for Disease Control and Prevention have proposed a revised classification system and AIDS case surveillance definition that incorporates both clinical signs and symptoms and one laboratory marker, the CD4+ cell count<sup>7</sup>. Thus far, the CD4+ cell count has been recognized and widely used as a marker for HIV-related disease progression. Conclusions from the present study indicate that the existence of

oral lesions in HIV patients could be useful to monitor immunological status. Results from the present study are consistent with previous reports that CD4+ cell depletion is strongly associated with a high viral load<sup>18</sup>. The development of oral lesions caused by opportunistic pathogens is significantly related to the CD4+ cell count<sup>18</sup>. The onset of certain oral lesions (such as those in candidiasis and oral hairy leukoplakia) is signaled by a sustained reduction in the CD4+ blood cell count, which is associated with a high viral load<sup>11</sup>.

## V. Conclusion

As the CD4+ cell count decreases, the appearance and severity of oral lesions increases. A diagnosis of oral lesions may point to a positive HIV/AIDS status. Progression of infection is associated with a high prevalence of certain oral lesions, including candidiasis, hairy leukoplakia, and Kaposi's sarcoma. The severity of lesions is more pronounced with a low CD4+ cell count. Management of lesions will improve quality of life for HIV/AIDS patients. An awareness of the connection between oral lesions and disease progression is recommended for clinicians treating HIV infection.

## Conflict of Interest

No potential conflict of interest relevant to this article was reported.

## ORCID

Antoine Berberi, <http://orcid.org/0000-0002-7658-1361>

Georges Aoun, <http://orcid.org/0000-0001-5073-6882>

## References

- Patton L. Progress in understanding oral health and HIV/AIDS. *Oral Dis* 2014;20:223-5.
- Piot P, Quinn TC. Response to the AIDS pandemic--a global health model. *N Engl J Med* 2013;368:2210-8.
- UNAIDS. Global AIDS Response Progress Reporting 2016 [Internet]. Geneva: UNAIDS; January 2016 [cited 2017 Jul 21]. Available from: [https://aidsreportingtool.unaids.org/static/docs/GARPR\\_Guidelines\\_2016\\_EN.pdf](https://aidsreportingtool.unaids.org/static/docs/GARPR_Guidelines_2016_EN.pdf).
- Nesti M, Carli E, Giaquinto C, Rampon O, Nastasio S, Giuca MR. Correlation between viral load, plasma levels of CD4-CD8 T lymphocytes and AIDS-related oral diseases: a multicentre study on 30 HIV+ children in the HAART era. *J Biol Regul Homeost Agents* 2012;26:527-37.
- Patton LL, Ramirez-Amador V, Anaya-Saavedra G, Nittayananta W, Carrozzo M, Ranganathan K. Urban legends series: oral manifestations of HIV infection. *Oral Dis* 2013;19:533-50.
- Classification and diagnostic criteria for oral lesions in HIV infection. EC-Clearinghouse on Oral Problems Related to HIV Infection and WHO Collaborating Centre on Oral Manifestations of the Immunodeficiency Virus. *J Oral Pathol Med* 1993;22:289-91.
- Petersen PE. Policy for prevention of oral manifestations in HIV/AIDS: the approach of the WHO Global Oral Health Program. *Adv Dent Res* 2006;19:17-20.
- Moniaci D, Greco D, Flecchia G, Raiteri R, Sinicco A. Epidemiology, clinical features and prognostic value of HIV-1 related oral lesions. *J Oral Pathol Med* 1990;19:477-81.
- Kolokotronis A, Kioses V, Antoniadis D, Mandraveli K, Doutsos I, Papanayotou P. Immunologic status in patients infected with HIV with oral candidiasis and hairy leukoplakia. *Oral Surg Oral Med Oral Pathol* 1994;78:41-6.
- Berberi A, Noujeim Z, Aoun G. Epidemiology of oropharyngeal candidiasis in human immunodeficiency virus/acquired immune deficiency syndrome patients and CD4+ counts. *J Int Oral Health* 2015;7:20-3.
- Ramírez-Amador V, Esquivel-Pedraza L, Sierra-Madero J, Anaya-Saavedra G, González-Ramírez I, Ponce-de-León S. The changing clinical spectrum of human immunodeficiency virus (HIV)-related oral lesions in 1,000 consecutive patients: a 12-year study in a referral center in Mexico. *Medicine (Baltimore)* 2003;82:39-50.
- Berberi A, Noujeim Z. Epidemiology and relationships between CD4+ counts and oral lesions among 50 patients infected with human immunodeficiency virus. *J Int Oral Health* 2015;7:18-21.
- Park YJ, Nam JH, Noh KL, Pang EO, Kim DY, Kim JH, et al. Aids-associated kaposi's sarcoma on left lower retromolar triangle and parapharyngeal area: a case report. *J Korean Oral Maxillofac Surg* 2009;35:182-6.
- Vigneswaran N, Williams MD. Epidemiologic trends in head and neck cancer and aids in diagnosis. *Oral Maxillofac Surg Clin North Am* 2014;26:123-41.
- Bunn BK, van Heerden WF. HIV/AIDS associated malignancies of the head and neck. *SADJ* 2012;67:590-2.
- Pakfetrat A, Falaki F, Delavarian Z, Dalirsani Z, Sanatkhan M, Zabihi Marani M. Oral manifestations of human immunodeficiency virus-infected patients. *Iran J Otorhinolaryngol* 2015;27:43-54.
- Bravo IM, Correnti M, Escalona L, Perrone M, Brito A, Tovar V, et al. Prevalence of oral lesions in HIV patients related to CD4 cell count and viral load in a Venezuelan population. *Med Oral Patol Oral Cir Bucal* 2006;11:E33-9.
- Bodhade AS, Ganvir SM, Hazarey VK. Oral manifestations of HIV infection and their correlation with CD4 count. *J Oral Sci* 2011;53:203-11.
- Fanales-Belasio E, Raimondo M, Suligoi B, Buttò S. HIV virology and pathogenetic mechanisms of infection: a brief overview. *Ann Ist Super Sanita* 2010;46:5-14.
- Onakewhor JU, Olagbuji BN, Ande AB, Ezeanochie MC, Olorok OE, Okonofua FE. HIV-AIDS related maternal mortality in Benin City, Nigeria. *Ghana Med J* 2011;45:54-9.
- Taiwo OO, Hassan Z. The impact of Highly Active Antiretroviral Therapy (HAART) on the clinical features of HIV-related oral lesions in Nigeria. *AIDS Res Ther* 2010;7:19.
- Zhou H, Zhao H, Hao Y, Song C, Han J, Zhang J, et al. Excessive conversion and impaired thymic output contribute to disturbed regulatory T-cell homeostasis in AIDS patients with low CD4 cell counts. *AIDS* 2013;27:1059-69.
- Serrano-Villar S, Sainz T, Lee SA, Hunt PW, Sinclair E, Shacklett BL, et al. HIV-infected individuals with low CD4/CD8 ratio despite effective antiretroviral therapy exhibit altered T cell subsets, heightened CD8+ T cell activation, and increased risk of non-AIDS morbidity and mortality. *PLoS Pathog* 2014;10:e1004078.
- Margolick JB, Gange SJ, Detels R, O'Gorman MR, Rinaldo CR Jr, Lai S. Impact of inversion of the CD4/CD8 ratio on the natural history of HIV-1 infection. *J Acquir Immune Defic Syndr* 2006;42:620-6.

25. Mocroft A, Bannister WP, Kirk O, Kowalska JD, Reiss P, D'Arminio-Monforte A, et al. The clinical benefits of antiretroviral therapy in severely immunocompromised HIV-1-infected patients with and without complete viral suppression. *Antivir Ther* 2012;17:1291-300.
26. Frimpong P, Amponsah EK, Abebrese J, Kim SM. Oral manifestations and their correlation to baseline CD4 count of HIV/AIDS patients in Ghana. *J Korean Assoc Oral Maxillofac Surg* 2017;43:29-36.
27. Adurogbangba MI, Aderinokun GA, Odaibo GN, Olaleye OD, Lawoyin TO. Oro-facial lesions and CD4 counts associated with HIV/AIDS in an adult population in Oyo State, Nigeria. *Oral Dis* 2004;10:319-26.
28. Thompson GR 3rd, Patel PK, Kirkpatrick WR, Westbrook SD, Berg D, Erlandsen J, et al. Oropharyngeal candidiasis in the era of antiretroviral therapy. *Oral Surg Oral Med Oral Pathol Oral Radiol Endod* 2010;109:488-95.
29. Castro LÁ, Álvarez MI, Martínez E. Pseudomembranous candidiasis in HIV/AIDS patients in Cali, Colombia. *Mycopathologia* 2013;175:91-8.
30. Lin JN, Lin CC, Lai CH, Yang YL, Chen HT, Weng HC, et al. Predisposing factors for oropharyngeal colonization of yeasts in human immunodeficiency virus-infected patients: a prospective cross-sectional study. *J Microbiol Immunol Infect* 2013;46:129-35.