



Comparative evaluation of the efficacy of wound healing with and without dehydrated human amniotic/chorionic membrane in alveoloplasty: a pilot study

Monica Gajul, Kalyani Bhate, Sayali Awate, Pradnya Kakodkar, Sonal Shah

Department of Oral & Maxillofacial Surgery, Dr. D. Y. Patil Vidyapeeth, Pune, India

Abstract (J Korean Assoc Oral Maxillofac Surg 2021;47:279-285)

Objectives: Wound healing is an integral part of any surgical procedure. Appropriate wound closure is critical to any successful surgical procedure, especially intraoral procedures. Various factors aid in wound healing, both pharmacological and non-pharmacological. Dehydrated human amniotic/chorionic membrane (dHACM) is an emerging bioinert material that contains anti-inflammatory properties, angiogenetic properties, osteogenic potential, and various growth factors. The purpose of this study was to evaluate the efficacy of wound healing properties of dHACM in bilateral alveoloplasty patients.

Materials and Methods: A prospective split-mouth study was conducted on 10 patients. Site A received sutures with dHACM and site B was sutured without dHACM. Wound healing was assessed with the Landry, Turnbull, and Howley Index.

Results: Sites A and site B were compared. A $P < 0.05$ and a test value of 22 was obtained, indicating a statistical difference between the two sites.

Conclusion: Our study showed better healing with dHACM than without.

Key words: Biological dressings, Amnion, Wound Healing, Alveoloplasty

[paper submitted 2021. 2. 18 / revised 2021. 4. 24 / accepted 2021. 5. 10]

I. Introduction

Wound healing is an integral part of oral surgery, and it plays an important role in patient prognosis. After any surgical procedure in the oral cavity, it takes a minimum of one to one-and-a-half months for the wound to heal completely¹.

Appropriate wound closure is of great importance in any surgical procedure, especially intraoral procedures^{2,3}. Healing can occur in two ways: primary intention healing and secondary intention healing. Healing that occurs without scar tissue formation is termed primary intention and healing that occurs with granulation tissue formation is termed secondary intention^{1,2}.

Primary healing occurs in clean and neat wounds with no infection, while wounds with uneven edges and infections generally heal through secondary intention¹. Factors such as bleeding, vascularity, granulation tissue formation, suppuration, tissue discoloration, and pain are determining factors of wound healing⁴.

Various factors aid in wound healing and numerous materials and techniques are continuously proposed to aid in wound healing, which can be classified into pharmacological agents and non-pharmacological agents. The pharmacological agents include various drugs that aid in healing like anti-inflammatory drugs, immune-suppressants, and antimicrobial drugs.

Bioinert materials and membranes include plasma rich fibrin (PRF), plasma rich platelets (PRP), bone grafts, skin grafts, collagen membrane, and hydrocolloid materials^{2,3}. The disadvantage of these materials is that they require a separate surgical site or a donor site. The patient must undergo secondary procedures for graft procurement. Collagen membrane has challenging handling properties. PRF and PRP require a blood draw from patients. Thus, there is a need for materials that have easy handling properties, are inexpensive,

Monica Gajul

Department of Oral & Maxillofacial Surgery, Dr. D. Y. Patil Vidyapeeth,
Sant Tukaram Nagar, Pimpri, Pune 411018, India
TEL: +91-20-67116419

E-mail: monicagajul@gmail.com

ORCID: <https://orcid.org/0000-0001-5087-5786>

© This is an open-access article distributed under the terms of the Creative Commons Attribution Non-Commercial License (<http://creativecommons.org/licenses/by-nc/4.0/>), which permits unrestricted non-commercial use, distribution, and reproduction in any medium, provided the original work is properly cited.

Copyright © 2021 The Korean Association of Oral and Maxillofacial Surgeons.

and can be made easily available to patients. One such material is amniotic membrane.

The amniotic membrane is the innermost layer of the placenta, consisting of a thick basement membrane and an avascular stromal matrix^{1,4}. It can be used as a graft and as a dressing to facilitate reconstruction and to promote healing⁴. It is an emerging novel method that aids in wound healing^{4,5}. It is widely used for better healing in diabetic foot, as a burn dressing, and for orbital surgery. The amniotic membrane is an excellent graft material that helps heal soft and hard tissue.

Certain surgical procedures are only carried out in the oral cavity. Alveoloplasty is often performed prior to receiving a denture or to bring pain relief. The main procedural objective of alveoloplasty is to round out sharp bony edges and remove any bony spicules or undercuts present after an extraction^{5,6}. The amniotic membrane has been used in the oral cavity for

pre-cancerous lesions and procedures like vestibuloplasty and is also commonly used with alveoloplasty. However, a thorough search of the English-language medical literature revealed no evaluations of amniotic membrane for wound healing after alveoloplasty. This pilot study aims to assess amniotic membrane efficacy for wound healing after alveoloplasty.

II. Materials and Methods

This prospective split-mouth pilot study was conducted in the Department of Oral & Maxillofacial Surgery, Dr. D. Y. Patil Vidyapeeth after an ethical clearance was granted by the Institutional Review Board (No. DPU/1185/19). Using a convenience sampling technique with random allocation, 10 patients with bilaterally edentulous jaws who reported to our center and required bilateral alveoloplasty procedure were selected.

Sample size: $n=20$ alveoloplasty sites; $n=[(Z_{1-\alpha}-Z\beta)]^2/3$

Site A: $n=10$ (with dehydrated human amniotic/chorionic membrane [dHACM])

Site B: $n=10$ (without dHACM)

Patients who fit the following inclusion criteria were chosen for the study: (i) indicated for alveoloplasty in the upper and lower jaw bilaterally; (ii) >45 years or older; and (iii) willing to participate. The exclusion criteria were: (i) history of tobacco chewing, smoking, or alcohol consumption and (ii) any of the following medical conditions—coagulation disorders, metabolic bone disorders, drug consumption leading to gingival hyperplasia, pregnancy, history of radiotherapy, chemotherapy, or having recently undergone any operative procedures.

A detailed history was taken of all enrolled participants. All participants were well-informed of the study goals and procedures and everyone was given a printed informed consent form. All necessary preoperative radiographs that is—

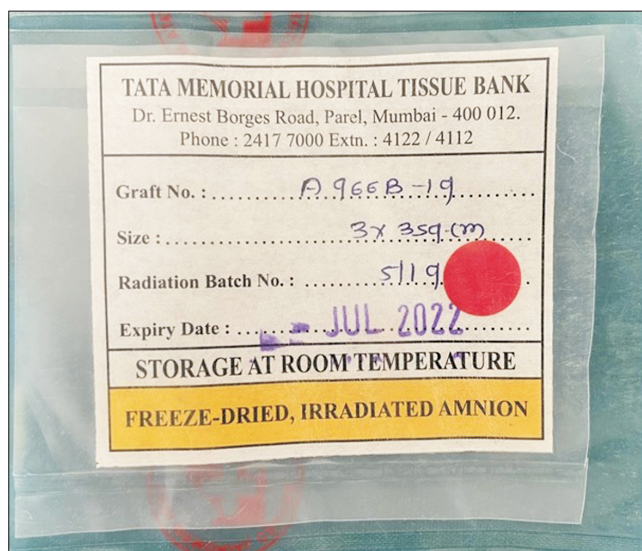


Fig. 1. Dehydrated human amniotic/chorionic membrane obtained from human placental extract.

Monica Gajul et al: Comparative evaluation of the efficacy of wound healing with and without dehydrated human amniotic/chorionic membrane in alveoloplasty: a pilot study. J Korean Assoc Oral Maxillofac Surg 2021

Table 1. Landry, Turnbull, and Howley Index for checking the healing of soft tissues

Healing index	Tissue color	Bleeding palpation	Granulation tissue	Incision margins	Suppuration
1 (very poor: Two or more signs are present.)	>50% of red gingiva	Yes	Yes	Not epithelialized, with loss of epithelium beyond incision margin.	Yes
2 (poor)	>50% of red gingiva	Yes	Yes	Not epithelialized, with exposed connective tissue.	No
3 (good)	25%-50% of red gingiva	No	No	No exposed connective tissue.	No
4 (very good)	>25% of red gingiva	No	No	No exposed connective tissue.	No
5 (excellent)	All pink tissues	No	No	No exposed connective tissue.	No

Monica Gajul et al: Comparative evaluation of the efficacy of wound healing with and without dehydrated human amniotic/chorionic membrane in alveoloplasty: a pilot study. J Korean Assoc Oral Maxillofac Surg 2021

Orthopantomogram has been taken. Preoperative workups, such as a complete blood profile, were performed for all patients. Site selection and dHACM placement side (TATA Tissue Bank, Mumbai, India; Fig. 1) were determined using the Sequentially Numbered Opaque Sealed Envelopes (SNOSE) technique.

One operator carried out all alveoloplasty surgical procedures and another investigator recorded the healing index at seven days and 21 days postoperatively using the Landry, Turnbull, and Howley Index.(Table 1)

Patients were taken for surgery and routine painting and draping were performed. Local anesthetic injection of 2% lignocaine hydrochloride with 1:200,000 adrenaline was administered at the alveoloplasty region. A crestal incision was made and a full-thickness mucoperiosteal flap was raised using a Molts Periosteal Elevator (No. 9; iM3, St., Vancouver, WA, USA). Any irregular bone was levelled and smoothed with a bone rongeur and bone file.(Fig. 2) For all 10 patients,

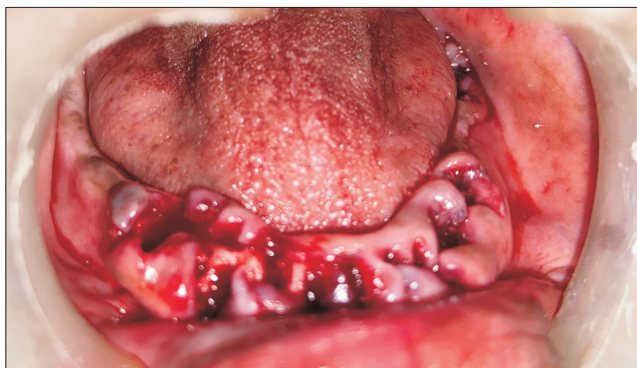

Fig. 2. Alveoloplasty procedure done on lower jaw.
Monica Gajul et al: Comparative evaluation of the efficacy of wound healing with and without dehydrated human amniotic/chorionic membrane in alveoloplasty: a pilot study. J Korean Assoc Oral Maxillofac Surg 2021

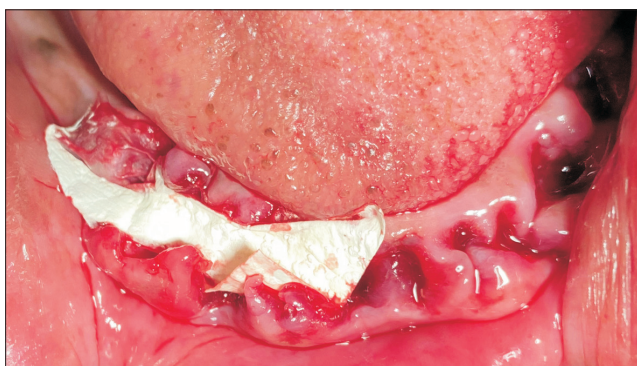


Fig. 3. Dehydrated human amniotic/chorionic placed after alveoloplasty procedure.
Monica Gajul et al: Comparative evaluation of the efficacy of wound healing with and without dehydrated human amniotic/chorionic membrane in alveoloplasty: a pilot study. J Korean Assoc Oral Maxillofac Surg 2021

the amniotic membrane was placed at site A and was not placed in site B.(Fig. 3) Wound closure was done with 3-0 silk sutures.(Fig. 4) Gauze was placed after surgery. The same procedure was repeated at site B. Postoperative instructions were given to the patient. Analgesics (Paracip 500 mg; Cipla GX, Mumbai, India) were prescribed. The patient was called the next day for follow-up and again on the seventh and 21st days. Healing was measured using the Landry, Turnbull, and Howley Index. The analysis was performed using IBM SPSS Statistics software (ver. 22.0; IBM, Armonk, NY, USA). A $P < 0.05$ was considered statistically significant.

III. Results

This experimental split-mouth study was conducted from 2019 to 2020 to assess the efficacy of dHACM for accelerating the wound healing process. Most patients were between

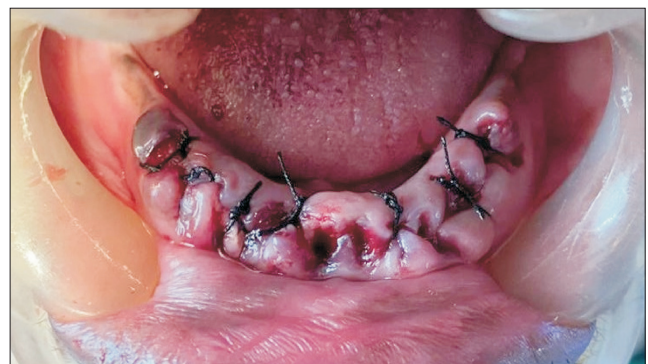

Fig. 4. Closure done with 3-0 silk after placement of dehydrated human amniotic/chprionic procedure.
Monica Gajul et al: Comparative evaluation of the efficacy of wound healing with and without dehydrated human amniotic/chorionic membrane in alveoloplasty: a pilot study. J Korean Assoc Oral Maxillofac Surg 2021

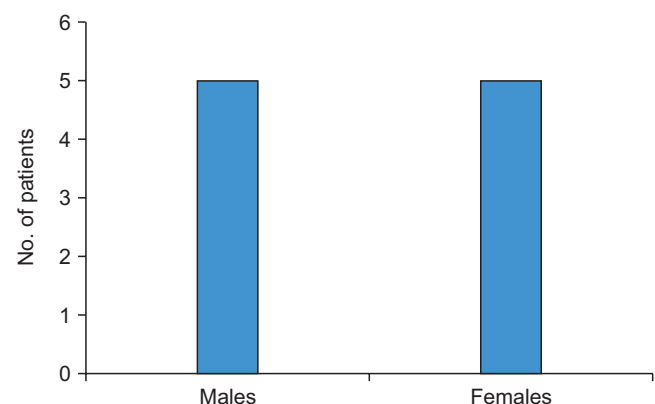


Fig. 5. Demographic chart of patients.
Monica Gajul et al: Comparative evaluation of the efficacy of wound healing with and without dehydrated human amniotic/chorionic membrane in alveoloplasty: a pilot study. J Korean Assoc Oral Maxillofac Surg 2021

45-55 years with a mean age of 50.5±10.50 years. Of 10 patients, 5 were male and 5 were female.(Fig. 5)

Wound healing was compared between the two sites using the Landry, Turnbull, and Howley Index. A score of 5 indicated excellent tissue healing while a score of 1 indicated very poor healing. Among site A (dHACM) cases, scores ranged from 2 to 5, while site B (no dHACM) cases ranged from 1 to 5. Though the individual parameters that make up the index were not significantly different between the two site groups,

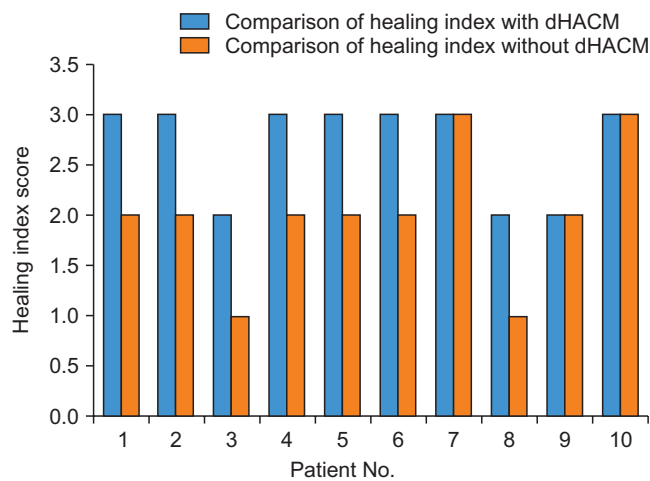


Fig. 6. Comparison of healing index. Mann-Whitney U test value=22, $P<0.05$. There is a significant difference between the two groups. (dHACM: dehydrated human amniotic/chorionic membrane)

Monica Gajul et al: Comparative evaluation of the efficacy of wound healing with and without dehydrated human amniotic/chorionic membrane in alveoloplasty: a pilot study. J Korean Assoc Oral Maxillofac Surg 2021

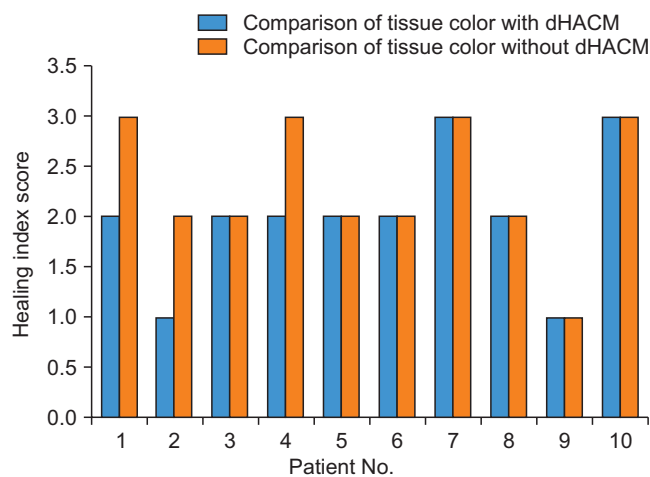


Fig. 7. Comparison of tissue color. Mann-Whitney U test value=38, $P>0.05$. There is no statistically significant difference between the two groups. (dHACM: dehydrated human amniotic/chorionic membrane)

Monica Gajul et al: Comparative evaluation of the efficacy of wound healing with and without dehydrated human amniotic/chorionic membrane in alveoloplasty: a pilot study. J Korean Assoc Oral Maxillofac Surg 2021

the total count, i.e., the healing index, was different.(Fig. 6) Tissue color comparisons did not reveal significant differences between the two groups (Fig. 7; $P>0.05$. The inter-group comparison of the healing index, which consists of tissue color, bleeding on palpation, granulation tissue, suppuration, and overall healing, was significantly different ($P<0.05$, Mann-Whitney U test value=22; Fig. 8).

IV. Discussion

Denture prosthetics are important for restoring quality of life to edentulous patients. Loss of teeth leads to loss of facial contour, low self-esteem, and, ultimately, compromised aesthetics⁵. A primary requisite for receiving good dentures is a smooth alveolar ridge. Traumatic extraction and poor healing of extraction sockets often lead to bony spicules on the alveolar ridge, which makes denture prosthesis difficult and even painful⁶.

Furthermore, appropriate wound closure after any intraoral surgical procedure is always of great concern⁷. After alveoloplasty, good healing is important for successful receipt of the fabricated denture. In 2016, Politis et al.¹ conducted a study on wound healing in the oral cavity, in which they defined the mouth as an enigmatic structure in which wound healing occurs amidst millions of bacteria. Healing of hard tissue requires approximately six months¹. Various materials and grafts can be used as adjuncts or catalysts for wound healing,

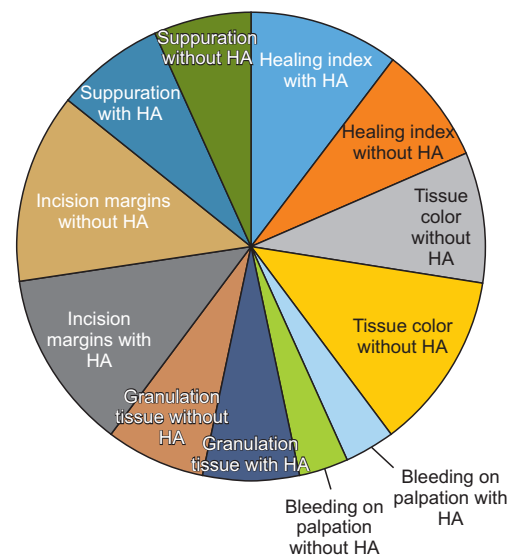


Fig. 8. Overall comparison of healing index of soft tissues. (HA: dehydrated human amniotic/chorionic membrane).

Monica Gajul et al: Comparative evaluation of the efficacy of wound healing with and without dehydrated human amniotic/chorionic membrane in alveoloplasty: a pilot study. J Korean Assoc Oral Maxillofac Surg 2021

particularly PRF, PRP, skin grafts, and dHACM⁸.

The amnion is the deepest layer of the human placenta⁸⁻¹⁹, and it has distinctive properties. It is made up of three lamina: an overlying tissue, a basement sheath, and a stromal layer beneath^{13,14}. It possesses the unique property of low immunogenicity, which makes it an excellent grafting material. It behaves as a barrier and does not allow for fibrous tissue proliferation^{12,15}. The amnion also possesses antiangiogenic and anti-inflammatory substances, including interleukin (IL)-1 receptor antagonist, tissue inhibitors of metalloproteinase-1, -2, -3, and -4, and IL-10.31 and -32¹⁵⁻¹⁷.

Because of these characteristics, dHACM is thought to foster new blood vessel growth, encourage tissue proliferation, and recruit mesenchymal progenitor cells that ultimately aid in better wound healing¹⁷. Its ease of use and obtainment has led to widespread use in many medical areas^{17,18}.

According to Zhou et al.²⁰, the amniotic membrane also possesses osteoblastic properties that encourage new bone formation. Similar effects were observed in our previous study when dHACM was used as a graft material for soft tissue healing, and it also contributed to uneventful healing of the alveolar bone underneath²¹⁻²³. In this study, a comparison of wound healing efficacy with and without dHACM was performed in alveoloplasty patients. The parameters assessed were the healing index, tissue color, bleeding on palpation, granulation tissue, and suppuration¹⁸.

This study compared bilateral sites in the same patients. This approach offers the unique advantage of reducing variables like immune response, healing capacity, and inflammatory reaction. Because both sites are in the same patient, all these factors are controlled for.

Doig and Simpson²⁴ carried out an experiment that randomized patients into various groups according to medications and discussed the various randomization strategies to conceal randomization arrangements. They found that the SNOSE strategy was both powerful and affordable. This technique was used in this study to reduce bias²¹.

There are many parameters to assess wound healing, but the Landry, Turnbull, and Howley Index is easy and convenient to score⁴. It has a scoring range from 1 to 5, the lowest being 1 and the highest being 5. The parameters measured in this index are the healing index, tissue color, bleeding on palpation, granulation tissue, and suppuration, and this index was selected to compare wound healing in alveoloplasty patients with and without dHACM⁴.

Although no significant variations were found in any of the Landry, Turnbull, and Howley Index parameters, the

mean overall healing index score was higher in sites where amniotic membrane was used. In seven patients, the healing index was higher on the amniotic membrane side than the non-membrane side; the other three patients showed similar healing in both sites. This can be attributed to the low level immune response of the amniotic membrane^{15-17,19}. According to a 2020 study by Puyana et al.²¹, amniotic tissue cells expressed microbial peptides like IL-10, tumor necrosis factor (TNF)- α , and interferons, which are known to inhibit inflammation. In this study, a similar effect was seen because dHACM is anti-inflammatory by nature. The results were significantly different between the sites, so it can be concluded that dHACM is better than suturing alone.

The other parameter assessed was tissue color. According to a 2014 study by Tsuno et al.¹⁶, the amniotic membrane enhances formation of new blood vessels. Identical effects were found in our study, which yielded similar results following new angiogenesis, resulting in improved tissue color. Although tissue color was not significantly different between the two site groups, six out of 10 patients showed better tissue color on their dHACM-treated side than their suture-alone side.

dHACM is a promising material for wound healing. Many studies have concluded that it has multiple effective uses in many medical areas. The advantages of dHACM include its easy handling properties, convenient procurement process, cost efficiency, no requirement of a separate surgical site, and no fear of immuno-histocompatibility rejection^{11,12,15,16,18}. No studies have reported any adverse reactions caused by dHACM.

This is a pilot study with a small sample size. A multi-center study with a larger sample size is needed to corroborate our study results.

This study was conducted in older patients, where healing is delayed compared with younger patients. The study shows that amniotic membrane enhances healing in this population.

V. Conclusion

In our study, we assessed wound healing with and without dHACM in alveoloplasty patients. Our findings suggest that dHACM aids in wound healing due to its low immunogenicity, anti-inflammatory, and angiogenetic properties. Hence, we recommend the use of dHACM as a wound-healing graft material for alveoloplasty without fear of adverse events.

ORCID

Monica Gajul, <https://orcid.org/0000-0001-5087-5786>
Kalyani Bhate, <https://orcid.org/0000-0002-6654-6060>
Sayali Awate, <https://orcid.org/0000-0002-3809-0836>
Pradnya Kakodkar, <https://orcid.org/0000-0002-1540-8100>
Sonal Shah, <https://orcid.org/0000-0001-8424-0105>

Authors' Contributions

M.G. participated in data collection and wrote the manuscript. K.B. and P.K. participated in the study design and performed statistical analyses. S.S., S.A., and M.G. participated in the study design and coordination and helped draft the manuscript. All authors read and approved the final manuscript.

Acknowledgements

The authors acknowledge the support of the Department of Oral and Maxillofacial Surgery.

Ethics Approval and Consent to Participate

The study was approved by the Institutional Review Board (No. DPU/1185/19) of Dr. D. Y. Patil Vidyapeeth. Informed consent was obtained from all patients.

Conflict of Interest

No potential conflict of interest relevant to this article was reported.

References

1. Politis C, Schoenaers J, Jacobs R, Agbaje JO. Wound healing problems in the mouth. *Front Physiol* 2016;7:507. <https://doi.org/10.3389/fphys.2016.00507>
2. Tenenhaus M. The use of dehydrated human amnion/chorion membranes in the treatment of burns and complex wounds: current and future applications. *Ann Plast Surg* 2017;78(2 Suppl 1):S11-3. <https://doi.org/10.1097/SAP.0000000000000983>
3. Tettelbach W, Cazzell S, Reyzelman AM, Sigal F, Caporusso JM, Agnew PS. A confirmatory study on the efficacy of dehydrated human amnion/chorion membrane dHACM allograft in the management of diabetic foot ulcers: a prospective, multicentre, randomised, controlled study of 110 patients from 14 wound clinics. *Int Wound J* 2019;16:19-29. <https://doi.org/10.1111/iwj.12976>
4. Gangwani KD, Shetty L, Kulkarni D, Seshagiri R, Chopra R. Piezosurgery versus conventional method alveoplasty. *Ann Maxillofac Surg* 2018;8:181-7. https://doi.org/10.4103/ams_ams_162_18
5. Nandhana S, Kathiravan. Incidence of alveoplasty post extraction – a retrospective study. *J Pharm Sci Res* 2017;9:441-3.
6. Van der Weijden F, Dell'Acqua F, Slot DE. Alveolar bone dimensional changes of post-extraction sockets in humans: a systematic review. *J Clin Periodontol* 2009;36:1048-58. <https://doi.org/10.1111/j.1600-051X.2009.01482.x>
7. Suthar P, Shah S, Wanknis P, Limaye G, Saha A, Sathe P. Comparing intra-oral wound healing after alveoplasty using silk sutures and n-butyl-2-cyanoacrylate. *J Korean Assoc Oral Maxillofac Surg* 2020;46:28-35. <https://doi.org/10.5125/jkaoms.2020.46.1.28>
8. Arai N, Tsuno H, Okabe M, Yoshida T, Koike C, Noguchi M, et al. Clinical application of a hyperdry amniotic membrane on surgical defects of the oral mucosa. *J Oral Maxillofac Surg* 2012;70:2221-8. <https://doi.org/10.1016/j.joms.2011.09.033>
9. Faulk WP, Matthews R, Stevens PJ, Bennett JP, Burgos H, Hsi BL. Human amnion as an adjunct in wound healing. *Lancet* 1980;1:1156-8. [https://doi.org/10.1016/s0140-6736\(80\)91617-7](https://doi.org/10.1016/s0140-6736(80)91617-7)
10. Kim JS, Kim JC, Na BK, Jeong JM, Song CY. Amniotic membrane patching promotes healing and inhibits proteinase activity on wound healing following acute corneal alkali burn. *Exp Eye Res* 2000;70:329-37. <https://doi.org/10.1006/exer.1999.0794>
11. Rinastiti M, Harijadi, Santoso AL, Sosroseno W. Histological evaluation of rabbit gingival wound healing transplanted with human amniotic membrane. *Int J Oral Maxillofac Surg* 2006;35:247-51. <https://doi.org/10.1016/j.ijom.2005.09.012>
12. Amemiya T, Nakamura T, Yamamoto T, Kinoshita S, Kanamura N. Immunohistochemical study of oral epithelial sheets cultured on amniotic membrane for oral mucosal reconstruction. *Biomed Mater Eng* 2010;20:37-45. <https://doi.org/10.3233/BME-2010-0613>
13. Kothari CR, Goudar G, Hallur N, Sikkerimath B, Gudi S, Kothari MC. Use of amnion as a graft material in vestibuloplasty: a clinical study. *Br J Oral Maxillofac Surg* 2012;50:545-9. <https://doi.org/10.1016/j.bjoms.2011.09.022>
14. Lakshmi S, Bharani S, Ambardar K. Repair of an oroantral communication by a human amniotic membrane: a novel technique. *J Korean Assoc Oral Maxillofac Surg* 2015;41:194-7. <https://doi.org/10.5125/jkaoms.2015.41.4.194>
15. Kar IB, Singh AK, Mohapatra PC, Mohanty PK, Misra S. Repair of oral mucosal defects with cryopreserved human amniotic membrane grafts: prospective clinical study. *Int J Oral Maxillofac Surg* 2014;43:1339-44. <https://doi.org/10.1016/j.ijom.2014.07.018>
16. Tsuno H, Arai N, Sakai C, Okabe M, Koike C, Yoshida T, et al. Intraoral application of hyperdry amniotic membrane to surgically exposed bone surface. *Oral Surg Oral Med Oral Pathol Oral Radiol* 2014;117:e83-7. <https://doi.org/10.1016/j.oooo.2012.05.014>
17. Ahn KM, Lee JH, Lee UL, Lee JH, Lee JW, Kim SP, et al. Development of biocompatible dressing material made of collagen and amniotic membrane and wound healing experiment in rat. *J Korean Assoc Oral Maxillofac Surg* 2006;32:189-99.
18. Hassan M, Prakasam S, Bain C, Ghoneima A, Liu SS. A randomized split-mouth clinical trial on effectiveness of amnion-chorion membranes in alveolar ridge preservation: a clinical, radiologic, and morphometric study. *Int J Oral Maxillofac Implants* 2017;32:1389-98. <https://doi.org/10.11607/jomi.5875>
19. Lyons AB, Chipps LK, Moy RL, Herrmann JL. Dehydrated human amnion/chorion membrane allograft as an aid for wound healing in patients with full-thickness scalp defects after Mohs micrographic surgery. *JAAD Case Rep* 2018;4:688-91. <https://doi.org/10.1016/j.jidcr.2018.03.015>
20. Zhou S, Sun C, Huang S, Wu X, Zhao Y, Pan C, et al. Efficacy of adjunctive bioactive materials in the treatment of periodontal intrabony defects: a systematic review and meta-analysis. *Biomed Res Int* 2018;2018:8670832. <https://doi.org/10.1155/2018/8670832>
21. Puyana S, Ruiz S, Elkbuli A, Bernal E, McKenney M, Askari M, et al. The use of dehydrated human amniotic membrane versus amniotic/chorionic membrane allografts to treat partial thickness facial

- burns. *J Craniofac Surg* 2020;31:201-3. <https://doi.org/10.1097/SCS.0000000000005834>
22. Nanda S, Chakraborty S, Ray A, Inamuddin. Healing of cervical necrotizing fasciitis using amniotic membrane as a dressing material. *Natl J Maxillofac Surg* 2011;2:147-51. <https://doi.org/10.4103/0975-5950.94469>
 23. Cullum D, Lucas M. Minimally invasive extraction site management with dehydrated amnion/chorion membrane (dHACM): open-socket grafting. *Compend Contin Educ Dent* 2019;40:178-83.
 24. Doig GS, Simpson F. Randomization and allocation concealment: a practical guide for researchers. *J Crit Care* 2005;20:187-91; discussion 191-3. <https://doi.org/10.1016/j.jcrc.2005.04.005>

How to cite this article: Gajul M, Bhate K, Awate S, Kakodkar P, Shah S. Comparative evaluation of the efficacy of wound healing with and without dehydrated human amniotic/chorionic membrane in alveoloplasty: a pilot study. *J Korean Assoc Oral Maxillofac Surg* 2021;47:279-285. <https://doi.org/10.5125/jkaoms.2021.47.4.279>