



Histopathology and ultrastructural findings of pediatric sialolithiasis: a brief communication

Kezia Rachellea Mustakim^{1,*}, Truc Thi Hoang Nguyen^{1,*}, Mi Young Eo¹, Soung Min Kim^{1,2}

¹Department of Oral and Maxillofacial Surgery, Dental Research Institute, School of Dentistry, Seoul National University, Seoul, Korea,

²Oral and Maxillofacial Microvascular Reconstruction LAB, Brong Ahafo Regional Hospital, Sunyani, Ghana

Abstract (J Korean Assoc Oral Maxillofac Surg 2022;48:125-129)

Sialolithiasis is a condition in which the salivary gland excretory duct is obstructed due to the formation of calcareous deposits and is uncommon in children compared to adults. The treatment modalities range from a conservative approach involving hydration to a surgical approach. Though several studies have analyzed the sialolith micromorphology structures, studies on pediatric sialoliths remain scarce. This brief communication aims to describe the sialolith micromorphology to understand the mechanism of mineralization and growth of pediatric sialoliths. A 6-year-old Korean female presented with swelling under her tongue. The intraoral examination revealed a painless yellowish hard mass beneath the tongue near the Wharton's duct which was suspected as a sialolith. After receiving the informed consent, the sialolithotomy was performed under local anesthesia. The obtained stone was analyzed through histopathology and transmission electron microscope examinations to understand the mechanism of mineralization and growth of pediatric sialolith. The micromorphology and growth processes of pediatric sialolith remain undescribed. More comprehensive microscopic studies are needed regarding their distinctive characteristics. By expanding knowledge about sialoliths micromorphology, development of new preventive, diagnostic and patient-tailored treatment methods of pediatric sialolithiasis will be enhanced.

Key words: Pediatrics, Sialolithiasis, Histopathology, Transmission electron microscopy, Ultrastructure

[paper submitted 2021. 7. 11 / revised 2021. 8. 16 / accepted 2021. 8. 18]

I. Introduction

Sialolithiasis occurs when the salivary gland excretory duct is obstructed by calcareous deposits and commonly found in adults, accounts for 30% of all salivary disorders but rarely in children as only 3% of all sialolithiasis cases¹. The submandibular gland is the most frequently involved site due to its long curvy duct and narrow orifice causing viscous mucinous saliva moves against gravity, resulting in saliva retention^{2,3}.

Francis and Larsen² suggest that sialolithiasis formation involves retrograde migration of any substances or pathogens

from oral cavity into the salivary ductal system to act as a nidus which precipitates organic and inorganic materials. Infection also alters the saliva composition, affecting protein precipitation and calcium solubility to result in stone formation². Though several studies have analyzed the sialolith crystalline structure, studies on pediatric sialoliths remain scarce. Therefore, we report submandibular sialolithiasis management in a 6-year-old child and analyze the sialolith micromorphology to understand the mechanism of mineralization and growth of pediatric sialoliths.

II. Case Report

A 6-year-old Korean female presented to the Oral and Maxillofacial Surgery Department, Seoul National University Dental Hospital for swelling under her tongue. This case report was approved by the Institutional Review Board of Seoul National Hospital (S-D20200010) on 3rd March 2021. The intraoral examination revealed a painless yellowish hard mass beneath the tongue near the Wharton's duct which was suspected as a sialolith.(Fig. 1. A) The patient was informed

Soung Min Kim

Department of Oral and Maxillofacial Surgery, Dental Research Institute, School of Dentistry, Seoul National University, 101 Daehak-ro, Jongno-gu, Seoul 03080, Korea

TEL: +82-2-2072-0213

E-mail: smin5@snu.ac.kr

ORCID: <https://orcid.org/0000-0002-6916-0489>

*These authors contributed equally to this work as first authors.

© This is an open-access article distributed under the terms of the Creative Commons Attribution Non-Commercial License (<http://creativecommons.org/licenses/by-nc/4.0/>), which permits unrestricted non-commercial use, distribution, and reproduction in any medium, provided the original work is properly cited.

Copyright © 2022 The Korean Association of Oral and Maxillofacial Surgeons.

that the mass would be removed surgically. However, the patient was resistant to the treatment plan and further follow-ups were scheduled to observe the symptom progress. Along the follow-ups, the symptoms progressed to painful, enlarged, festered mass with oral malodor. On the last follow-up, a computed tomography (CT) scan was performed and confirmed the sialolith near the right Wharton's duct orifice.(Fig. 1. B) After two years and two months from the first visit, the patient finally cooperated with surgery indication.

After receiving the informed consent, the sialolithotomy

was performed under local anesthesia using 2% lidocaine with 1:100,000 epinephrine. The sialolith was grasped with dental pincette and removed through blunt dissection using dissecting forceps.(Fig. 1. C) The 3 mm stone was cut transversely into two sections, for light microscope (LM) histopathologic and transmission electron microscope (TEM) slides preparation.(Fig. 1. D) The histologic section was fixed in 10% formalin and the TEM section was fixed in 2.5% glutaraldehyde. The wound was left open without a suture and dressed in the following day. The patient was instructed to

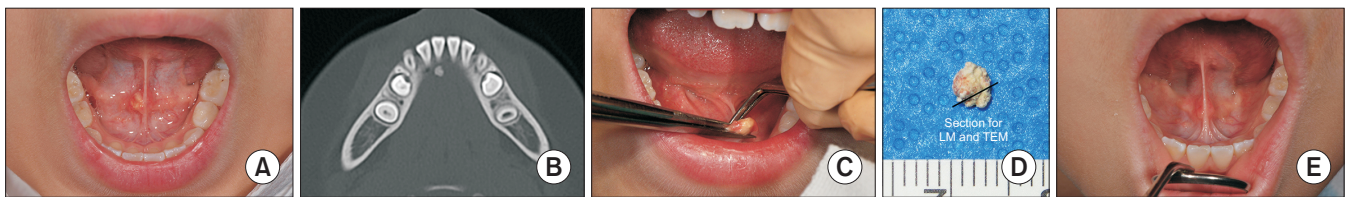


Fig. 1. A. Preoperative condition. B. The axial computed tomography view confirmed the sialolith at the Wharton's duct orifice. C. Sialolithotomy procedure using blunt dissection technique. D. The obtained 3-mm-diameter stone for light microscope (LM) and transmission electron microscope (TEM) examinations. E. One-month follow-up condition.

Kezia Rachellea Mustakim et al: Histopathology and ultrastructural findings of pediatric sialolithiasis: a brief communication. J Korean Assoc Oral Maxillofac Surg 2022

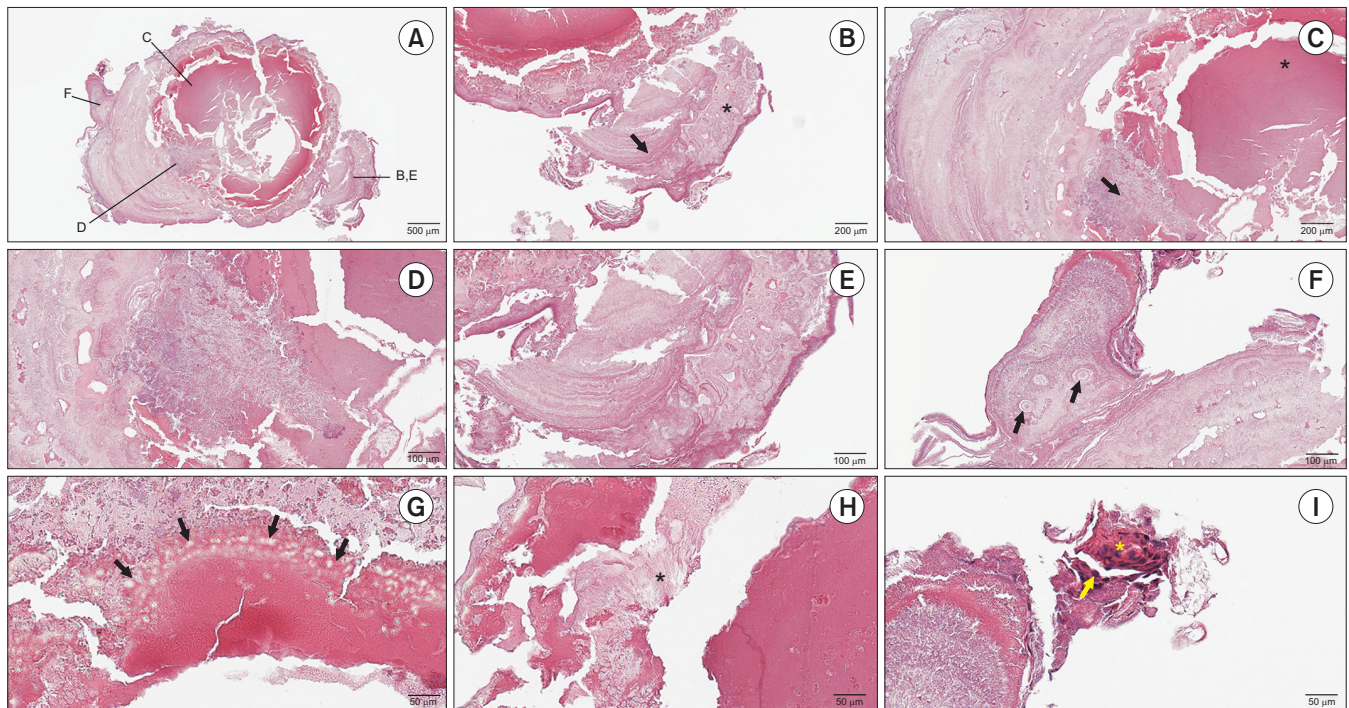


Fig. 2. A. The stone revealed varied calcification degrees (H&E staining, $\times 4$). Scale bar=500 μm . B. Laminated concentric patterns (black arrow) and mineralized nodules (black asterisk) (H&E staining, $\times 10$). Scale bar=200 μm . C. Eosinophilic core (black asterisk) and amorphous materials (black arrow) (H&E staining, $\times 10$). Scale bar=200 μm . D. Amorphous basophilic materials (H&E staining, $\times 20$). Scale bar=100 μm . E. The detail of laminated structures with concentric pattern and mineralized nodules of the sialolith (H&E staining, $\times 20$). Scale bar=100 μm . F. The branch consists of mineralized nodules (black arrows) (H&E staining, $\times 20$). Scale bar=100 μm . G. Globular structures (black arrows) (H&E staining, $\times 40$). Scale bar=50 μm . H. Needle-like crystallization (black asterisk) (H&E staining, $\times 40$). Scale bar=50 μm . I. Bacteria (yellow arrow) in the outer shell containing salivary ductal epithelium (yellow asterisk) (H&E staining, $\times 40$). Scale bar=50 μm .

Kezia Rachellea Mustakim et al: Histopathology and ultrastructural findings of pediatric sialolithiasis: a brief communication. J Korean Assoc Oral Maxillofac Surg 2022

maintain oral hygiene and practice tongue movements. At the one-month follow-up, the wound was fully healed without any problems.(Fig. 1. E)

The histologic slide was stained with H&E. Histologically, the stone revealed different degrees of calcification of organic and inorganic layers.(Fig. 2. A-F) Laminated concentric patterns (Fig. 2. B, black arrow [Fig. 2. E]) and mineralized nodules (Fig. 2. B, black asterisk [Fig. 2. E]; Fig. 2. F, black arrows) were observed in the outer layer of sialolith surrounding the eosinophilic core.(Fig. 2. C, black asterisk) Amorphous basophilic materials (Fig. 2. C, black arrow [Fig. 2. D]) were observed in several areas. In the peripheral eosinophilic zone, irregular pattern containing globular structures identified as globuli and tearlike globuli was observed.(Fig. 2. G, black arrows) A needle-like crystallization structure was observed between the peripheral eosinophilic zone and hollow space.(Fig. 2. H, black asterisk) A new branch of stone was observed outside the laminated structure and exhibited mineralized nodules.(Fig. 2. F) Small amounts of bacteria (Fig. 2. I, yellow arrow) were located at the outer shell of the sialolith containing salivary ductal epithelium.(Fig. 2. I, yellow asterisk)

In the TEM examination (JEM-1400 Flash; JEOL, Tokyo, Japan), the stone was stripped into 1 mm×1 mm×1 mm blocks, embedded in epoxy resin, cut into ultrathin sections

(70-80 nm) and scanned under 3,000× and 6,000×. The concentric laminar structure is illustrated in Fig. 3. A. In the internal lamellas, the globular structure dominated (Fig. 3. A, blue asterisk), while the crystalline pattern in several outer layers was heterogeneous with some regions of needle-like pattern.(Fig. 3. A, black asterisk) In the most external layer, a finger-like globuli was recorded.(Fig. 3. A, black arrows) Clusters of vesicle structures were observed in the external lamella of several regions, with tear-like structures adjacent to the major vesicles.(Fig. 3. B, blue arrow) Clusters of needle-like crystallites are shown in Fig. 3. C (blue asterisks). Globular exosomal-like structures approximately 0.5 μm in diameter were detected in the internal lamellas.(Fig. 3. D, blue arrows) Membranous bodies were observed adjacent to the vesicles.(Fig. 3. D, black asterisks) Several globules showed opaque internal and surface contractions, indicating deposition of microcrystalline inorganic compounds.(Fig. 3. D, black arrowhead) A detailed image of intra-vesicular (Fig. 3. E, blue arrowheads) and extra-vesicular (Fig. 3. E, black arrowheads) depositions of microcrystalline matter is shown in Fig. 3. E. Interestingly, several vesicle structures exhibited a double membrane.(Fig. 3. E, blue asterisks) Areas with a high density of vesicles are captured in Fig. 3. F. Intra-vesicular (Fig. 3. F, blue arrowheads) and extra-vesicular (Fig. 3. E, black arrowhead) depositions were observed in this cluster.

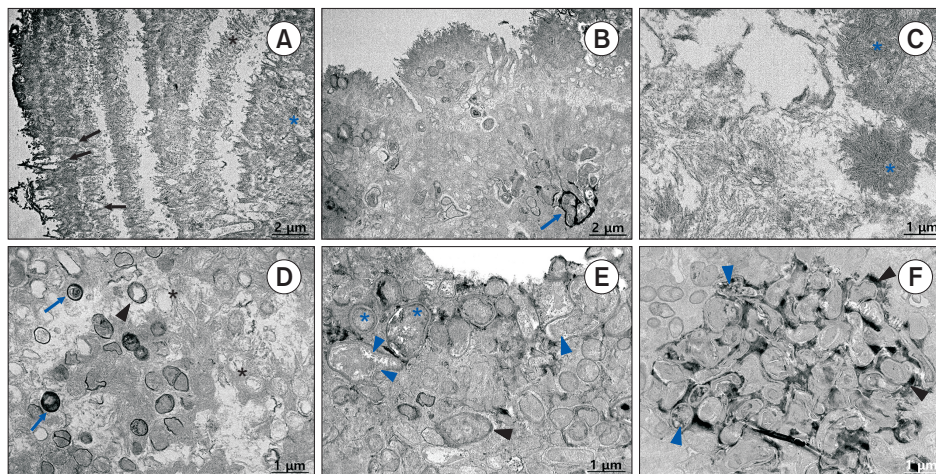


Fig. 3. Transmission electron microscope images of pediatric stone. A. In the internal lamellas, the globular structure was dominant (blue asterisk), while the crystalline pattern was heterogeneous in several outer layers, with some regions of needle-like patterns (black asterisk). Finger-like globuli were recorded (black arrows), magnification 3,000×. B. Clusters of vesicle structures with tear-like structures adjacent to the major vesicles (blue arrow), magnification 3,000×. C. Needle-like crystallites were arranged in clusters (blue asterisks), magnification 6,000×. D. Globular exosomal-like structures approximately 0.5 μm in diameter were detected in the internal lamellas (blue arrows). Membranous bodies were observed adjacent to the vesicles (black asterisks). Some globules were noticed to have internal and surface opaque contraction (black arrowhead), magnification 6,000×. E. Two patterns of calcification related to structure: intra-vesicular (blue arrowheads) and extra-vesicular (black arrowheads) patterns. Some vesicle structures had double membranes (blue asterisks), magnification 6,000×. F. Area of high-density vesicles showing intra-vesicular (blue arrowheads) and extra-vesicular (black arrowhead) deposition, magnification 6,000×.

Kezia Rachellea Mustakim et al: Histopathology and ultrastructural findings of pediatric sialolithiasis: a brief communication. J Korean Assoc Oral Maxillofac Surg 2022

III. Discussion

Submandibular gland sialolithiasis appears as swelling in the Wharton's duct area. It can be asymptomatic at first, but discomfort and pain due to duct contractions in an attempt to eliminate saliva will appear gradually⁴. Symptoms may also be accompanied by the intraoral purulent discharge¹. Pediatric sialolithiasis symptoms are short due to patients and parents low tolerance to uncomfortable symptoms⁵. In our case, the patient initially presented with painless swelling, but pain, oral malodor, pus discharge, and stone enlargement gradually appeared.

Sialolith structure can be classified into concentric and irregular patterns, with high and low mineralization⁶. In H&E staining, it appears as alternating eosinophilic and basophilic zones or globular calcified zones, formed by organic and inorganic materials⁷⁻⁹. Basophilic zone indicates a highly mineralized area (Fig. 2. D), whereas the eosinophilic zone indicates less mineralization. Frequently, the core is predominated by organic materials while inorganic materials form the concentric pattern. In many studies, the core is globular and highly mineralized or only composed of mineral/inorganic materials^{6,7,10}. The present sialolith core was homogenous eosinophilic without specific structure, indicating organic materials domination.(Fig. 2. A, 2. C) Under high magnification light microscopy, macromolecules were observed, highly suggestive of lipid compounds, which might originate from degenerated salivary gland membrane¹¹. This differs from the five-year-old girl submandibular gland sialolith reported by Lee et al.¹², which showed a basophilic core.

In our case, laminated concentric patterns and mineralized nodules in sialolith outer layer and irregular pattern in peripheral eosinophilic zone were observed.(Fig. 2. B, 2. E) The concentric pattern corresponds to steady-state growth, while the irregular pattern indicates sialolith growth perturbations due to chronic inflammation/infection. These structure variations affect the sialolith fracture toughness and mechanical behavior. Meanwhile, mineralized nodules indicate the ongoing growth stages⁶. The sialolith branch containing mineralized nodules in this case may indicate the ongoing growth and formation of a new layer.(Fig. 2. F) According to Hayashibara et al.¹³, pediatric sialoliths are more fragile than adult stones during sectioning. In our sialolith, during microscopic slides preparation, the stone was fragile and easily divided which might correlate to the peripheral eosinophilic area irregular growth pattern and core organic composition. Meanwhile, contrary to our core organic composition, Kasaboglu

et al.¹⁴ study regarding micromorphology of submandibular sialoliths obtained from six adult patients aged 48 to 62 years revealed no organic material in the cores, and the cores were completely crystallized. However, Hayashibara et al.¹³, found no significant differences in elements, radiopacities and Ca/P ratios when comparing adult and pediatric sialoliths. The globular structure (Fig. 2. G) was associated with organic components segregation and was considered as lipids accumulation^{6,15}. Furthermore, the tearlike globular structures suggest the globuli as a dynamic structure and indicate the ongoing calcification process with organic materials elimination. Needle-like crystallizations (Fig. 2. H) is thought to be associated with peripheral organic substances resulting from successive precipitation events which follows compositional gradients¹⁵.

Infection occurs when intraoral pathogenic bacteria enter the salivary gland or from stagnant saliva in the duct which can cause sialadenitis⁷. In this case histologic slide, the bacteria appeared only at the outer shell containing salivary gland epithelium indicating bacteria originated from the salivary gland epithelium which was included during sialolithotomy. (Fig. 2. I) This can explain the observed festered swelling.

TEM images of sialolith have revealed intra-vesicular and extra-vesicular calcifications around globular lysosome-like structures.(Fig. 3. A, 3. F) Some vesicles have exhibited mitochondria-like morphology though without the crista structure. The mitochondria and lysosomes seem to be degenerative products from salivary gland and ductal cells, accumulated due to the obstruction and then underwent mineralization within the stone.(Fig. 3. B, 3. D) In the TEM images, the mineralized crystalline regions appeared dark in bright-field imaging because of heavy element diffraction.(Fig. 3. C) Tear-like structures surrounding major vesicles can display organic material leakage from the vesicle structures.(Fig. 3. B) It is suggested that calcification of vesicle structures is accompanied by elimination of organic materials, producing surrounding tear-like structures⁶.(Fig. 3. E, 3. F)

Treatment modalities for sialolithiasis include a conservative approach through the sialoendoscopy and salivary ductal irrigation, good hydration, analgesic and antibiotic medication, and sialogogues to foster spontaneous stones removal especially stone smaller than 2 mm. However, spontaneous removal in children can be difficult due to the small opening of the duct^{1,4}. Intraoral removal under local anesthesia is a treatment of choice for children with relatively small stones and stones in the distal part of the Wharton's duct^{3,5}. In our case, we performed intraroral sialolithotomy without suturing

the wound to avoid duct obstruction.

In conclusion, the micromorphology and growth processes of pediatric sialolith remain undescribed. We found that the pediatric sialolith core composition is different from the adult sialoliths which may relate to a different growth pattern and mechanical behavior of the stone. However, more comprehensive microscopic studies are needed regarding their distinctive characteristics. By expanding knowledge about sialoliths micromorphology, development of new preventive, diagnostic and patient-tailored treatment methods of pediatric sialolithiasis will be enhanced.

ORCID

Kezia Rachellea Mustakim, <https://orcid.org/0000-0002-4283-499X>

Truc Thi Hoang Nguyen, <https://orcid.org/0000-0002-8667-6698>

Mi Young Eo, <https://orcid.org/0000-0001-7055-9924>

Soung Min Kim, <https://orcid.org/0000-0002-6916-0489>

Authors' Contributions

K.R.M. and T.T.H.N. wrote the manuscript, M.Y.E. collected the data and images, S.M.K. coordinated and designed the whole manuscript. All authors read and approved the final manuscript.

Acknowledgements

This research was supported by Basic Science Research Program funded by the Ministry of Education (2017R1D1A1B04029339) and by grant No. 03-2019-0043 from the SNU DH Research Fund.

Conflict of Interest

No potential conflict of interest relevant to this article was reported.

References

1. Thong HK, Mohamad Mahbob H, Sabir Husin Athar PP, Tengku

- Kamalden TMI. Recurrent submandibular sialolithiasis in a child. *Cureus* 2020;12:e12163. <https://doi.org/10.7759/cureus.12163>
2. Francis CL, Larsen CG. Pediatric sialadenitis. *Otolaryngol Clin North Am* 2014;47:763-78. <https://doi.org/10.1016/j.otc.2014.06.009>
3. Park SY, Lee SH, Lee NY, Jih MK. Sialolithiasis in children: three case reports. *Oral Biol Res* 2019;43:340-8. <https://doi.org/10.21851/obr.43.04.201912.340>
4. Karengera D, Yousefpour A, Sadeghi HM, Reyhler H. Sialolithiasis in children as a diagnostic dilemma. *Eur Arch Otorhinolaryngol* 2000;257:161-3. <https://doi.org/10.1007/s004050050215>
5. Inui A, Itou R, Oyama T, Tamura Y, Kubota K, Kobayashi W. Comparison of sialolithiasis in pediatric and adult patients. *Oral Sci Int* 2017;14:37-9. [https://doi.org/10.1016/S1348-8643\(17\)30019-8](https://doi.org/10.1016/S1348-8643(17)30019-8)
6. Nolasco P, Anjos AJ, Marques JM, Cabrita F, da Costa EC, Mauricio A, et al. Structure and growth of sialoliths: computed microtomography and electron microscopy investigation of 30 specimens. *Microsc Microanal* 2013;19:1190-203. <https://doi.org/10.1017/S1431927613001694>
7. Alcure ML, Vargas PA, Jorge Júnior J, di Hipólito Júnior O, Lopes MA. Clinical and histopathological findings of sialoliths. *Braz J Oral Sci* 2005;4:899-903.
8. De-Castro ICV, de-Jesus AAF, De Azevedo RA, Campos PSF, dos Santos JN. Clinicopathological study of sialolithiasis: a retrospective analysis of 11 cases. *J Oral Diagn* 2019;04:e20190006.
9. Busso CS, Guidry JJ, Gonzalez JJ, Zorba V, Son LS, Winsauer PJ, et al. A comprehensive analysis of sialolith proteins and the clinical implications. *Clin Proteomics* 2020;17:12. <https://doi.org/10.1186/s12014-020-09275-w>
10. Tretiakow D, Skorek A, Wysocka J, Darowicki K, Ryl J. Classification of submandibular salivary stones based on ultrastructural studies. *Oral Dis* 2021;27:1711-9. <https://doi.org/10.1111/odi.13708>
11. Im YG, Kook MS, Kim BG, Kim JH, Park YJ, Song HJ. Characterization of a submandibular gland sialolith: micromorphology, crystalline structure, and chemical compositions. *Oral Surg Oral Med Oral Pathol Oral Radiol* 2017;124:e13-20. <https://doi.org/10.1016/j.oooo.2017.03.011>
12. Lee HS, Choi BJ, Choi HJ, Kim SO, Son HK, Song JS, et al. Sialolithiasis on the mouth floor in a child. *J Korean Acad Pediatr Dent* 2009;36:114-8.
13. Hayashibara T, Nakano K, Sobue S, Ooshima T. Salivary calculi in children: a study using an energy dispersive X-ray analyzer and contact microradiography. *Pediatr Dent J* 2004;14:41-5. <https://doi.org/10.11411/pdj.14.41>
14. Kasaboğlu O, Er N, Tümer C, Akkocaoğlu M. Micromorphology of sialoliths in submandibular salivary gland: a scanning electron microscope and X-ray diffraction analysis. *J Oral Maxillofac Surg* 2004;62:1253-8. <https://doi.org/10.1016/j.joms.2003.11.018>
15. Alves de Matos AP, Carvalho PA, Almeida A, Duarte L, Vilar R, Leitão J. On the structural diversity of sialoliths. *Microsc Microanal* 2007;13:390-6. <https://doi.org/10.1017/S1431927607070754>

How to cite this article: Mustakim KR, Nguyen TTH, Eo MY, Kim SM. Histopathology and ultrastructural findings of pediatric sialolithiasis: a brief communication. *J Korean Assoc Oral Maxillofac Surg* 2022;48:125-129. <https://doi.org/10.5125/jkaoms.2022.48.2.125>