



Sinus mucosal healing pattern according to pterygomaxillary disjunction type after Le Fort I osteotomy

Tae-Seok Jang¹, Seung-Woo Lee¹, Baek-Soo Lee^{1,2}, Gyujo Shim¹, Suyun Seon¹, Joo-Young Ohe^{1,2}

¹Department of Oral and Maxillofacial Surgery, Kyung Hee University Dental Hospital,

²Department of Oral and Maxillofacial Surgery, School of Dentistry, Kyung Hee University, Seoul, Korea

Abstract (J Korean Assoc Oral Maxillofac Surg 2022;48:292-296)

Objectives: During Le Fort I osteotomy, the separation of the pterygomaxillary junction (PMJ) is a difficult procedure for most surgeons because it is invisible. In this process, damage to the posterior structures constituting the sinus or those adjacent to it, including the maxillary sinus posterior wall and pterygoid plate, may occur. We would like to investigate the effects of this on the inside of the maxillary sinus after surgery and whether there are complications.

Materials and Methods: One-hundred patients who underwent Le Fort I osteotomy from 2013 to 2020 using cone-beam computed tomography images were classified into two groups (clean-cut type and fractured type) according to the PMJ cutting pattern. In addition, the mucosal thickness in the maxillary sinus was divided into preoperative, postoperative three months, one year, and the change over the course of surgery was evaluated retrospectively.

Results: Of the total 100 cases, the clean-cut type numbered 28 cases and the fractured type totaled 72 cases. Among the fracture types, part of the sinus wall and the pterygoid plate were broken in 69 cases, and the maxillary sinus posterior wall was detached in three cases. There was no statistically significant difference in sinus mucosal thickening between the clean-cut type and fractured type of the PMJ, three months and one year after surgery between the two groups. However, there was a significant difference in sinus mucosal thickness at postoperative one year in the case where a partial detachment of the maxillary sinus posterior wall occurred compared to not.

Conclusion: Even if there is some damage to the structures behind the PMJ, it may not be reasonable to spend some time on the PMJ separation process considering the overall postoperative complications, if there is no significant difference inside the sinus, or increased probability of postoperative complications.

Key words: Maxillary osteotomy, Pterygomaxillary junction, Maxillary sinus, Mucous membrane

[paper submitted 2022. 7. 19 / revised 2022. 8. 11 / accepted 2022. 8. 17]

I. Introduction

Le Fort I osteotomy, performed to improve skeletal malocclusion in the course of orthodontic treatment, is a commonly performed surgical method because it can achieve dramatic results by enabling free movement of the maxilla^{1,2}. This is a surgery that is separated by crossing from the sinus wall

level of the maxillary bone. The front and sides can be visibly sawed, while the separation of the pterygomaxillary junction (PMJ) located at the posterior part is invisible, which is a difficult procedure for most surgeons^{3,4}. For this reason, the pterygoid vein plexus, descending palatal artery, posterior wall of the maxillary sinus, pterygoid plate, etc. are carefully separated using an osteotome and mallet to minimize postoperative complications^{3,4}.

When the cross-sectional separation at the sinus wall level of the maxilla is finished, the shape and volume of the maxillary sinus change according to the three-dimensional movement of the maxilla^{5,6}. After surgery, the maxillary sinus is filled with blood, and the change in mucosal thickness, swelling, and other inflammatory reactions appear during the healing process⁷. Mucosal thickness usually increases after surgery and then gradually decreases⁷.

Joo-Young Ohe

Department of Oral and Maxillofacial Surgery, Kyung Hee University Dental Hospital, 26 Kyungheedaero, Dongdaemun-gu, Seoul 02447, Korea

TEL: +82-2-958-9360

E-mail: ojyoung81@naver.com

ORCID: <https://orcid.org/0000-0002-4411-7871>

© This is an open-access article distributed under the terms of the Creative Commons Attribution Non-Commercial License (<http://creativecommons.org/licenses/by-nc/4.0/>), which permits unrestricted non-commercial use, distribution, and reproduction in any medium, provided the original work is properly cited.

Copyright © 2022 The Korean Association of Oral and Maxillofacial Surgeons.

Maxillary sinus mucous thickening does not necessarily cause any inflammatory symptoms or discomfort to the patient⁷, and is sometimes asymptomatic. However, a persistently thickened mucous membrane can result in chronic sinusitis, which can cause symptoms such as headache and nasal congestion, and this can make it difficult to perform subsequent sinus-related surgery, including a sinus graft.

Many studies have been conducted to investigate the relationship between various factors that can affect the maxillary sinus after Le Fort I osteotomy. However, there are insufficient studies on the effect of the pterygomaxillary disjunction type, which constitutes the posterior part of the maxilla, on the healing pattern of the maxillary sinus after surgery. In this paper, to investigate the difference in changes in the maxillary sinus healing according to different separation patterns of PMJ, cutting types were classified into two groups and the thickness changes of the maxillary sinus mucosa were investigated. Based on this, we can think about the precautions to be taken in the PMJ separation process and whether the effort and time to cleanly separate the PMJ is reasonable.

II. Materials and Methods

The study was approved by the Institutional Review Board (IRB) of Kyung Hee University Dental Hospital (IRB No. KH-DT22019) and the informed consent was waived by the IRB.

This study is a retrospective cohort study in which 100 patients who underwent Le Fort I osteotomy from 2013 to 2020 at Kyung Hee University Dental Hospital were followed-up by cone-beam computed tomography (CBCT) for one year. The operation was performed by only one oral and maxillofacial surgeon.

Through 100 CBCTs, we classified the PMJ cutting type into two groups, clean cut type (Type I) (Fig. 1. A) and fractured type (Type II).(Fig. 1. B, 1. C) To compare the changes in mucosal thickness of the maxillary sinus over time, we measured it in preoperative, postoperative three months, and postoperative one year.

In addition, the fractured type was classified into the posterior wall type (Type II-1) in which the posterior wall of the maxillary sinus was significantly separated, and the pterygoid fracture type (Type II-2) in which a part of the posterior wall of the maxillary sinus and the pterygoid plate were damaged,

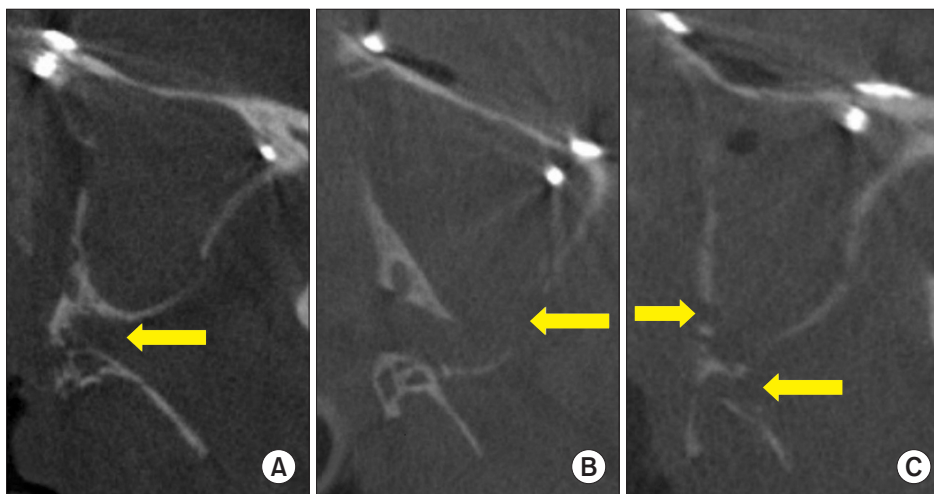


Fig. 1. Pterygomaxillary junction (PMJ) cutting type in postoperative cone-beam computed tomography. A. Type I: the cutting line within the PMJ (arrow). B. Type II-1: the posterior wall of maxillary sinus detached (arrow). C. Type II-2: a part of posterior wall of the maxillary sinus (left arrow) and pterygoid (right arrow) fracture occurred after PMJ separation.

Tae-Seok Jang et al: Sinus mucosal healing pattern according to pterygomaxillary disjunction type after Le Fort I osteotomy. *J Korean Assoc Oral Maxillofac Surg* 2022

Table 1. Information of the patients who underwent Le Fort I osteotomy

Sex	Skeletal diagnosis					Total
	Non-asymmetry		Asymmetry		Etc.	
	Protrusion	Retrusion	Protrusion	Retrusion		
	Maxillary movement type		Maxillary movement type			
Setback	Advance	Setback	Advance			
Male ¹	15	4	25	3	1	48
Female ¹	20	1	13	5	13	52
Total	35	5	38	8	14	100

¹Mean age (mean±standard deviation): male, 23.52±10.00 years; female, 22.19±8.00 years.

Etc.: performed posterior impaction or canting correction.

Tae-Seok Jang et al: Sinus mucosal healing pattern according to pterygomaxillary disjunction type after Le Fort I osteotomy. *J Korean Assoc Oral Maxillofac Surg* 2022

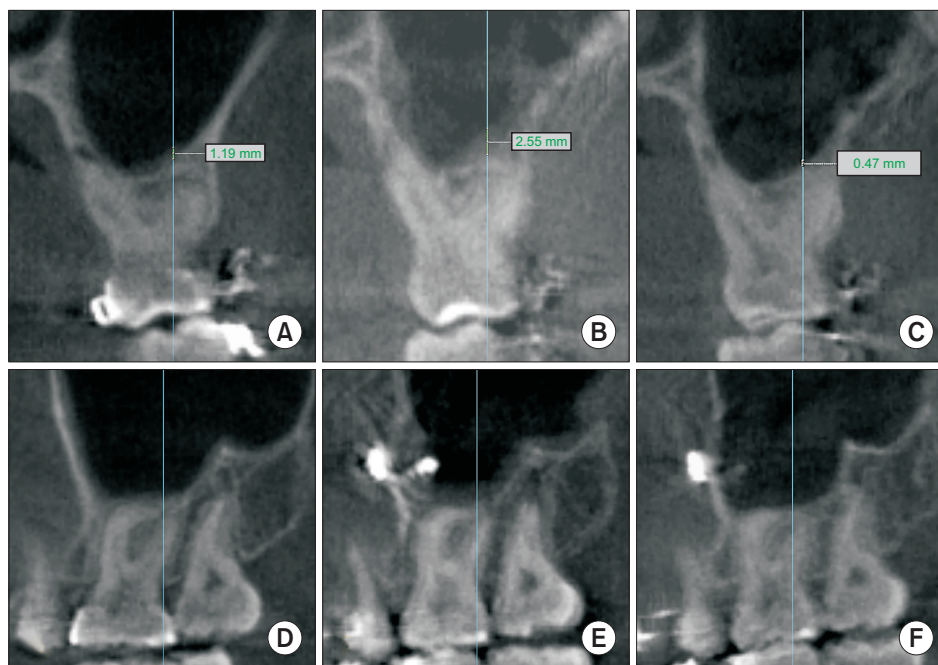


Fig. 2. Measurement of maxillary sinus mucosal thickness over time. A, D. Preoperative. B, E. Postoperative 3 months. C, F. Postoperative 1 year. *Tae-Seok Jang et al: Sinus mucosal healing pattern according to pterygomaxillary disjunction type after Le Fort I osteotomy. J Korean Assoc Oral Maxillofac Surg 2022*

Table 2. Number of cases by type

PMJ cutting type	No. of cases
1. Clean cut type (Type I)	28
2. Posterior wall type (Type II-1)	3
3. Pterygoid fracture type (Type II-2)	69
Total	100

(PMJ: pterygomaxillary junction)

A total of 100 cases were classified according to PMJ cutting type and were measured for sinus mucosal thickness.

Tae-Seok Jang et al: Sinus mucosal healing pattern according to pterygomaxillary disjunction type after Le Fort I osteotomy. J Korean Assoc Oral Maxillofac Surg 2022

respectively, and measured as seen in Fig. 1. B and 1. C.

For PMJ cutting, the right maxilla was mainly selected from CBCT taken one day postoperative. However, in the evaluation of factors related to mucosal thickening, the presence of disease in the maxillary sinus was investigated before surgery, and if there was a history of surgery in the right maxillary sinus or a change in the right sinus mucosal thickness was detected, the contralateral left side was classified and measured.

Therefore, PMJ cutting investigation and classification of areas with no history of maxillary sinus disease and related surgery were performed on 100 males and females with a mean age of 22.8 years (range, 18-43 years) at the time of surgery and sinus mucosal thickness was measured.(Table 1) Mucosal thickness over time was measured at the same point (approximately the first molar distobuccal root site) of the maxillary sinus on the side where the PMJ cutting type was observed.(Fig. 2)

Method error was defined as the reproducibility of double judgment and calculated as the standard error of measurement. The method error of repeated linear measurements was

Table 3. Mean mucosal thickness over time

	Preoperative	Postoperative	
		3 mo	1 yr
Mean mucosal thickness (mm)	0.32	3.74	1.34

Tae-Seok Jang et al: Sinus mucosal healing pattern according to pterygomaxillary disjunction type after Le Fort I osteotomy. J Korean Assoc Oral Maxillofac Surg 2022

within 0.3 mm. A statistically significant difference was not detected in linear measurements.

Since the mucosal thickening of each group did not follow a normal distribution, statistical analysis was performed using non-parametric tests, Mann-Whitney U test, and Kruskal-Wallis test. Statistical analysis was performed using IBM SPSS Statistics (ver. 26.0; IBM, Armonk, NY, USA). *P*-values less than 0.05 were statistically significant.

III. Results

The Type I cases numbered 28 out of 100 cases and the Type II represented 72 cases. Among fractured types, the Type II-1 was detached in three cases.(Table 2) After surgery, the sinus mucosal thickness increased by more than 3 mm on mean (3.74 mm) at three months and decreased to less than 2 mm after one year.(Table 3) The Type I and Type II cases were measured and compared as seen in Fig. 3, and Type II was classified into Type II-1 and Type II-2, measured, and compared as seen in Fig. 4.

There was no difference in the standard deviation of sinus mucosal thickness at postoperative three months and one year

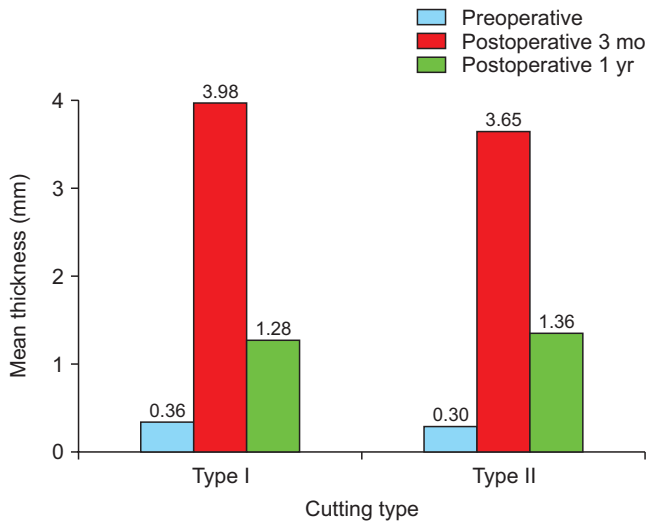


Fig. 3. Sinus mucosal thickness by two groups (Type I and Type II). *Tae-Seok Jang et al: Sinus mucosal healing pattern according to pterygomaxillary disjunction type after Le Fort I osteotomy. J Korean Assoc Oral Maxillofac Surg 2022*

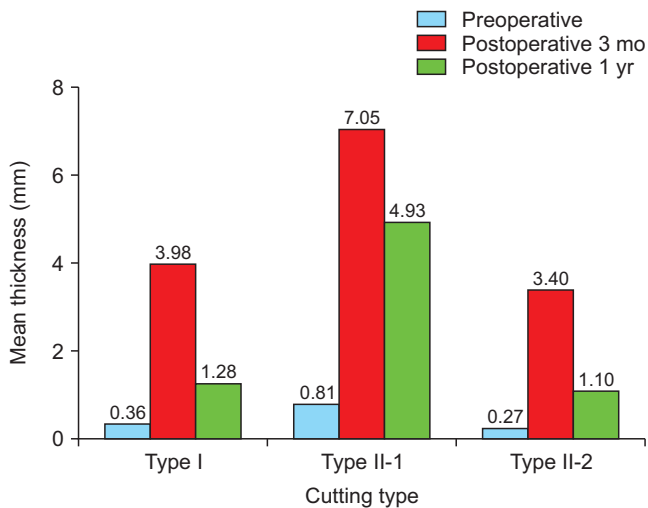


Fig. 4. Type II was classified into subgroups (Type II-1 and Type II-2) and mucosal thickness was compared. There was a significant difference in the mean mucosal thickness of Type II-1 at 1 year after surgery.

Tae-Seok Jang et al: Sinus mucosal healing pattern according to pterygomaxillary disjunction type after Le Fort I osteotomy. J Korean Assoc Oral Maxillofac Surg 2022

between Type I and Type II, and no statistical significance was noted. So, there was no difference in sinus mucosal thickening at postoperative three months and one year between the two groups.(Table 4) However, there was a significant difference in sinus mucosal thickness one year after surgery in Type II-1 compared to the other types, as seen in Tables 5 and 6.

IV. Discussion

Separation of the PMJ during the Le Fort I osteotomy is

Table 4. Statistical comparison between the Type I and Type II mucosal thickness

	P-value
Postoperative 3 mo	0.899
Postoperative 1 yr	0.296

Tae-Seok Jang et al: Sinus mucosal healing pattern according to pterygomaxillary disjunction type after Le Fort I osteotomy. J Korean Assoc Oral Maxillofac Surg 2022

Table 5. Statistical comparison of mucosal thickness on three cutting types (Type I, Type II-1, and Type II-2)

	P-value
Postoperative 3 mo	0.333
Postoperative 1 yr	0.015

Tae-Seok Jang et al: Sinus mucosal healing pattern according to pterygomaxillary disjunction type after Le Fort I osteotomy. J Korean Assoc Oral Maxillofac Surg 2022

Table 6. Statistical comparison of the Type I, Type II-1, and Type II-2 after one year

Mucosal thickness in 1 year after surgery	P-value
Type I vs Type II-1	0.022
Type II-1 vs Type II-2	0.011

Tae-Seok Jang et al: Sinus mucosal healing pattern according to pterygomaxillary disjunction type after Le Fort I osteotomy. J Korean Assoc Oral Maxillofac Surg 2022

a challenging procedure for most surgeons because it is not directly visible^{3,4}. So, it is difficult to separate the PMJ as intended, and posterior structures such as the pterygoid vein plexus, descending palatal artery, posterior wall of the maxillary sinus, and pterygoid plate may be damaged in this process⁴. Due to this damage, some bleeding may be observed, thereby prolonging the operation time. So, the surgeon spends effort and time to separate the PMJ cleanly in the hope that it will preserve the adjacent structures and reduce the possibility of postoperative complications.

However, if bleeding is controlled, posterior and lateral maxillary movement becomes easier by fracturing posterior hard tissue structure, including the pterygoid plate. As a result, it is possible to shorten the overall operation time by skipping the process of trimming the hard tissue structures. In addition, it can be expected that the incidence of postoperative complications can be further reduced.

Further, if the posterior wall of the maxillary sinus is not detached, the PMJ separation pattern does not significantly affect the occurrence of internal problems or recovery patterns after Le Fort I osteotomy. Therefore, it may not be reasonable to spend time, even at the risk of postoperative complications, due to the extension of the operation time.

Of course, whether only damage to the posterior wall of the maxillary sinus, or the gap caused by the three-dimensional movement of the maxilla also affected the maxillary sinus mucosal thickening could be considered. During Le Fort I os-

teotomy, the amount of three-dimensional movement including impaction, advance, and setback of the maxilla was all within 5 mm, and soft tissue proliferated and penetrated the gap in the transversely separated sinus of the maxilla. However, most cases were not accompanied by an overall thickening of the maxillary sinus mucosa. The infiltrated soft tissue was usually observed in a limited area up to one year after surgery, but no specificity was found in the maxillary sinus. In other words, it can be considered that the gap in the maxillary sinus wall caused by the movement of the maxilla has no effect on complications within the maxillary sinus after surgery. However, additional research is needed on whether the gap generated by the maxillary movement of more than 5 mm affects the maxillary sinus mucosal thickening.

In addition, we can see from these data that there is little effect on the inside of the maxillary sinus due to penetrating screws through the maxillary cortical bone and sinus membrane for plate fixation after the maxilla movement. Based on this, even if the implant fixture penetrates the sinus membrane during placement, it can be considered that this does not cause problems inside the sinus, such as sinusitis.

V. Conclusion

The PMJ separation process during Le Fort I osteotomy is invisible, so it may take some time because it is difficult to cleanly separate. Although there is some damage to posterior structures of the PMJ, we found that there is no significant difference inside the sinus in the postoperative complication compared to the clean cut case. Therefore, spending significant time on the PMJ cutting process may not be a good choice considering the overall postoperative complications.

ORCID

Tae-Seok Jang, <https://orcid.org/0000-0001-9063-9761>
Seung-Woo Lee, <https://orcid.org/0000-0001-6750-9643>
Baek-Soo Lee, <https://orcid.org/0000-0002-9145-8062>
Gyujo Shim, <https://orcid.org/0000-0003-1938-1846>
Suyun Seon, <https://orcid.org/0000-0002-2870-2747>
Joo-Young Ohe, <https://orcid.org/0000-0002-4411-7871>

Authors' Contributions

T.S.J. and S.S. participated in data collection and wrote the manuscript. T.S.J., S.W.L., and G.S. participated in the study design and performed the statistical analysis. J.Y.O., T.S.J.,

and B.S.L. participated in the study design and coordination and helped to draft the manuscript. All authors read and approved the final manuscript.

Ethics Approval and Consent to Participate

This study was approved by IRB of Kyung Hee University Dental Hospital (IRB No. KH-DT22019) and the informed consent was waived by the IRB.

Conflict of Interest

No potential conflict of interest relevant to this article was reported.

References

1. Iwamoto M, Watanabe M, Yamamoto M, Narita M, Kamio T, Takaki T, et al. Prognostic factors for maxillary sinus mucosal thickening following Le Fort I osteotomy: a retrospective analysis. *Maxillofac Plast Reconstr Surg* 2019;41:12. <https://doi.org/10.1186/s40902-019-0195-3>
2. Joh Y, Park HS, Yang HJ, Hwang SJ. Horizontal change of philtrum after orthognathic surgery in patients with facial asymmetry. *Maxillofac Plast Reconstr Surg* 2019;41:48. <https://doi.org/10.1186/s40902-019-0232-2>
3. Chin YP, Leno MB, Dumrongwongsiri S, Chung KH, Lin HH, Lo LJ. The pterygomaxillary junction: an imaging study for surgical information of LeFort I osteotomy. *Sci Rep* 2017;7:9953. <https://doi.org/10.1038/s41598-017-10592-8>
4. Dadwal H, Shanmugasundaram S, Krishnakumar Raja VB. Preoperative and postoperative CT scan assessment of pterygomaxillary junction in patients undergoing Le Fort I osteotomy: comparison of pterygomaxillary dysjunction technique and trimble technique-a pilot study. *J Maxillofac Oral Surg* 2015;14:713-9. <https://doi.org/10.1007/s12663-014-0720-y>
5. Bin LR, Filho LI, Yamashita AL, de Souza Pinto GN, Mendes RA, Ramos AL, et al. How does bimaxillary orthognathic surgery change dimensions of maxillary sinuses and pharyngeal airway space? *Angle Orthod* 2020;90:715-22. <https://doi.org/10.2319/120919-782.1>
6. Panou E, Motro M, Ateş M, Acar A, Erverdi N. Dimensional changes of maxillary sinuses and pharyngeal airway in class III patients undergoing bimaxillary orthognathic surgery. *Angle Orthod* 2013;83:824-31. <https://doi.org/10.2319/100212-777.1>
7. Shanbhag S, Karnik P, Shirke P, Shanbhag V. Association between periapical lesions and maxillary sinus mucosal thickening: a retrospective cone-beam computed tomographic study. *J Endod* 2013;39:853-7. <https://doi.org/10.1016/j.joen.2013.04.010>

How to cite this article: Jang TS, Lee SW, Lee BS, Sim G, Seon S, Ohe JY. Sinus mucosal healing pattern according to pterygomaxillary disjunction type after Le Fort I osteotomy. *J Korean Assoc Oral Maxillofac Surg* 2022;48:292-296. <https://doi.org/10.5125/jkaoms.2022.48.5.292>