



# Radiographic evaluation before surgical extraction of impacted third molar to reduce the maxillary sinus related complication

Mi Hyun Seo, Buyanbileg Sodnom-Ish, Mi Young Eo, Hoon Myoung, Soung Min Kim

*Department of Oral and Maxillofacial Surgery, Dental Research Institute, School of Dentistry, Seoul National University, Seoul, Korea*

**Abstract** (J Korean Assoc Oral Maxillofac Surg 2023;49:192-197)

**Objectives:** Surgical extraction of maxillary third molars is routine in departments devoted to oral and maxillofacial surgery. Because maxillary third molars are anatomically adjacent to the maxillary sinus, complications such as oroantral fistula and maxillary sinusitis can occur. Here we explore the factors that can cause radiographic postoperative swelling of the maxillary sinus mucosa after surgical extraction.

**Materials and Methods:** This retrospective study reviewed the clinical records and radiographs of patients who underwent maxillary third-molar extraction. Preoperative panoramas, Waters views, and cone-beam computed tomography were performed for all patients. The patients were divided into two groups; those with and those without swelling of the sinus mucosa swelling or air-fluid level in a postoperative Waters view. We analyzed the age and sex of patients, vertical position, angulation, number of roots, and relation to the maxillary sinus between groups. Statistical analysis used logistic regression and  $P < 0.05$  was considered statistically significant.

**Results:** A total of 91 patients with 153 maxillary third molars were enrolled in the study. Variables significantly related to swelling of the maxillary sinus mucosa after surgical extraction were the age and the distance between the palatal cemento-enamel junction (CEJ) and the maxillary sinus floor ( $P < 0.05$ ). Results of the analysis show that the relationship between the CEJ and sinus floor was likely to affect postoperative swelling of the maxillary sinus mucosa.

**Conclusion:** Maxillary third molars are anatomically adjacent to the maxillary sinus and require careful handling when the maxillary sinus is pneumatized to the CEJ of teeth.

**Key words:** Maxilla, Third molar, Maxillary sinus, Cone-beam computed tomography, Panoramic radiography

[paper submitted 2023. 1. 8 / revised 2023. 2. 13 / accepted 2023. 2. 18]

## I. Introduction

Maxillary third molars are routinely extracted in oral and maxillofacial surgery for therapeutic and prophylactic purposes<sup>1</sup>. The maxilla is a relatively soft and elastic bone compared with the mandible. Maxillary third molars therefore require less force to extract compared with mandibular third molars, and it is often possible to extract them without sectioning the teeth<sup>2</sup>. Because maxillary third molars are

anatomically close to the maxillary sinus, complications such as perforation of the maxillary sinus, postoperative maxillary sinusitis, oroantral fistula, and dislocation into the maxillary sinus may occur<sup>3-5</sup>. Few studies have addressed the complexity of removing maxillary third molars. Body mass index, tooth morphology, and surgical experience are associated with extraction time for maxillary third molars<sup>6</sup>. The proximity of the roots to the maxillary sinus is associated with increased difficulty<sup>7</sup>. The purpose of this study was to predict the radiological factors that can cause maxillary sinus complications during maxillary third-molar extraction.

## II. Materials and Methods

This study was a retrospective radiographic evaluation of patients who underwent maxillary third-molar extraction. Patients were admitted to the Department of Oral and Maxillofacial Surgery at Seoul National University Dental Hos-

---

### Soung Min Kim

*Department of Oral and Maxillofacial Surgery, Dental Research Institute, School of Dentistry, Seoul National University, 101 Daehak-ro, Jongno-gu, Seoul 03080, Korea*

TEL: +82-2-2072-0213

E-mail: [smin5@snu.ac.kr](mailto:smin5@snu.ac.kr)

ORCID: <https://orcid.org/0000-0002-6916-0489>

© This is an open-access article distributed under the terms of the Creative Commons Attribution Non-Commercial License (<http://creativecommons.org/licenses/by-nc/4.0/>), which permits unrestricted non-commercial use, distribution, and reproduction in any medium, provided the original work is properly cited.

Copyright © 2023 The Korean Association of Oral and Maxillofacial Surgeons.

pital between March 1, 2019, and December 31, 2021. All patients underwent preoperative panorama, a Waters view, and cone-beam computed tomography (CBCT). One week after surgical extraction, the patients were followed up with a postoperative panorama and Waters view. This study was conducted according to the guidelines of the Declaration of Helsinki and approved by the Institutional Review Board of Seoul National University (IRB No. S-D20220018).

### 1. Inclusion criteria

Patients who underwent surgical extraction of a maxillary third molar and received a preoperative panorama, CBCT, postoperative panorama, and Waters views were enrolled in the study.

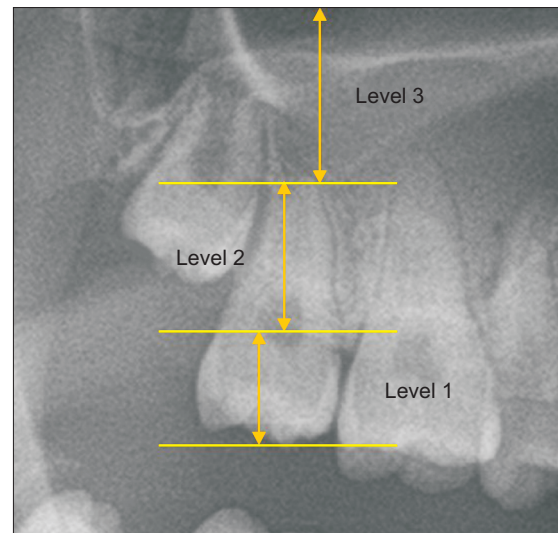
### 2. Exclusion criteria

Patients who did not complete follow-ups after extraction, those who had chronic sinusitis and allergic rhinosinusitis, and those younger than 16 years of age were excluded.

### 3. Methods

The objective was to identify the factors that affect the occurrence of postoperative radiographic swelling of the maxillary mucosa or air-fluid level after third-molar extraction. The following variables in medical records and radiographs were retrospectively reviewed and investigated: patient sex and age; panoramic findings such as depth of impaction (vertical position) and angulation of teeth; CBCT findings including inclination of teeth, number of roots, distance between the cemento-enamel junction (CEJ) and maxillary sinus floor, distance between root apex, and maxillary sinus floor.

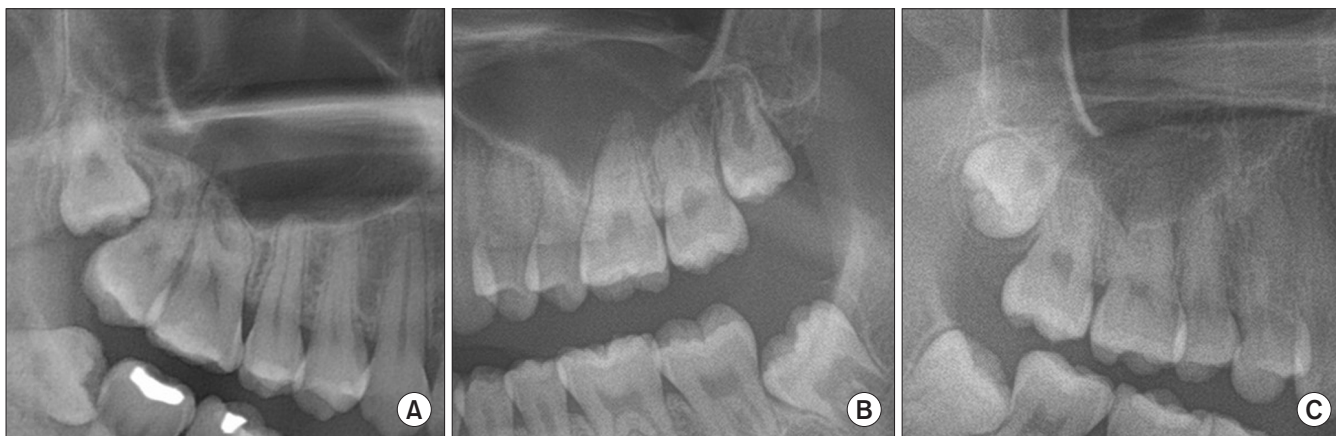
Extracted maxillary third molars were divided into two groups. Members of Group A had no postoperative abnormalities, either clinically or radiographically, and members of Group B had postoperative swelling of the maxillary mucosa or an air-fluid level in a Waters view. The sinus mucosa is not typically imaged radiographically, but in cases of inflammation the mucosa appears as a non-corticated radiopaque band along the floor and wall of the sinus<sup>8</sup>. Vertical position and tooth angle were evaluated on a preoperative panorama. If the occlusal surface was at the same level or below the CEJ of the maxillary second molar, it was classified as level 1.



**Fig. 1.** Vertical position of the maxillary third molar in the panoramic view. If the occlusal surface was at or below the cemento-enamel junction (CEJ) of the maxillary second molar, it was classified as level 1. If it was between the CEJ and the apex of the maxillary second molar, it was classified as level 2, and if it was above the apex, it was classified as level 3.

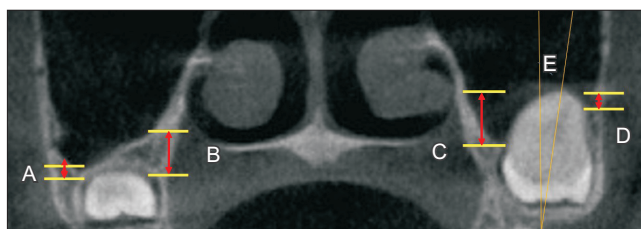
*Mi Hyun Seo et al: Radiographic evaluation before surgical extraction of impacted third molar to reduce the maxillary sinus related complication. J Korean Assoc Oral Maxillofac Surg 2023*

If the occlusal surface was located between the CEJ and the apex of the maxillary second molar, it was classified as level 2, and if it was located above the apex, it was classified as level 3.(Fig. 1) The angulations were classified as vertical, mesial, and distal according to the angle between the long axes of the maxillary third and second molars. Those with an angle difference between the two long axes of less than  $15^\circ$  were classified as vertical, those representing negative angles based on the long axes of the second molar were classified as mesial, and those representing positive angles were classified as distal.(Fig. 2) In CBCT, the number of roots and buccopalatal inclination of the long axis of the tooth in the coronal section were identified. Depending on the angle between the vertical line through the midpalate and the long axis of the tooth, inclination was divided into buccal, vertical, and palatal based on a threshold of  $15^\circ$ . Teeth presenting along the positive angle between the midline and long axis of the tooth were classified as buccal and teeth presenting on the negative angle were classified as palatal. On CBCT, the distance from the tooth to the floor of the maxillary sinus was measured, as was the shortest distance from the buccal and palatal sides of the CEJ and root apex to the floor of the maxillary sinus. When the root apex or CEJ was above the maxillary sinus floor, the distance was expressed as a negative value.(Fig. 3) Logistic regression was performed using IBM SPSS Statistics



**Fig. 2.** Angulation of the maxillary third molar. A. Mesial angulation. B. Vertical angulation. C. Distal angulation.

Mi Hyun Seo et al: Radiographic evaluation before surgical extraction of impacted third molar to reduce the maxillary sinus related complication. J Korean Assoc Oral Maxillofac Surg 2023



**Fig. 3.** Analysis of the maxillary third molar in a coronal section of cone-beam computed tomography. The distance from the tooth to the floor of the maxillary sinus was measured. The shortest distance from the buccal and palatal sides of the cemento-enamel junction (A, B) and root apex (C, D) to the floor of the maxillary sinus were measured. Depending on the angle between the vertical line passing through the midpalate and the long axis of the tooth, inclination was divided into buccal, vertical, and palatal (E).

Mi Hyun Seo et al: Radiographic evaluation before surgical extraction of impacted third molar to reduce the maxillary sinus related complication. J Korean Assoc Oral Maxillofac Surg 2023

(ver. 26.0; IBM) for statistical analysis, for which  $P < 0.05$  was considered statistically significant.

### III. Results

A total of 91 patients were included in this study, including 42 males and 49 females. The mean age was  $25.47 \pm 7.99$  years. The age distribution of patients is displayed in Table 1, with 9 patients aged 16 to 19 years, 69 patients in their 20s, 7 patients in their 30s, 3 patients in their 40s, and 3 patients 50 years or older. (Table 1) A total of 153 impacted maxillary third molars were included; 120 in Group A and 33 in Group B. In Group B, only 1 patient exhibited clinical postoperative sinusitis. Clinically, the symptoms of maxillary sinusitis were postoperative maxillary pain and swelling, nasal congestion, a runny nose, postnasal drip, and a foul odor. In most

**Table 1.** Demographic data (n=91)

Patients	Value
Sex	
Male	42
Female	49
Age (yr)	$25.47 \pm 7.99$
16-19	9
20-29	69
30-39	7
40-49	3
$\geq 50$	3

Values are presented as number only or mean  $\pm$  standard deviation.

Mi Hyun Seo et al: Radiographic evaluation before surgical extraction of impacted third molar to reduce the maxillary sinus related complication. J Korean Assoc Oral Maxillofac Surg 2023

cases, postoperative swelling of the maxillary sinus mucosa or air-fluid level was shown on a radiograph without clinical symptoms. The results of radiographic evaluations using panoramas and CBCTs are described in Table 2. In the vertical position, 67 teeth (43.8%), 85 teeth (55.6%), and 1 tooth (0.7%) were in the level 1, 2, and 3 categories, respectively. For angulations, 57 teeth (37.3%), 62 teeth (40.5%), and 34 teeth (22.2%) exhibited mesial, vertical, and distal angulations, respectively. For the number of roots, 73 teeth (47.7%), 23 teeth (15.0%), 53 teeth (34.6%), and 4 teeth (2.6%), exhibited 1, 2, 3, and 4 roots, respectively in the coronal section, with 88 teeth (57.5%), 38 teeth (24.8%), and 27 teeth (17.6%) exhibiting buccal, vertical, and palatal inclinations, respectively.

Age and distance between the palatal CEJ and maxillary sinus floor were statistically significantly associated with postoperative maxillary sinus mucosa swelling or haziness after surgical extraction. (Table 3)

**Table 2.** Radiographic evaluation of impacted maxillary third molars (n=153)

Variable	Value
Vertical position	
Level 1	67 (43.8)
Level 2	85 (55.6)
Level 3	1 (0.7)
Angulation	
Mesial	57 (37.3)
Vertical	62 (40.5)
Distal	34 (22.2)
No. of roots	
1	73 (47.7)
2	23 (15.0)
3	53 (34.6)
4	4 (2.6)
Inclination	
Buccal	88 (57.5)
Vertical	38 (24.8)
Palatal	27 (17.6)

Values are presented as number (%).

Mi Hyun Seo et al: Radiographic evaluation before surgical extraction of impacted third molar to reduce the maxillary sinus related complication. *J Korean Assoc Oral Maxillofac Surg* 2023

#### IV. Discussion

The maxillary sinus is the largest and first paranasal sinus to develop, and its development is completed with the eruption of the third molar<sup>2</sup>. The floor of the maxillary sinus is formed from the alveolar process of the maxilla. The volume of the maxillary sinuses changes with growth, eruption, and extraction of maxillary teeth<sup>9</sup>.

In general, maxillary third-molar extraction causes fewer postoperative complications compared with mandibular third-molar extraction<sup>10</sup>. However, surgical extraction of maxillary third molars can be a causative factor in odontogenic maxillary sinusitis because of the anatomic relationship. The selection of an appropriate surgical procedure should be based on preoperative evaluation of the morphology and anatomical relationship with adjacent structures<sup>11</sup>. Lim et al.<sup>12</sup> reported that the depth of impaction of the maxillary third molar is a possible predictor of oroantral perforation. Rothamel et al.<sup>1</sup>, who studied the incidence and predictive factors of perforation of the maxillary sinus in surgical extraction, reported that an intraoperative root fracture, higher degree of impaction, and older patient age were associated with oroantral perforation. The present study produced similar results. As most maxillary third molars are removed by luxation without odontomy, we hypothesized that the factors that increase the difficulty of extraction may also increase the possibility of maxillary sinusitis. Statistically significant differences in sex and depth of impaction were evident in postoperative X-rays of

**Table 3.** Predictive values for postoperative maxillary sinus mucosa swelling or haziness

	Exp ( $\beta$ )	CI	P-value
Sex (0: male, 1: female)	0.388	0.149-1.010	0.052
Age	1.082	1.011-1.157	0.022*
Vertical position	1.608	0.535-4.838	0.398
Angulation	1.621	0.805-3.265	0.176
No. of roots	1.097	0.660-1.825	0.721
Buccopalatal inclination	1.504	0.778-2.905	0.225
Distance between sinus and CEJ (B)	0.976	0.803-1.185	0.805
Distance between sinus and CEJ (P)	0.789	0.635-0.982	0.033*
Distance between sinus and apex (B)	0.800	0.601-1.065	0.126
Distance between sinus and apex (P)	1.140	0.908-1.430	0.259

(CEJ: cemento enamel junction, B: buccal, P: palatal, Exp ( $\beta$ ): exponentiated coefficient, CI: confidence interval)

\*P<0.05.

Mi Hyun Seo et al: Radiographic evaluation before surgical extraction of impacted third molar to reduce the maxillary sinus related complication. *J Korean Assoc Oral Maxillofac Surg* 2023

the groups with and without mucosal thickening. Previous studies on the anatomical relationship between maxillary teeth and sinuses have focused on the position of the root apex<sup>13,14</sup>.

In this study, we explored whether there was a difference between the two experimental groups in the positional relationships between the root apex and maxillary sinus floor and between the CEJ and maxillary sinus floor. There were statistically significant differences in the positional relationship between the CEJ and maxillary sinus but none in the location of the root apex in relation to the sinus floor. Age was also found to be related to maxillary sinus changes after surgical extraction. As a patient ages, bone resilience decreases, and maxillary tuberosity fracture can be treated by surgical extraction<sup>15</sup>. There were no significant relationships with postoperative radiographic maxillary sinus changes in variables such as sex, depth, tooth direction, or number of roots. As a result, we determined that the relationship of the CEJ and the sinus floor was likely to affect the maxillary sinus mucosa. Because the CEJ is close to the sinus floor, caution is required when luxating the tooth with an elevator to avoid iatrogenic maxillary sinusitis.

A limitation of this study was that, due to the small sample size, the proportion of patients who developed clinical sinusitis was small. Additional studies involving a large number of patients with radiographic postoperative maxillary mucosal swelling or air-fluid level are needed.

## V. Conclusion

Maxillary third molars are anatomically adjacent to the maxillary sinus and require careful extraction. When the maxillary sinus is pneumatized to the CEJ, swelling of the maxillary sinus mucosa often appears after surgery. If patients are old or if the sinus floor and CEJ of tooth are too close, the possibility of postoperative maxillary sinusitis is high.

## ORCID

Mi Hyun Seo, <https://orcid.org/0000-0001-8220-6480>

Buyanbileg Sodnom-Ish, <https://orcid.org/0000-0002-4239-1420>

Mi Young Eo, <https://orcid.org/0000-0001-7055-9924>

Hoon Myoung, <https://orcid.org/0000-0002-9984-8479>

Soung Min Kim, <https://orcid.org/0000-0002-6916-0489>

## Authors' Contributions

M.H.S. conceptualized the study and wrote the manuscript. B.S.-I. contributed to the manuscript preparation and manuscript editing. M.Y.E. corrected data and wrote the manuscript. H.M. revised the manuscript. S.M.K. designed the study and coordinated and carefully reviewed and revised the manuscript. All authors have read and agreed to the published version of the manuscript.

## Funding

This research was supported by grant No. 08-2021-0013 from the SNU DH Research Fund and the Basic Science Research Program administered through the National Research Foundation of Korea (NRF) funded by the Ministry of Education (2021R111A1A01058939).

## Ethics Approval and Consent to Participate

This retrospective data analysis was approved by the Institutional Review Board of Seoul National University (IRB No. S-D20220018) and all methods were performed in accordance with the relevant guidelines and regulations of the Declaration of Helsinki. Consent for publication was obtained from all participants.

## Conflict of Interest

No potential conflict of interest relevant to this article was reported.

## References

- Rothamel D, Wahl G, d'Hoedt B, Nentwig GH, Schwarz F, Becker J. Incidence and predictive factors for perforation of the maxillary antrum in operations to remove upper wisdom teeth: prospective multicentre study. *Br J Oral Maxillofac Surg* 2007;45:387-91. <https://doi.org/10.1016/j.bjoms.2006.10.013>
- Yurdabakan ZZ, Okumus O, Pekiner FN. Evaluation of the maxillary third molars and maxillary sinus using cone-beam computed tomography. *Niger J Clin Pract* 2018;21:1050-8. [https://doi.org/10.4103/njcp.njcp\\_420\\_17](https://doi.org/10.4103/njcp.njcp_420_17)
- Lee D, Ishii S, Yakushiji N. Displacement of maxillary third molar into the lateral pharyngeal space. *J Oral Maxillofac Surg* 2013;71:1653-7. <https://doi.org/10.1016/j.joms.2013.05.018>
- Kocaelli H, Balcioglu HA, Erdem TL. Displacement of a maxillary third molar into the buccal space: anatomical implications apropos of a case. *Int J Oral Maxillofac Surg* 2011;40:650-3. <https://doi.org/10.1016/j.ijom.2010.11.021>
- Bilginaylar K. The use of platelet-rich fibrin for immediate closure of acute oroantral communications: an alternative approach. *J Oral Maxillofac Surg* 2018;76:278-86. <https://doi.org/10.1016/j.joms.2017.07.168>
- Susarla SM, Dodson TB. Predicting third molar surgery operative time: a validated model. *J Oral Maxillofac Surg* 2013;71:5-13. <https://doi.org/10.1016/j.joms.2012.08.004>
- de Carvalho RW, de Araújo Filho RC, do Egito Vasconcelos BC. Assessment of factors associated with surgical difficulty during removal of impacted maxillary third molars. *J Oral Maxillofac Surg* 2013;71:839-45. <https://doi.org/10.1016/j.joms.2013.01.001>
- Bisla S, Gupta A, Singh H, Sehrawat A, Shukla S. Evaluation of relationship between odontogenic infections and maxillary sinus changes: a cone beam computed tomography-based study. *J Oral Biol Craniofac Res* 2022;12:645-50. <https://doi.org/10.1016/j.jobcr.2022.08.001>
- Asaumi R, Sato I, Miwa Y, Imura K, Sunohara M, Kawai T, et al. Understanding the formation of maxillary sinus in Japanese human fetuses using cone beam CT. *Surg Radiol Anat* 2010;32:745-51. <https://doi.org/10.1007/s00276-010-0678-5>
- Bui CH, Seldin EB, Dodson TB. Types, frequencies, and risk factors for complications after third molar extraction. *J Oral Maxillofac Surg* 2003;61:1379-89. <https://doi.org/10.1016/j.joms.2003.04.001>
- de Andrade PF, Silva JNN, Sotto-Maior BS, Ribeiro CG, Devito KL, Assis NMSP. Three-dimensional analysis of impacted maxillary third molars: a cone-beam computed tomographic study of the position and depth of impaction. *Imaging Sci Dent* 2017;47:149-55. <https://doi.org/10.5624/isd.2017.47.3.149>
- Lim AA, Wong CW, Allen JC Jr. Maxillary third molar: patterns of impaction and their relation to oroantral perforation. *J Oral Maxillofac Surg* 2012;70:1035-9. <https://doi.org/10.1016/j.joms.2012.01.032>
- Kilic C, Kamburoglu K, Yuksel SP, Ozen T. An assessment of the relationship between the maxillary sinus floor and the maxillary posterior teeth root tips using dental cone-beam computerized tomography. *Eur J Dent* 2010;4:462-7.
- Sharan A, Madjar D. Correlation between maxillary sinus floor topography and related root position of posterior teeth using panoramic and cross-sectional computed tomography imaging. *Oral Surg Oral Med Oral Pathol Oral Radiol Endod* 2006;102:375-81.

- <https://doi.org/10.1016/j.tripleo.2005.09.031>
15. Shmuly T, Winocur-Arias O, Kahn A, Findler M, Adam I. Maxillary tuberosity fractures following third molar extraction, prevalence, and risk factors. *J Craniofac Surg* 2022;33:e708-12. <https://doi.org/10.1097/scs.00000000000008654>

**How to cite this article:** Seo MH, Sodnom-Ish B, Eo MY, Myoung H, Kim SM. Radiographic evaluation before surgical extraction of impacted third molar to reduce the maxillary sinus related complication. *J Korean Assoc Oral Maxillofac Surg* 2023;49:192-197. <https://doi.org/10.5125/jkaoms.2023.49.4.192>