



# Midline cleft of the upper lip associated with a microform unilateral cleft and a proboscis-like structure: a case report

Adekunle Moses Adetayo<sup>1,2</sup>, Olukayode Adebola Yusuf<sup>1</sup>, Chika Precious Ibeh<sup>2</sup>, Eyinnaya Ukaegbu<sup>2</sup>,  
Fadkemi Oginni<sup>3</sup>, Modupe Olusola Adetayo<sup>4</sup>

<sup>1</sup>Department of Surgery, Benjamin Carson Snr School of Medicine, Babcock University,

<sup>2</sup>Dental Unit, Babcock University Teaching Hospital, Ilishan-Remo, <sup>3</sup>Department of Oral and Maxillofacial Surgery, Obafemi Awolowo University, Ile-Ife, <sup>4</sup>Department of Biochemistry, Babcock University, Ilishan-Remo, Nigeria

**Abstract** (J Korean Assoc Oral Maxillofac Surg 2023;49:223-227)

A midline or median cleft lip is rare, and a midline cleft associated with a unilateral cleft and a proboscis-like structure is rarer still. We present a case managed at our center in which a 5-year-old male had a median cleft of the upper lip with an associated ‘proboscis’ and a microform unilateral cleft lip.

**Key words:** Midline cleft, Atypical cleft, Cutaneous mass

[paper submitted 2022. 7. 13 / revised 2022. 8. 19 / accepted 2022. 8. 26]

## I. Introduction

A midline or median cleft lip is rare, with an incidence amongst cleft patients of only 0.43% to 0.73%<sup>1,2</sup>. It was initially presumed to arise from a failure of fusion between the medial nasal prominences; however, further study and observation in rats showed that it might be due to a failure of mesenchymal migration<sup>3</sup>.

In his widely adopted facial cleft classification, Tessier<sup>4</sup> put a midline cleft of the upper lip in the 0 group, whereas the 5-type surgical classification proposed by Fearon<sup>5</sup> has a midline cleft of the lip as type 1. The midline cleft is unique because it is the only type with two subtypes: a subtype with a deficiency in the midline structures, also called a pseudo median cleft, and a subtype with an excess of midline structures that is called a true median cleft<sup>2</sup>. True median cleft lips are presumed to result from a failure of fusion between the

median nasal processes, and the pseudo type is understood to result from a lack or insufficiency of the tissue that contribute to the formation of the midline structure<sup>2,6</sup>. There is still, however, no consensus on this classification.

The true median cleft, although presumed not to be associated with brain deformities, is associated with intraoral and extraoral soft tissue masses<sup>7,8</sup>, upper lip sinuses<sup>9</sup>, and cutaneous facial polyps<sup>10</sup>. To the best of our knowledge, the association of a proboscis-like structure with a median cleft and the coexistence of an upper median cleft with a unilateral upper cleft lip has not been discussed in the literature. We present a case managed in our center in which a 5-year-old male had a true median cleft of the upper lip associated with a microform unilateral cleft.

## II. Case Report

The 5-year-old male patient, yet to commence formal education, presented in the company of his mother. The mother received routine antenatal clinic care before his delivery. The pregnancy was full-term and uneventful. The mother said that she did not smoke, drink alcohol, or be exposed to any environmental risk factors for orofacial clefts during pregnancy. There was no family history of clefts. She married into a polygamous family with a lot of rancor and infighting. No other history concerning the child or his family was significant.

**Adekunle Moses Adetayo**

Department of Surgery, Babcock University, PMB 4003, Ilishan-Remo 121103, Nigeria

TEL: +234-8038337845

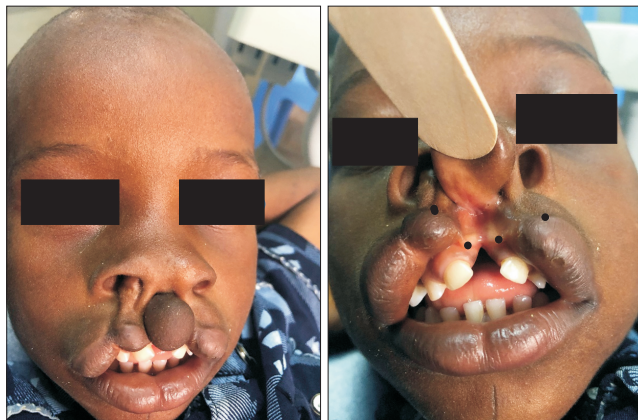
E-mail: [adetayo@babcock.edu.ng](mailto:adetayo@babcock.edu.ng)

ORCID: <https://orcid.org/0000-0002-7318-0810>

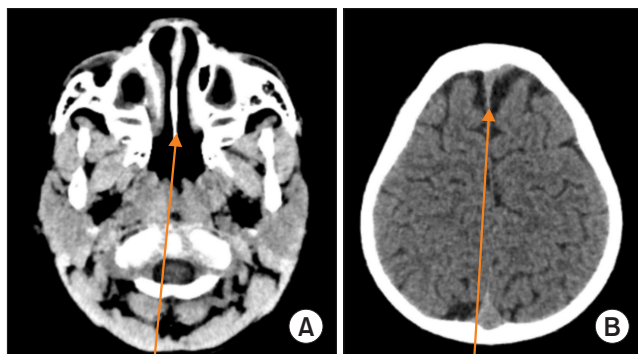
© This is an open-access article distributed under the terms of the Creative Commons Attribution Non-Commercial License (<http://creativecommons.org/licenses/by-nc/4.0/>), which permits unrestricted non-commercial use, distribution, and reproduction in any medium, provided the original work is properly cited.

Copyright © 2023 The Korean Association of Oral and Maxillofacial Surgeons.

On examination, the patient weighed 20 kg and demonstrated good intellect. Limbs, genitals, abdomen, and chest were clinically normal. There was a complete midline cleft of the upper lip and a right microform cleft of the upper lip. The midline cleft extended into the vermillion, white roll, the philtrum, and up into the columella, splitting them into two halves. Between the two halves of the columella, the base of a balloon-like tissue was attached, the proboscis, composed of skin externally and labial mucosa internally. The width of the cleft was 2.5 cm. The intercanthal distance was normal



**Fig. 1.** Preoperative clinical photographs showing the midline and microform cleft lip, bifid columella, and bifid frenula. Adekanle Moses Adetayo et al: Midline cleft of the upper lip associated with a microform unilateral cleft and a proboscis-like structure: a case report. J Korean Assoc Oral Maxillofac Surg 2023



CT showing the falx cerebri, which is absent in a false median cleft of the upper lip.

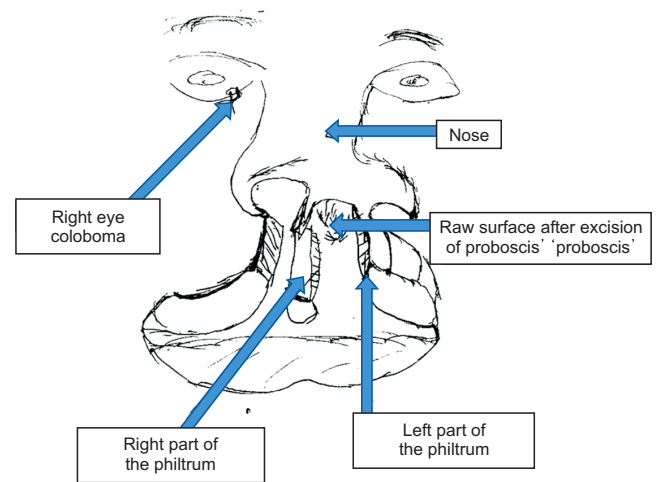
CT showing the nasal septum, which is normally absent in a false median cleft of the upper lip.

**Fig. 2.** A, B. Computerized tomography (CT) showing the nasal septum and falx cerebri in the patient with a true median cleft of the upper lip. These structures are absent in false median clefts. Adekanle Moses Adetayo et al: Midline cleft of the upper lip associated with a microform unilateral cleft and a proboscis-like structure: a case report. J Korean Assoc Oral Maxillofac Surg 2023

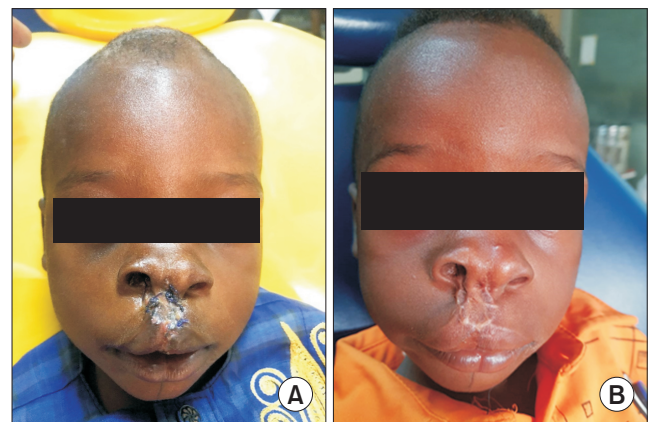(35 mm). Intraorally, there were two upper labial frenula followed by an extension of the cleft into the upper alveolus. There was also a coloboma of the right eye with a medial defect of the lower eyelid.(Fig. 1) Computerized tomography of the brain showed that the nasal septum, falx cerebri, frontal bones, cranial vault, corpus callosum, and other intracranial structures were intact.(Fig. 2)

The patient was prepared for primary cheilorrhaphy, but the family was unable to pay for surgery until a charity foundation paid for the treatment.

Surgery was done under general anesthesia (endotracheal intubation). The first step was to excise the proboscis at the base of the columella, which resulted in a midline cleft lip



**Fig. 3.** Schematic diagram showing the patient's face and intraoperative procedures. Adekanle Moses Adetayo et al: Midline cleft of the upper lip associated with a microform unilateral cleft and a proboscis-like structure: a case report. J Korean Assoc Oral Maxillofac Surg 2023



**Fig. 4.** Postoperative clinical photographs. A. Two-week follow-up. B. 24-week follow-up. Adekanle Moses Adetayo et al: Midline cleft of the upper lip associated with a microform unilateral cleft and a proboscis-like structure: a case report. J Korean Assoc Oral Maxillofac Surg 2023

and a right microform unilateral cleft lip. A full thickness skin graft was taken from the part of the lip between the midline and right microform clefts and fashioned with a medial curvilinear edge, so that a philtrum could be formed, together with the remnant philtrum on the medial segment.

The microform unilateral cleft was converted into a complete one, and the residual tissue from which the full thickness skin had been lifted was excised and discarded. Two opposing C-shaped incisions were made into the two cleft parts of the columella, and a corresponding piece of tissue comprising skin and subcutaneous tissue was removed from the two parts to reduce the width of the columella. (Fig. 3) Markings were then made for a Millard rotation advancement repair. Separation of the orbicularis oris from the skin and oral mucosa at the edges of the cleft was done with a No. 15 scalpel blade. The skin-philtrum flap was sutured, positioning it to form the remaining part of the cupid's bow, and then the orbicularis oris muscle was repaired to achieve its continuity. Closure was attained through intraoral and extra-oral suturing. An attempt was made to repair the cartilage of the columella by freeing it and bringing it together. Unfortunately, the patient disturbed the healing by repeated traumatic touch, which led to a breakdown, with subsequent migration and rewidening of the nose. (Fig. 4) He is now being worked up for a revisional surgery to reduce the columella width and excise the hypertrophic scar that developed postoperatively.

### III. Discussion

A median cleft is defined as a vertical cleft through the center of the upper lip. This condition is rare, and the scientific world is still trying to gather data on the possible etiopathogenesis and clinical features associated with it<sup>2,11</sup>. The present case of a midline cleft of the upper lip with a right microform cleft of the upper lip is a true median cleft of the upper lip. A duplicated upper labial frenulum, duplicated nasal septum, and wide diastema of the upper incisors are the criteria stated by Ichida et al.<sup>2</sup> and re-echoed in Jain<sup>12</sup> that must be present in a true median cleft. These structures become duplicated as a result of the midline cleft. The false median cleft is regarded as arhinencephaly by Kundrat<sup>13</sup> and as holotelencephaly<sup>2</sup> and a component of holoprosencephaly by DeMyer et al.<sup>14</sup>. This suggests that the etiopathogenesis of this category of cleft is still largely unclear, but it has been traced to the third week of intrauterine life, when failure of fusion or merging of the median nasal prominences caused by reduced mesodermal in-growth results in a median cleft, as observed in rats<sup>6,15</sup>.

The presence of a microform unilateral cleft compounds the possible etiopathogenesis of this case. Mazzola<sup>16</sup> stated that the upper lip is formed from the fusion of the medial and lateral nasal prominences and the medial aspect of the maxillary process. Thus, this unilateral cleft might result from a failure of fusion between the maxillary process and lateral nasal prominence or between the lateral and median nasal prominences.

James et al.<sup>17</sup> found craniofacial clefts to be commoner on the right sides and in male persons. In line with this, the right-sided microform cleft lip and the presence of a coloboma of the right eye in this case suggest that the cleft on the right is a craniofacial cleft. The implication of the microform unilateral cleft in this case is that the previously described techniques<sup>1,2,5</sup> for median cleft lip repair would not (and did not) suffice. The initial challenge in this case was creating a philtrum. However, knowing that in clefts, especially unilateral clefts, most of the tissues are present but displaced<sup>18</sup>, we looked and found the remaining philtral half attached to the medial edge of the unilateral microform cleft lip. The curvilinear edge of the philtral flap allowed us to make a curvilinear repair, ensuring that the resulting scar simulates the philtral ridge. This technique for median cleft repair is similar to the one advocated by Millard and Williams<sup>1</sup> and used by James et al.<sup>17</sup>. The excess tissue, including the proboscis-like structure<sup>7</sup>, was excised to allow the cleft edges to approximate a linear or curvilinear shape<sup>1,17</sup>. A technique involving wide and extensive dissection of nasal cartilage and the incorporation of z-plasty near the vermilion in a median cleft that looked like the one presented in this report was described by Kolker et al.<sup>19</sup>. The drawback of that technique, as pointed out by Millard and Williams<sup>1</sup>, is the retardation of nasal growth caused by the extensive nasal dissection. Jian et al.<sup>20</sup> described a 'proportioned' technique with markings and numbers that incorporated z-plasty to get adequate lip height and width. Unsightly scars have, however, been documented as complications of repair with z-plasty<sup>18</sup>. Our use of the Millard rotational advancement repair for this case offered flexibility, and the repair produced symmetrical lip height and width in a subjective assessment<sup>1</sup>. The columella, however, is still relatively large, despite our attempt to narrow it. Therefore, a revisional surgery is being planned to reposition the alar cartilage and correct the patient's columella widening. Financial challenge remains the main obstacle. While we await additional financial support, the patient is being reviewed every 3 months pending revision surgery.

In summary, a midline cleft of the upper lip is rare, and the

clinical features associated with it are still being gathered. The techniques used for surgical repair will obviously depend on the phenotype. Thus, it is important to develop an array of techniques, rather than a one-size-fits-all approach, as seen in the case presented here.

## ORCID

Adekunle Moses Adetayo, <https://orcid.org/0000-0002-7318-0810>

Olukayode Adebola Yusuf, <https://orcid.org/0000-0002-8201-3678>

Chika Precious Ibeh, <https://orcid.org/0009-0000-7387-7549>

Eyinnaya Ukaegbu, <https://orcid.org/0000-0003-3886-590X>

Fadekemi Oginni, <https://orcid.org/0000-0002-7297-1055>

Modupe Olusola Adetayo, <https://orcid.org/0000-0001-6507-3436>

## Authors' Contributions

A.M.A. was involved in conception, data collection, writing and proofreading of the manuscript. O.A.Y. was involved in conception, data collection, writing and proofreading of the manuscript. F.O. was involved in writing and proofreading of the manuscript. E.U. in writing and proofreading of the manuscript. C.P.I. involved in data collection and writing of the manuscript. M.O.A. was involved in writing and proofreading of the manuscript.

## Funding

No funding to declare.

## Acknowledgements

Our appreciation goes to the staff of the Dental Unit and Main Theatre, Babcock University Teaching Hospital, for their support and preparation of this patient before, during, and after surgery. We also would like to thank the Happy Child Foundation for paying for this patient's surgery.

## Consent for Publishing Photographs

Written informed consent was obtained from the patient's

legal guardian for publication of this article and accompanying images.

## Conflict of Interest

No potential conflict of interest relevant to this article was reported.

## References

1. Millard DR Jr, Williams S. Median lip clefts of the upper lip. *Plast Reconstr Surg* 1968;42:4-14.
2. Ichida M, Komuro Y, Yanai A. Consideration of median cleft lip with frenulum labii superior. *J Craniofac Surg* 2009;20:1370-4. <https://doi.org/10.1097/scs.0b013e3181ae42bf>
3. de Boutray M, Beziat JL, Yachouh J, Bigorre M, Gleizal A, Captier G. Median cleft of the upper lip: a new classification to guide treatment decisions. *J Craniofac Surg* 2016;44:664-71. <https://doi.org/10.1016/j.jcms.2016.02.012>
4. Tessier P. Anatomical classification facial, cranio-facial and latero-facial clefts. *J Maxillofac Surg* 1976;4:69-92. [https://doi.org/10.1016/s0301-0503\(76\)80013-6](https://doi.org/10.1016/s0301-0503(76)80013-6)
5. Fearon JA. Rare craniofacial clefts: a surgical classification. *J Craniofac Surg* 2008;19:110-2. <https://doi.org/10.1097/scs.0b013e31815ca1ba>
6. Tange I. [12 Cases of median cleft lip]. *Jpn J Plast Reconstr Surg* 1965;8:118-31. Japanese.
7. Nakamura J, Tomonari H, Goto S. True median cleft of the upper lip associated with three pedunculated club-shaped skin masses. *Plast Reconstr Surg* 1985;75:727-31. <https://doi.org/10.1097/00006534-198505000-00022>
8. Casseler F, Radovich F, Ubiglia GP, Guidetti F. [A case report of a true median cleft of the upper lip with a pedunculated median skin-mucosa mass]. *Minerva Stomatol* 1991;40:505-8. Italian.
9. Kün-Darbois JD, Chatellier A, Paré A, Caillot A, Ambroise B, Bénateau H, et al. Congenital midline upper lip sinuses: 3 rare cases. *Cleft Palate Craniofac J* 2018;55:292-5. <https://doi.org/10.1177/1055665617723635>
10. Pai GS, Levkoff AH, Leithiser RE Jr. Median cleft of the upper lip associated with lipomas of the central nervous system and cutaneous polyps. *Am J Med Genet* 1987;26:921-4. <https://doi.org/10.1002/ajmg.1320260421>
11. Moore MH. Rare craniofacial clefts. *J Craniofac Surg* 1996;7:408-11. <https://doi.org/10.1097/00001665-199611000-00003>
12. Jain S. True median cleft of upper lip: review of anatomic changes and surgical management. *J Appl Dent Med Sci* 2017;3:74-81.
13. Kundrat H. [Arhinencephalie als typische Art von Missbildung]. *Leuschner & Lubensky*; 1882. German.
14. DeMyer W, Zeman W, Palmer CG. The face predicts the brain: diagnostic significance of median facial anomalies for holoprosencephaly (arhinencephaly). *Pediatrics* 1964;34:256-63.
15. Patel NP, Tantri MD. Median cleft of the upper lip: a rare case. *Cleft Palate Craniofac J* 2010;47:642-4. <https://doi.org/10.1597/09-065>
16. Mazzola RF. Congenital malformations in the frontonasal area: their pathogenesis and classification. *Clin Plast Surg* 1976;3:573-609.
17. James O, Sabo VY, Adamson OO, Otoghile B, Adekunle AA, Adeyemo WL, et al. Presentation and management of atypical orofacial clefts: a single-institution experience for 13 year period. *Cleft Palate Craniofac J* 2023;60:133-41. <https://doi.org/10.1177/10556656211055012>
18. Markus AF, Delaire J, Smith WP. Facial balance in cleft lip and

- palate. II. Cleft lip and palate and secondary deformities. *Br J Oral Maxillofac Surg* 1992;30:296-304. [https://doi.org/10.1016/0266-4356\(92\)90179-m](https://doi.org/10.1016/0266-4356(92)90179-m)
19. Kolker AR, Sailon AM, Meara JG, Holmes AD. Midline cleft lip and bifid nose deformity: description, classification, and treatment. *J Craniofac Surg* 2015;26:2304-8. <https://doi.org/10.1097/scs.0000000000002229>
  20. Jian XC, Zheng L, Xu P, Liu DY. Median cleft of the upper lip associated with a mass: a rare case. *J Craniomaxillofac Surg* 2014;42:1557-61. <https://doi.org/10.1016/j.jcms.2014.01.003>

**How to cite this article:** Adetayo AM, Yusuf OA, Ibeh CP, Ukaegbu E, Oginni F, Adetayo MO. Midline cleft of the upper lip associated with a microform unilateral cleft and a proboscis-like structure: a case report. *J Korean Assoc Oral Maxillofac Surg* 2023;49:223-227. <https://doi.org/10.5125/jkaoms.2023.49.4.223>