



Mandibular metastasis of papillary thyroid carcinoma: a case report and systematic literature review

Yootaek Shin¹, Hyounmin Kim¹, Solbin Yang¹, Seung-Yong Han², Eunae Sandra Cho²,
Dongwook Kim¹, Hyung Jun Kim¹

Departments of¹Oral and Maxillofacial Surgery and²Oral Pathology, Yonsei University College of Dentistry, Seoul, Korea

Abstract (J Korean Assoc Oral Maxillofac Surg 2025;51:73-79)

In this paper, we systematically review the literature on papillary thyroid carcinoma (PTC) metastasis to the mandible. This is a rare occurrence, especially in young, asymptomatic patients. We propose appropriate surgical and adjuvant therapy guidelines based on our findings. A systematic PubMed search (up to July 2023) identified 10 eligible cases of papillary or follicular thyroid carcinoma with metastasis to the mandible. Studies of patients with different histologic types or without confirmed distant metastasis were excluded. A rare case of PTC metastasizing to the mandible in a young male highlights an unusual presentation. Surgical treatment of both primary and metastatic sites, along with aggressive adjuvant therapy after surgery, had a positive impact on survival.

Key words: Thyroid neoplasm, Papillary carcinoma, Neoplasm metastasis, Mandible

[paper submitted 2024. 11. 11 / revised 2024. 12. 6 / accepted 2024. 12. 11]

I. Introduction

Distant metastasis of malignant tumors to the jawbone region is rare, accounting for approximately 1% of all malignant tumors occurring in the jawbone¹. The primary sites are the lung, breast, and prostate, with the thyroid accounting for approximately 6%^{2,3}. Papillary thyroid carcinoma (PTC) accounts for approximately 80% of thyroid malignancies and metastasizes primarily by lymphatic invasion to nearby lymph nodes^{4,5}. However, it does not metastasize as frequently as follicular thyroid carcinoma (FTC)⁵. In this paper, we report a rare case of PTC metastasizing to the mandible and cervical lymph nodes and propose optimal treatments for thyroid diseases metastasizing to the jawbone as discovered through a review of the literature.

Hyung Jun Kim

Department of Oral and Maxillofacial Surgery, Yonsei University College of Dentistry, 50-1 Yonsei-ro, Seodaemun-gu, Seoul 03722, Korea

TEL: +82-2-2228-3138

E-mail: KIMOMS@yuhs.ac

ORCID: <https://orcid.org/0000-0001-8247-4004>

© This is an open-access article distributed under the terms of the Creative Commons Attribution Non-Commercial License (<http://creativecommons.org/licenses/by-nc/4.0/>), which permits unrestricted non-commercial use, distribution, and reproduction in any medium, provided the original work is properly cited.

© 2025 The Korean Association of Oral and Maxillofacial Surgeons.

II. Materials and Methods

A systematic literature review was conducted to identify similar cases. PubMed (up to July 2023) was searched using the following keywords: [(papillary thyroid carcinoma) or (follicular thyroid carcinoma) and (mandible)].

Studies were excluded if the primary thyroid lesion was of a different histologic type than the present case or if the histologic type of the lesion could not be confirmed. In addition, cases were excluded if they involved malignant tumors of the thyroid and jawbone but did not involve distant metastasis to the jawbone.

All identified relevant articles were examined independently by two investigators (Y.S. and H.K.). Upon encountering discrepancies, the two reviewers (Y.S. and H.K.) engaged in a collaborative discussion and analyzed the data together. Only eligible full-text studies were included, and additional relevant studies cited within the selected papers were reviewed. A total of 10 cases reported in 10 studies were analyzed. (Table 1)

Table 1. Literature review of all cases of mandibular metastases from papillary thyroid carcinoma

Study	Age (yr)/sex	Symptom	Previous thyroid cancer history	Type of thyroid carcinoma	Location of mandibular metastasis	Nodal metastasis	Metastasis to other organ	Treatment
Colella et al. ⁷ (2003)	50/F	Swelling (RMT, Rt.) Pain	Lobectomy Isthmectomy (5 years prior)	PTC	Ramus, Rt.	Level IB	NR	NR
Liu et al. ¹⁷ (2007)	66/M	Swelling (cheek, Lt.)	Thyroidectomy (22 years prior)	FVPTC	Ramus, Lt.	NR	Scapula	Radical resection of the mandibular tumor RAI Segmental mandibulectomy Thyroidectomy
Kumar et al. ¹⁸ (2010)	58/F	Swelling (mandible, Lt.)	None	FVPTC	Canine to angle	NR	NR	RAI Segmental mandibulectomy Thyroidectomy Midline neck dissection RAI Hemi mandibulectomy RAI
Bingol et al. ¹⁰ (2015)	33/F	Swelling (mandible, Rt.)	Thyroid gland surgery (20 years prior)	FVPTC	Angle (6x5x3 cm ³)	NR	Pelvis Humerus Multisystem NR	Segmental mandibulectomy Thyroidectomy Hemi mandibulectomy mRND, Rt. Palliative en-bloc resection
Anajar et al. ¹² (2017)	52/F	Swelling (mandible, Lt.)	None	PTC	Angle to ramus, Lt.	None	NR	Segmental mandibulectomy
Khoostezani et al. ¹⁶ (2019)	68/M	Swelling (mandible, Rt.)	None	PTC	Angle to ramus, Rt.	Multiple (level NR)	None	Thyroidectomy Hemi mandibulectomy
Gholami et al. ¹⁹ (2020)	56/F	Swelling (mandible, Lt.) Pain Unhealed extraction socket Numb-chin syndrome	None	PTC	Premolar, Lt. to incisor, Rt.	Multiple (level NR)	Rib, Rt. Iliac, Rt. Hip, Rt.	Palliative en-bloc resection
Wareing et al. ⁸ (2021)	68/M	Swelling (cheek, Rt.)	None	PTC	Body to condyle, Rt. (6x5.5x4.5 cm ³)	Bilateral level I, II	Rib Lumbar Vertebra None	Thyroidectomy Palliative RAI
Wahyono et al. ¹¹ (2022)	54/F	Swelling (mandible, Lt.) Pain Sense alteration	None	FVTPC	Body to angle, Lt. (5.9x5.3x5.0 cm ³)	None	None	Hemi mandibulectomy Thyroidectomy
Raffaelli et al. ²⁰ (2023)	77/M	Malocclusion Swelling (mandible, Lt.) Hypoesthesia	Thyroidectomy RAI (pT2NxM0, 5 years prior)	PTC	Angle to ramus, Lt.	NR	None	Segmental mandibulectomy Adjuvant radiation

(M: male, F: female, RMT: retromolar triagone, Rt.: right, Lt.: left, NR: not reported, FVPTC: follicular variant papillary thyroid carcinoma, PTC: papillary thyroid carcinoma, RAI: radioactive iodine therapy)

Yooeak Shin et al. Mandibular metastasis of papillary thyroid carcinoma: a case report and systematic literature review. J Korean Assoc Oral Maxillofac Surg 2025

III. Results

I. Literature review

Of the 67 papers initially identified in the main database, 56 were excluded due to reasons such as differences in histologic findings compared to the current case or because they discussed lesions in the thyroid and jawbone without clear evidence that the jawbone lesions were metastases originating from the thyroid. Of the included papers, 9 were in English and accessible in full text. After further exclusion of papers that lacked sufficient patient information such as age, sex, and PTC involvement, 8 papers were selected. Two additional papers were identified from the references of the selected papers. Finally, 10 papers and 10 cases were reviewed. A detailed flow chart describing the literature search is shown in Fig. 1.

The mean age of the 10 reported patients was 58.2 years, and 6 (60%) were female. Among the cases, 8 (80%) had metastases in the posterior mandible, and 2 (20%) had large lesions involving the anterior mandible.

In 5 of the 10 reported cases, mandibular metastases oc-

curred after completion of treatment for thyroid cancer. Of these, 2 patients received radioactive iodine therapy (RAI) following thyroidectomy, while the remaining 3 cases underwent thyroidectomy alone.

In the remaining 5 cases, the mandibular lesion led to the discovery of the thyroid lesion, as in our patient. Among them, 4 cases underwent mandible resection along with complete thyroidectomy. In 1 case, due to the patient's general condition, only thyroidectomy and palliative RAI were performed, without mandible resection.

Lymph node metastasis occurred in 4 of 6 cases reported to have PTC, three of which showed multiple lymph node metastasis, while 1 showed solitary metastasis at level I. Among the 4 cases reported with follicular variant papillary thyroid carcinoma (FVPTC), in which lymph node metastasis is known to be relatively rare, 1 case reported no lymph node metastasis, and the remaining 3 cases did not mention lymph node metastasis.

2. Case report

A 28-year-old male patient presented with a chief com-

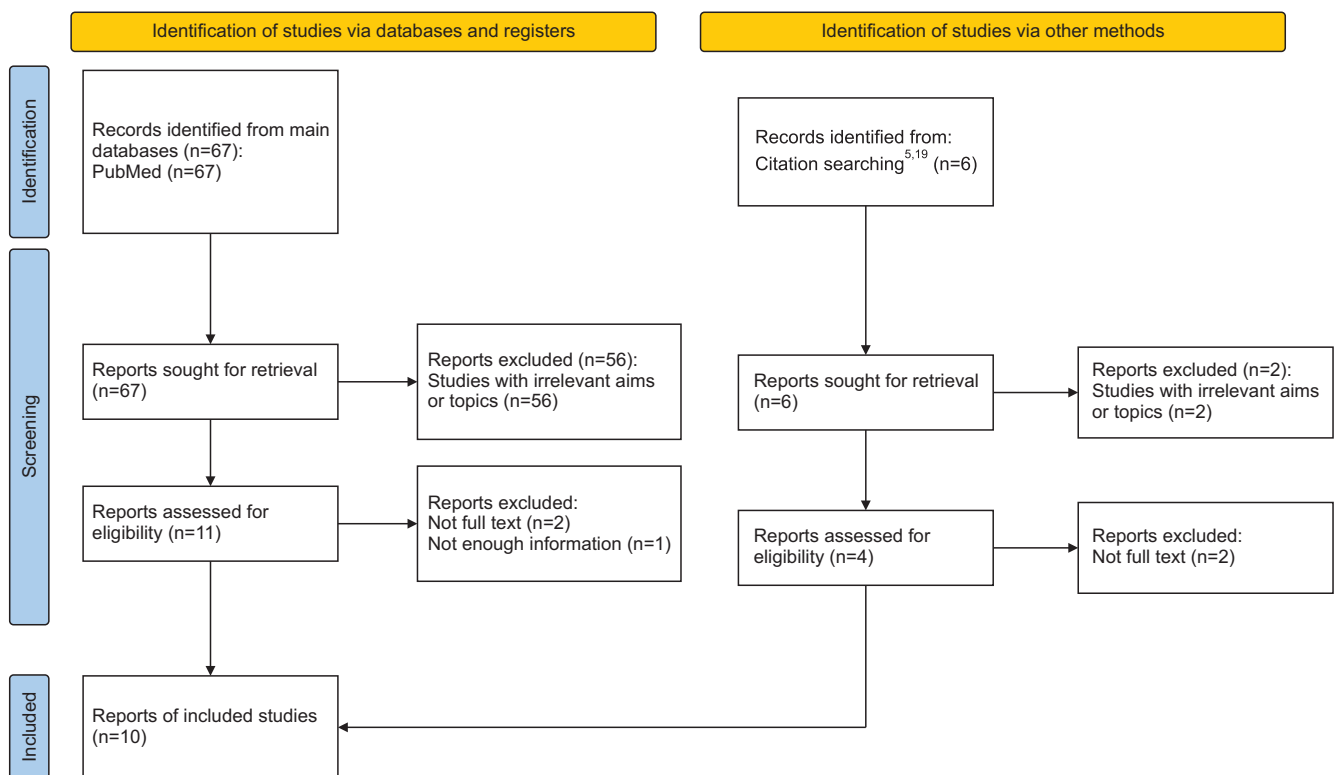


Fig. 1. PRISMA (Preferred Reporting Items for Systematic reviews and Meta-Analyses) flow diagram of systematic literature reviews. ^{5,19}Citation searching identified reports referenced by the main database.

Yootaek Shin et al: Mandibular metastasis of papillary thyroid carcinoma: a case report and systematic literature review. *J Korean Assoc Oral Maxillofac Surg* 2025

plaint of an impacted right mandibular tooth and had no neurologic symptoms such as paresthesia. A panoramic radiograph at the time of the initial visit showed a mixed radiolucent and radiopaque lesion with indistinct margins in the right mandibular ramus and the right retromolar trigone area. (Fig. 2)

The mandibular specimens showed a proliferative lesion with papillary epithelial structures and psammoma bodies in the connective tissue.(Fig. 3) In addition, some epithelial cells showed pseudo-inclusions, and nuclear grooves were

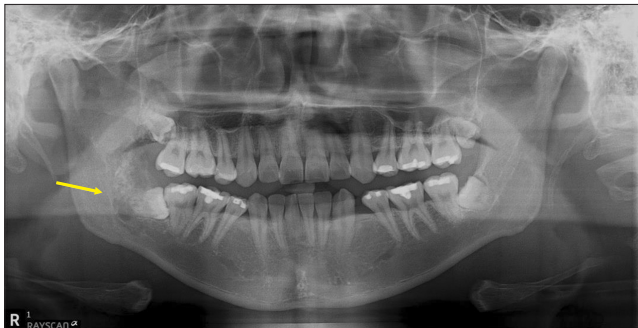

Fig. 2. Radiographic image of the right mandible. Panoramic radiograph showing a mixed radiolucent-radiopaque lesion with indistinct margins in the ascending ramus of the mandible (indicated by yellow arrow).

Yootaek Shin et al: Mandibular metastasis of papillary thyroid carcinoma: a case report and systematic literature review. J Korean Assoc Oral Maxillofac Surg 2025

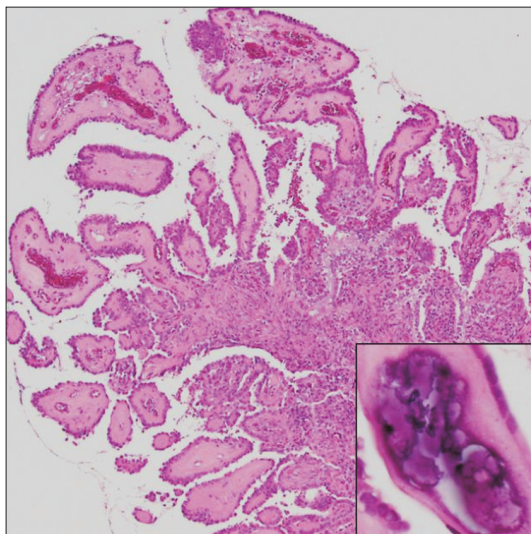


Fig. 3. Histopathologic examination of the incised mandibular specimen, with H&E staining and immunohistochemical staining. A papillary mass consisting of hyalinized or fibrovascular cores with inflammatory cell infiltrate ($\times 12.5$ original magnification). Psammoma bodies were observed within the lesion (inset, $\times 200$ original magnification).

Yootaek Shin et al: Mandibular metastasis of papillary thyroid carcinoma: a case report and systematic literature review. J Korean Assoc Oral Maxillofac Surg 2025

noted. Further immunohistochemical staining revealed tumor cells positive for cytokeratin in the cytoplasm and positive for TTF-1 in the nucleus, confirming the diagnosis of metastatic thyroid carcinoma in the mandible.

Therefore, a total thyroidectomy with central neck lymph node dissection and bilateral modified radical neck dissection was performed for the pT4aN1bM1, stage IVB thyroid lesion.(Fig. 4) In addition, segmental resection of the metastatic mandibular lesion was performed with simultaneous implant placement and free fibular flap reconstruction (jaw-in-a-day technique).

H&E staining was performed on the obtained thyroid, lymph node, and mandibular specimens. In both thyroid lobes, findings consistent with conventional PTC were observed, with infiltration into surrounding tissues and a multicentric growth pattern.(Fig. 5) The tumor size in the mandibular lesion was 3.4 cm, and the lesion showed a proliferative papillary epithelial structure, confirming it as a papillary carcinoma of thyroid origin. Infiltration into the bone marrow spaces was noted, with significant bone destruction at the center of the tumor. Of the 88 lymph nodes removed, metastases of thyroid carcinoma were confirmed in 18.

Approximately 3 months after surgery, RAI was administered. One year postoperatively, there was no evidence of distant metastasis or recurrence, and the fibula flap was functioning well with the implant in place.

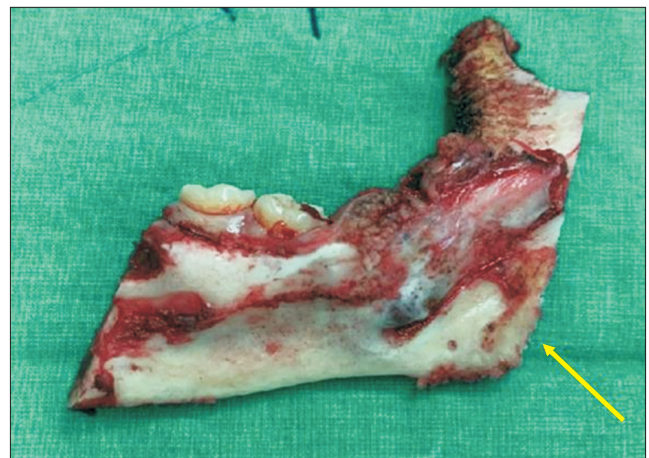

Fig. 4. Clinical photograph of the resected mandibular lesion. A tumor in the left retromolar trigone area of the mandible was identified (indicated by yellow arrow).

Yootaek Shin et al: Mandibular metastasis of papillary thyroid carcinoma: a case report and systematic literature review. J Korean Assoc Oral Maxillofac Surg 2025

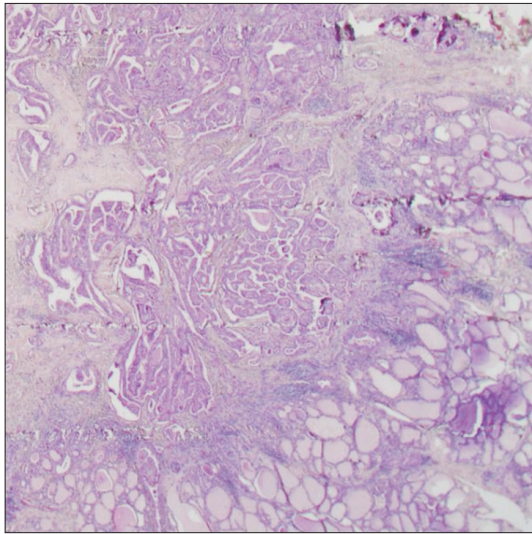


Fig. 5. Histopathologic examination of excised thyroid specimens (H&E). Infiltrative papillary thyroid carcinoma exhibited severe desmoplasia, heavy lymphoid infiltrates, and destruction of adjacent normal thyroid tissues ($\times 12.5$ original magnification).

Yootaek Shin et al: Mandibular metastasis of papillary thyroid carcinoma: a case report and systematic literature review. *J Korean Assoc Oral Maxillofac Surg* 2025

IV. Discussion

Malignant tumors metastasizing to the jawbone make up about 1% of all jawbone malignancies. Distant metastasis occurs in 1%-3% of thyroid cancer cases, with common sites being the spine (29%), pelvis (22%), ribs (17%), and femur (11%)⁶. Metastasis to the jawbone is rare, seen in only 6% of thyroid cancer cases⁴.

Histological analysis indicates that PTC is more prevalent than FTC. However, distant metastasis primarily occurs in FTC, with 71.8% of all thyroid cancer metastases originating from FTC and 28.2% from PTC⁷. FTC typically spreads through the bloodstream, while PTC spreads through the cervical lymph nodes⁸. Given the abundance of blood supply in the mandibular region, the occurrence of mandibular metastasis from PTC is rare, as the primary metastatic route to this area is hematogenous⁹. A specific type of PTC displays histological characteristics of both FTC and PTC, classified as FVPTC. FVPTC is more likely to metastasize to distant regions than conventional type PTC, though lymph node metastasis is uncommon^{10,11}. The case presented in this study is an uncommon instance of conventional PTC with distant metastasis to the mandible.

In cases of distant metastasis from thyroid cancer, surgical resection of the metastatic site, complete resection of the primary thyroid lesion, and neck dissection for metastatic lymph nodes are recommended as a guideline¹².

Lymph node metastasis is rare in FVPTC but common in PTC, occurring in 40%-90% of cases, especially in younger patients¹³. Shukla et al.¹⁴ reported that there is a tendency for the number of nodal metastases and the total number of metastatic lymph nodes to decrease with increasing decade of age. In addition, the likelihood of central lymph node metastasis is higher in males, those younger than 45 years, those with primary PTC tumors larger than 1 cm, extrathyroidal extension, or those with microcalcifications detected on ultrasound¹³.

In PTC, lymph node metastasis typically occurs first in the central cervical lymph nodes (CCLN) and then tends to spread to the lateral cervical lymph nodes (LCLN)¹³. Zhang et al.¹⁵ reported that, among patients with PTC, 44.57% had metastasis in the CCLN, while 17.17% had metastasis in the LCLN. In this context, Liu et al. asserted that lateral cervical lymph node dissection should be actively considered when there are metastases in three or more CCLN¹³.

In the 10 cases reviewed here, excluding 5 with a history of previous thyroid surgery, surgical treatment of both the primary site and the metastatic sites was performed in 4 cases. In one case, the metastatic mandibular lesion was considered too large for complete resection, which would have adversely affected the patient's postoperative quality of life. Of the cases, 5 were reported as PTC and 5 as FVPTC. Of the 5 cases reported as PTC, 3 had significant cervical lymph node metastasis, but only 1 of these cases reported neck dissection. Of the 5 cases reported as FVPTC, none specifically mentioned cervical lymph node metastasis, but 1 did report central lymph node dissection.

In the treatment of thyroid cancer, RAI and external beam radiotherapy can be used in various contexts, from treatment of residual disease to palliative care¹². RAI may significantly improve survival in metastatic disease, especially in younger patients, compared with other postoperative adjuvant therapies¹⁶. Of the 10 patients reviewed, 4 had undergone RAI postoperatively, while the remaining 6 cases did not report postoperative RAI¹⁷⁻²⁰.

In the case presented, the patient underwent complete resection of the primary thyroid carcinoma and segmental mandibulectomy for the metastatic mandibular lesion. The patient was relatively young (28 years old), and multiple lymph node metastasis was suspected due to the primary thyroid tumor being larger than 1 cm and the presence of extrathyroidal extension. As expected, multiple lymph node metastasis was found. Consequently, central cervical lymph node dissection and lateral cervical lymph node dissection were performed. High-dose RAI (200 mCi) was administered at approximately

3 months after surgery.

In addition, the “jaw-in-a-day” technique was used for the resected mandible, which included virtual surgical planning (VSP) and a prefabricated surgical guide. This technique facilitated the placement of a fibular free flap and implants, resulting in improved patient quality of life and high patient and caregiver satisfaction.

Thyroid cancer metastasis to the mandible is rare and tends to occur more frequently in females and the elderly. Although PTC is the most common type of thyroid cancer, distant metastases are more commonly seen with FTC.

This paper reports an unusual case of PTC, which rarely metastasizes to other organs, metastasizing to the jawbone region of a young male patient, which is also unusual compared to the typically older age at which metastatic thyroid cancer is observed. Due to the rarity of this type of case, a systematic literature review was conducted to investigate previously reported cases related to this phenomenon.

V. Conclusion

Thyroid cancer metastasis to the mandible is rare and tends to occur more frequently in females and the elderly. Although PTC is the most common type of thyroid cancer, distant metastases are more commonly seen with FTC.

In this paper, we report an unusual case of PTC, which rarely metastasizes to other organs, that metastasized to the jawbone region of a young male patient, which is also unusual compared to the typically older age at which metastatic thyroid cancer is observed. Due to the rarity of this case, we conducted a systematic literature review to investigate previously reported cases related to this phenomenon.

ORCID

Yootaek Shin, <https://orcid.org/0009-0000-1132-4156>

Hyounmin Kim, <https://orcid.org/0000-0002-1900-4744>

Solbin Yang, <https://orcid.org/0009-0000-2366-5951>

Seung-Yong Han, <https://orcid.org/0000-0002-9558-5384>

Eunae Sandra Cho, <https://orcid.org/0000-0002-0820-3019>

Dongwook Kim, <https://orcid.org/0000-0001-6167-6475>

Hyung Jun Kim, <https://orcid.org/0000-0001-8247-4004>

Authors' Contributions

Y.S. participated in data collection and writing the manuscript. H.K., S.Y., S.Y.H., E.S.C., and D.K. participated in

the study design. H.J.K. participated in the study design and helped to draft the manuscript. All authors read and approved the final manuscript.

Funding

No funding to declare.

Conflict of Interest

No potential conflict of interest relevant to this article was reported.

References

1. Hirshberg A, Shnaiderman-Shapiro A, Kaplan I, Berger R. Metastatic tumours to the oral cavity - pathogenesis and analysis of 673 cases. *Oral Oncol* 2008;44:743-52. <https://doi.org/10.1016/j.oraloncology.2007.09.012>
2. Hirshberg A, Leibovich P, Buchner A. Metastatic tumors to the jawbones: analysis of 390 cases. *J Oral Pathol Med* 1994;23:337-41. <https://doi.org/10.1111/j.1600-0714.1994.tb00072.x>
3. Irani S. Metastasis to the Jawbones: a review of 453 cases. *J Int Soc Prev Community Dent* 2017;7:71-81. https://doi.org/10.4103/jispcd.jispcd_512_16
4. LiVolsi VA. Papillary thyroid carcinoma: an update. *Mod Pathol* 2011;24 Suppl 2:S1-9. <https://doi.org/10.1038/modpathol.2010.129>
5. Nikitakis NG, Polymeri A, Polymeris A, Sklavounou A. Metastatic papillary thyroid carcinoma to the maxilla: case report and literature review. *Head Neck Pathol* 2012;6:216-23. <https://doi.org/10.1007/s12105-011-0323-6>
6. Pittas AG, Adler M, Fazzari M, Tickoo S, Rosai J, Larson SM, et al. Bone metastases from thyroid carcinoma: clinical characteristics and prognostic variables in one hundred forty-six patients. *Thyroid* 2000;10:261-8. <https://doi.org/10.1089/thy.2000.10.261>
7. Colella G, Capone R, Cappabianca S. Mandibular metastasis from papillary thyroid carcinoma--a case report. *Tumori* 2003;89:452-4. <https://doi.org/10.1177/030089160308900422>
8. Wareing J, Dawoud B, Power A, Sutton D. Intrabony mandibular metastases caused by papillary thyroid carcinoma masquerading as a parotid swelling. *Ann R Coll Surg Engl* 2021;103:e264-5. <https://doi.org/10.1308/rcsann.2020.7091>
9. Vural E, Hanna E. Metastatic follicular thyroid carcinoma to the mandible: a case report and review of the literature. *Am J Otolaryngol* 1998;19:198-202. [https://doi.org/10.1016/s0196-0709\(98\)90088-6](https://doi.org/10.1016/s0196-0709(98)90088-6)
10. Bingol UA, Cinar C, Cetinkale O. Mandibular metastases of papillary thyroid carcinoma treated by hemimandibulectomy and costochondral rib graft. *Plast Reconstr Surg Glob Open* 2015;3:e305. <https://doi.org/10.1097/gox.0000000000000275>
11. Wahyono A, Dwianingsih EK, Avanti WS, Cahyono R, Mandasari R, Anwar SL. Hemi-mandibulectomy without bony reconstruction: a case report of mandibular metastasis from a silent differentiated papillary thyroid cancer. *Ann Med Surg (Lond)* 2022;75:103334. <https://doi.org/10.1016/j.amsu.2022.103334>
12. Anajar S, Hassnaoui J, Rouadi S, Abada R, Roubal M, Mahtar M. Mandibular metastasis revealed papillary thyroid carcinoma: rare case. *Int J Surg Case Rep* 2017;37:130-3. <https://doi.org/10.1016/j.ijscr.2017.05.001>
13. Liu C, Xiao C, Chen J, Li X, Feng Z, Gao Q, et al. Risk factor analysis for predicting cervical lymph node metastasis in papil-

- lary thyroid carcinoma: a study of 966 patients. *BMC Cancer* 2019;19:622. <https://doi.org/10.1186/s12885-019-5835-6>
14. Shukla N, Osazuwa-Peters N, Megwalu UC. Association between age and nodal metastasis in papillary thyroid carcinoma. *Otolaryngol Head Neck Surg* 2021;165:43-9. <https://doi.org/10.1177/0194599820966995>
 15. Zhang T, He L, Wang Z, Dong W, Sun W, Zhang P, et al. Risk factors of cervical lymph node metastasis in multifocal papillary thyroid cancer. *Front Oncol* 2022;12:1003336. <https://doi.org/10.3389/fonc.2022.1003336>
 16. Khoozestani NK, Mosavat F, Shirkhoda M, Sedaghati A. Metastatic papillary thyroid carcinoma of the mandible: case report and literature review. *J Oral Maxillofac Pathol* 2019;23(Suppl 1):97-105. https://doi.org/10.4103/jomfp.jomfp_106_18
 17. Liu L, Venkataraman G, Salhadar A. Follicular variant of papillary thyroid carcinoma with unusual late metastasis to the mandible and the scapula. *Pathol Int* 2007;57:296-8. <https://doi.org/10.1111/j.1440-1827.2007.02092.x>
 18. Kumar RV, Chakravarthy C, Sekhar GR, Devireddy SK, Kumaravelu C, Kare A. Metastatic thyroid carcinoma presenting as hypervascular lesion of the mandible: a case report and review of literature. *J Oral Maxillofac Surg* 2010;68:2613-6. <https://doi.org/10.1016/j.joms.2009.10.004>
 19. Gholami S, Bakhshi M, Atarbashi-Moghadam S, Mir Mohammad Sadeghi H, Rahimzamani A. Mandibular metastasis of silent papillary thyroid carcinoma: a rare case report with review of the literature. *Case Rep Dent* 2020;2020:8683465. <https://doi.org/10.1155/2020/8683465>
 20. Raffaelli SD, Shupak RP, Winstead M, Hockaday JJ, Kim RY. A rare incidence of mandibular metastasis of papillary thyroid carcinoma: a case report and review of literature. *J Stomatol Oral Maxillofac Surg* 2023;124(6 Suppl):101560. <https://doi.org/10.1016/j.jormas.2023.101560>

How to cite this article: Shin Y, Kim H, Yang S, Han SY, Cho ES, Kim D, et al. Mandibular metastasis of papillary thyroid carcinoma: a case report and systematic literature review. *J Korean Assoc Oral Maxillofac Surg* 2025;51:73-79. <https://doi.org/10.5125/jkaoms.2025.51.2.73>