



Medication-related osteonecrosis of the jaw: an evidence-based 2025 position statement from a Korean multidisciplinary task force

Jin-Woo Kim¹, Sung-Hye Kong², Jae-Young Kim³, Mi Kyung Kwak⁴, Jun-Young Kim⁵, Ji-Hyeon Oh⁶, Hyung-Youl Park⁷, BeomTaek Kim⁸, Young-Kyun Lee⁹, Jeong Joon Han¹⁰, Moon-Young Kim¹¹, Yong Jun Choi¹², Yong-Dae Kwon¹³, Kwang-Sup Song¹⁴, Beom-Jun Kim¹⁵, Sun-Jong Kim¹, Seung-Hoon Baek¹⁶, Dong Ock Lee¹⁷, Han Seok Choi¹⁸, Ha Young Kim¹⁹, Tae-Geon Kwon²⁰; The Committee for the Korean Position Paper on

Medication-Related Osteonecrosis of the Jaw, representing the Korean Society for Bone and Mineral Research, the Korean Association of Oral and Maxillofacial Surgeons, the Korean Association of Maxillofacial Plastic and Reconstructive Surgeons, the Korean Society of Osteoporosis, and the Korean Endocrine Society

¹Department of Oral and Maxillofacial Surgery, Ewha Womans University College of Medicine, Seoul, ²Department of Internal Medicine, Seoul National University Bundang Hospital, Seoul National University College of Medicine, Seongnam, ³Department of Oral and Maxillofacial Surgery, Gangnam Severance Hospital, Yonsei University College of Dentistry, Seoul, ⁴Division of Endocrinology and Metabolism, Department of Internal Medicine, Hallym University Dongtan Sacred Heart Hospital, Hwaseong, ⁵Department of Oral and Maxillofacial Surgery, Yonsei University College of Dentistry, Seoul, ⁶Department of Oral and Maxillofacial Surgery, Dental Hospital, Gangneung-Wonju National University, Gangneung, ⁷Department of Orthopedic Surgery, Eunpyeong St. Mary's Hospital, College of Medicine, The Catholic University of Korea, Seoul, ⁸Department of Family Practice and Community Health, Ajou University School of Medicine and Graduate School of Medicine, Suwon, ⁹Department of Orthopedic Surgery, Seoul National University Bundang Hospital, Seongnam, ¹⁰Department of Oral and Maxillofacial Surgery, Dental Research Institute, School of Dentistry, Seoul National University, Seoul, ¹¹Department of Oral and Maxillofacial Surgery, College of Dentistry, Dankook University, Cheonan, ¹²Department of Endocrinology and Metabolism, Ajou University School of Medicine, Suwon, ¹³Department of Oral and Maxillofacial Surgery, Kyung Hee University College of Dentistry, ¹⁴Department of Orthopaedic Surgery, Chung-Ang University Hospital, Chung-Ang University College of Medicine, ¹⁵Division of Endocrinology and Metabolism, Department of Internal Medicine, Asan Medical Center, University of Ulsan College of Medicine, Seoul, ¹⁶Department of Orthopedic Surgery, Kyungpook National University Hospital, School of Medicine, Kyungpook National University, Daegu, ¹⁷Center for Uterine Cancer, Research Institute and Hospital, National Cancer Center, ¹⁸Division of Endocrinology and Metabolism, Department of Internal Medicine, Dongguk University Ilsan Hospital, Goyang, ¹⁹Division of Endocrinology, Department of Internal Medicine, Gangneung Asan Hospital, University of Ulsan College of Medicine, Gangneung, ²⁰Department of Oral and Maxillofacial Surgery, School of Dentistry, Kyungpook National University, Daegu, Korea

Dong Ock Lee

Center for Uterine Cancer, Research Institute and Hospital, National Cancer Center, 323 Ilsan-ro, Ilsandong-gu, Goyang 10408, Korea
TEL: +82-31-920-1638
E-mail: dolee@ncc.re.kr
ORCID: <https://orcid.org/0000-0002-9009-3508>

Han Seok Choi

Division of Endocrinology and Metabolism, Department of Internal Medicine, Dongguk University Ilsan Hospital, 27 Dongguk-ro, Ilsandong-gu, Goyang 10326, Korea
TEL: +82-31-961-5777
E-mail: hschoi402@dumc.or.kr
ORCID: <https://orcid.org/0000-0002-6506-4342>

Ha Young Kim

Division of Endocrinology, Department of Internal Medicine, Gangneung Asan Hospital, University of Ulsan College of Medicine, 38 Bangdong-gil, Gangneung 25440, Korea
TEL: +82-33-610-4580
E-mail: hykimmd@hanmail.net
ORCID: <https://orcid.org/0000-0002-0651-2213>

Jin-Woo Kim

Department of Oral and Maxillofacial Surgery, Ewha Womans University College of Medicine, 1071 Anyangcheon-ro, Yangcheon-gu, Seoul 07985, Korea
TEL: +82-2-2650-2720
E-mail: jwkim84@ewha.ac.kr
ORCID: <https://orcid.org/0000-0002-1672-5730>

Tae-Geon Kwon

Department of Oral and Maxillofacial Surgery, School of Dentistry, Kyungpook National University, 2175 Dalgubeol-daero, Jung-gu, Daegu 41940, Korea
TEL: +82-53-600-7574
E-mail: kwondk@knu.ac.kr
ORCID: <https://orcid.org/0000-0003-2799-0510>

This position statement is jointly endorsed by the Korean Society for Bone and Mineral Research, the Korean Association of Oral and Maxillofacial Surgeons, the Korean Association of Maxillofacial Plastic and Reconstructive Surgeons, the Korean Endocrine Society, and the Korean Society of Osteoporosis. By agreement of the Editors-in-Chief, this article is being published simultaneously in *Endocrinology and Metabolism* and the *Journal of the Korean Association of Oral and Maxillofacial Surgeons*. The two versions are identical except for journal-specific front matter and copyediting. Either version may be cited; please reference the journal you consult.

© This is an open-access article distributed under the terms of the Creative Commons Attribution Non-Commercial License (<http://creativecommons.org/licenses/by-nc/4.0/>), which permits unrestricted non-commercial use, distribution, and reproduction in any medium, provided the original work is properly cited.

© 2025 The Korean Association of Oral and Maxillofacial Surgeons.

Abstract (J Korean Assoc Oral Maxillofac Surg 2025;51:333-353)

With a rapidly aging population and increasing use of antiresorptive agents, medication-related osteonecrosis of the jaw (MRONJ) represents a growing clinical challenge worldwide. To address the need for tailored clinical guidance, a multidisciplinary task force was convened. Five Korean academic societies—the Korean Society for Bone and Mineral Research, the Korean Association of Oral and Maxillofacial Surgeons, the Korean Association of Maxillofacial Plastic and Reconstructive Surgeons, the Korean Society of Osteoporosis, and the Korean Endocrine Society—collaborated to develop this position statement. The consensus was formulated through comprehensive reviews of literature, combined with three rounds of formal surveys to consolidate expert opinion on controversial topics. This position paper provides evidence-based clinical guidelines for the prevention, diagnosis, and management of MRONJ tailored to the Korean healthcare environment. The diagnostic criteria affirm the standard definition but add a provision for diagnosis based on clinical or radiographic evidence of necrotic bone, even if the traditional 8-week timeframe has not been met. The committee advocates for retaining Stage 0 in the staging system to emphasize early detection and preventive intervention. Key recommendations include prescriptive, drug-specific guidelines for prophylactic drug holidays (e.g., a 2-month pause for oral bisphosphonates; timing surgery 3-4 months after the last denosumab injection) to minimize MRONJ risk from dental procedures. This statement also provides a clear framework for therapeutic drug holidays in established MRONJ, carefully balancing the need for jaw healing against systemic fracture risk. For treatment, this statement advocates for early and active surgical intervention across all MRONJ stages, supported by evidence of superior long-term outcomes compared to conservative management. This position statement offers a unique, evidence-based Korean clinical practice guideline for managing MRONJ. It is intended to standardize care, reduce clinical confusion, and ultimately improve patient outcomes by providing a clear framework for decision-making.

Key words: Medication-related osteonecrosis of the jaw, Bisphosphonates, Denosumab, Osteoporosis, Drug holiday, Guideline, Prevention
[paper submitted 2025. 10. 3 / revised 2025. 11. 11 / accepted 2025. 11. 17]

I. Introduction

South Korea is experiencing one of the world's most rapid demographic shifts towards a super-aged society, a trend that has profound implications for public health. This aging population has led to a high prevalence of osteoporosis; according to the Korea National Health and Nutrition Examination Survey (2008-2011), 22.4% of the population aged 50 and over has osteoporosis, affecting approximately one in five adults in this age group¹. The clinical sequelae of this disease are significant, with the incidence of osteoporosis-related fractures nearly doubling from 226,000 in 2008 to 434,000 in 2022². Hip fractures, in particular, are associated with a one-year mortality rate of approximately 17%, underscoring the critical need for effective fracture prevention². Consequently, the prescription of antiresorptive agents, primarily bisphosphonates (BPs) and denosumab, has risen substantially³. While BP prescriptions peaked in 2019, denosumab use has surged since its introduction in 2016, and the overall use of injectable formulations surpassed oral agents after 2020⁴.

Since osteonecrosis of the jaw associated with BP therapy was first reported in 2003, the diagnosis and management of what is now known as medication-related osteonecrosis of the jaw (MRONJ) have been subjects of considerable debate and clinical evolution. The American Association of Oral and Maxillofacial Surgeons (AAOMS) has been instrumental in defining the condition, first as BP-related osteonecrosis of the

jaw (BRONJ) in 2007 and later expanding the terminology to MRONJ in 2014 to include other agents like denosumab and antiangiogenics^{5,6}. However, international guidelines have continued to evolve, with the 2022 AAOMS position paper notably removing specific recommendations for prophylactic drug holidays, instead favoring a more generalized, individualized risk assessment⁷. While this approach has its merits, it has also created clinical uncertainty. Previous Korean position statements were published in 2015 and 2021 to address local needs^{3,8}. The unique epidemiological trends, healthcare system, and clinical practice patterns in Korea—where clinicians often prefer more prescriptive guidance to navigate complex decisions—necessitate a dedicated national consensus that reflects both global evidence and local clinical realities.

The primary objective of this position statement is to develop a practical, evidence-based clinical guideline for MRONJ that is directly applicable in the healthcare setting. This document is the culmination of a Korean multi-society collaboration involving 20 experts from five key academic societies: the Korean Association of Oral and Maxillofacial Surgeons, the Korean Association of Maxillofacial Plastic and Reconstructive Surgeons, the Korean Society of Osteoporosis, the Korean Society for Bone and Mineral Research, and the Korean Endocrine Society. This task force established a consensus through a rigorous process of in-depth literature reviews and three rounds of formal surveys, ensuring that

the recommendations are grounded in the latest scientific evidence while also reflecting the collective expertise of Korean clinicians. This paper aims to provide a clear, integrated framework for the definition, diagnosis, prevention, and treatment of MRONJ, with the goal of standardizing care and serving as an essential guide for clinicians managing patients on antiresorptive therapies.

II. Definition, Diagnosis, and Staging

1. Diagnostic criteria for MRONJ

The term MRONJ was adopted by the AAOMS in 2014 to encompass osteonecrosis associated not only with BPs but also with other antiresorptive (e.g., denosumab) and antiangiogenic agents⁶. While other terms such as “denosumab-related osteonecrosis of the jaw” or “antiresorptive agent-related osteonecrosis of the jaw” are used in some contexts, this committee has adopted MRONJ as the standard terminology unless a specific agent needs to be distinguished⁹.

Based on a comprehensive review of recent literature and international guidelines, this committee defines MRONJ by the following three criteria^{7,10,11}:

- (1) Current or previous treatment with an antiresorptive agent alone, or in combination with an immune modulator or antiangiogenic medication.
- (2) Exposed bone, or bone that can be probed through an intraoral or extraoral fistula, in the maxillofacial region that has persisted for more than 8 weeks. However, if necrotic bone is confirmed clinically or radiographically, the condition can be diagnosed as MRONJ even if the 8-week criterion has not been met.
- (3) No history of radiation therapy to the jaws or evidence of primary or metastatic malignant diseases to the jaws.

The addendum to the second criterion is crucial clarification. It acknowledges that definitive clinical or radiographic evidence of bone necrosis should not be disregarded simply because the 8-week observation period is incomplete, allowing for earlier diagnosis and intervention.

2. Imaging and other diagnostic aids

While the diagnosis of MRONJ is primarily based on clinical history and examination, various diagnostic aids are essential for assessing the extent of the disease, guiding treatment, and performing differential diagnosis.

- Imaging: Radiographic evaluation is a cornerstone of

MRONJ assessment.

- Panoramic radiography: May reveal features such as osteolytic lesions, sequestrum formation, thickening of the lamina dura, or widening of the periodontal ligament space. However, these findings are often present only in mid-later stages and are not specific to MRONJ¹².
- Computed tomography/cone-beam computed tomography (CT/CBCT): Provides superior three-dimensional detail, allowing for visualization of bone sclerosis, osteolysis, and periosteal reactions. These findings, while characteristic, are not pathognomonic and may be absent in early-stage disease¹³. Some reports suggest that BP-related lesions exhibit more pronounced sclerosis on CBCT compared to those associated with denosumab¹⁴.
- Magnetic resonance imaging (MRI): Is particularly useful for evaluating soft tissue involvement and bone marrow changes. In MRONJ, MRI may show decreased T1 and increased T2 signal intensity, indicative of marrow inflammation and edema^{15,16}.
- Nuclear medicine: Bone scintigraphy and single photon emission computed tomography (SPECT/CT) provide functional information on bone metabolism and can help delineate the extent of the necrotic lesion with high sensitivity, often more clearly than anatomical imaging alone¹⁷⁻²⁰.
- Biomarkers: The use of serum bone turnover markers, particularly C-terminal telopeptide (CTX), was once proposed as a tool for assessing MRONJ risk²¹. However, subsequent large-scale clinical studies and meta-analyses have demonstrated that CTX levels are not a reliable predictor of MRONJ development²²⁻²⁴. Therefore, in alignment with international consensus, this committee does not recommend the use of CTX testing for MRONJ risk assessment. Other potential markers related to angiogenesis (e.g., VEGF) or bone metabolism (e.g., TRACP 5b, RANKL/OPG) have been investigated but are not yet clinically validated²⁵⁻²⁷.
- Biopsy: A bone biopsy provides a definitive histopathological diagnosis but is generally not recommended for MRONJ confirmation. The surgical trauma from the biopsy procedure itself can exacerbate the necrotic process or create a new non-healing lesion²⁸. Its primary role is reserved for cases where there is a clinical suspicion of metastatic disease or primary malignancy that must be ruled out.
- Differential diagnosis: MRONJ must be differentiated from other conditions that present with similar clinical

or radiographic features²⁹. These include alveolar osteitis (“dry socket”), sinusitis, advanced periodontitis, periapical lesions, and fibro-osseous lesions. Other forms of jawbone necrosis, such as osteoradionecrosis (distinguished by a history of radiation therapy) and osteomyelitis of odontogenic origin, must also be considered³⁰. In patients with a history of cancer, metastatic disease to the jaw is a critical differential diagnosis⁹.

3. Clinical staging system and the rationale for retaining Stage 0

Accurate staging is essential for guiding treatment and predicting prognosis. This committee has adopted the widely used AAOMS staging system, which is based on clinical signs and symptoms⁶. MRONJ staging system and treatment recommendations are detailed in Table 1.

A significant point of debate in the international community has been the validity and utility of Stage 0³¹. This stage is characterized by non-specific symptoms (such as unexplained jaw pain, altered sensation, or tooth mobility) and radiographic changes, but without clinical evidence of exposed bone⁶. The argument against its inclusion is that these symptoms are non-specific and can overlap with common dental conditions like periodontitis or temporomandibular disorders, potentially leading to over-diagnosis of MRONJ³¹. Such a diagnosis could cause undue patient anxiety and lead to the inappropriate discontinuation of essential antiresorptive therapy, thereby increasing fracture risk³².

Despite these valid concerns, this committee, after exten-

sive discussion and formal surveys, has decided to retain Stage 0 in its staging system. This decision is rooted in a clinical philosophy that prioritizes early detection and proactive prevention. Stage 0 serves as a crucial clinical alert, prompting heightened surveillance for high-risk patients who present with suggestive symptoms. By identifying patients at this preclinical stage, clinicians can implement preventive measures, provide patient education, and perform closer monitoring to potentially avert the progression to frank bone exposure³³. Retaining Stage 0 empowers clinicians to intervene at the earliest possible moment, which is fundamental to minimizing the morbidity associated with advanced MRONJ.

III. Epidemiology

1. Osteoporosis

1) Bisphosphonates

According to a systematic literature review conducted for this position meeting, the prevalence of MRONJ in osteoporosis patients treated with BPs is reported to be 0.01%-0.10%^{34,35}. The incidence is reported to be between 10 and 45.06 per 100,000 person-years^{34,35}. A 2008 multi-center study in Korea involving approximately 600,000 patients prescribed BPs identified 254 cases of MRONJ, estimating an incidence of 0.04%³⁶. A 2012 cohort study using data from the National Health Insurance Service, which followed about 330,000 individuals for four years, reported a cumulative incidence of 20.9 per 100,000 person-years³⁷. An analysis of

Table 1. MRONJ staging system and treatment recommendations

Stage	Definition	Recommended management
At-risk	No exposed or necrotic bone in a patient with a history of antiresorptive or antiangiogenic agent use.	No treatment required. Patient education on risks and symptoms. Regular dental follow-up and maintenance of oral hygiene.
Stage 0	No clinical evidence of necrotic bone, but presents with non-specific clinical findings (e.g., unexplained jaw pain, altered sensation, tooth mobility) or radiographic changes.	Symptomatic treatment (e.g., analgesics), management of other dental conditions. Close clinical and radiographic monitoring.
Stage 1	Exposed and necrotic bone, or a fistula that probes to bone, in patients who are asymptomatic and have no evidence of infection.	Antimicrobial mouth rinse. Regular clinical follow-up. Patient education and review of indications for continued antiresorptive therapy. Early surgical intervention can be considered to achieve resolution.
Stage 2	Exposed and necrotic bone, or a fistula that probes to bone, with evidence of infection (erythema, purulent drainage) and pain.	Symptomatic treatment with oral antibiotics. Antimicrobial mouth rinse. Surgical debridement or resection is strongly recommended to control infection and resolve the lesion.
Stage 3	Exposed and necrotic bone, or a fistula that probes to bone, in patients with pain and infection, and one or more of the following: exposed necrotic bone extending beyond the alveolar region (e.g., inferior border, ramus, maxillary sinus), pathologic fracture, extraoral fistula, or oro-antral/oro-nasal communication.	Antimicrobial mouth rinse, antibiotic therapy, and pain control. Surgical resection of necrotic bone and potential reconstruction is indicated to manage infection and functional/esthetic compromise.

(MRONJ: medication-related osteonecrosis of the jaw)

Jin-Woo Kim et al: Medication-related osteonecrosis of the jaw: an evidence-based 2025 position statement from a Korean multidisciplinary task force. J Korean Assoc Oral Maxillofac Surg 2025

74,491 individuals from the National Health Insurance Service between 2004 and 2015 reported an MRONJ incidence of 45.06 per 100,000 person-years, with a gradual increase corresponding to the cumulative duration of use^{38,39}.

For osteoporosis patients on oral BPs, the prevalence of MRONJ is reported as 0.10%, and the incidence as 36.6 per 100,000 person-years^{40,41}. While large-scale, population-based studies on intravenous (IV) BPs alone are limited compared to oral agents, the prevalence of MRONJ in patients receiving IV BPs for osteoporosis is reported to range from 0.06% to 0.13% , with an incidence of 0-9.6 per 100,000 person-years^{42,43}. A pooled analysis of the Health Outcomes and Reduced Incidence with Zoledronic acid Once Yearly-Pivotal Fracture Trial (HORIZON-PFT) and four other randomized controlled trials reported an MRONJ incidence of less than 8 per 100,000 person-years (<1 per 14,200) in osteoporosis patients receiving 5 mg of zoledronate annually³⁴. However, a recent 2025 systematic review and meta-analysis of literature from 2015 to 2020 reported a mean incidence of 0.58% in osteoporosis patients (from an analysis of 498,443 individuals)⁴⁴. This may indicate a continuing upward trend in MRONJ incidence but also suggests heterogeneity among studies, highlighting the need for future research with sufficient patient numbers and standardized reporting systems. (Supplementary Table 1)

2) Denosumab

In patients treated with denosumab, the prevalence of MRONJ varies widely compared to BP-treated patients, ranging from 0% to 0.18%⁴⁵. The incidence of MRONJ in denosumab users also varies, from 0 to 283 per 100,000 patient-years^{46,47}. In the 10-year FREEDOM-extension trial, 13 cases of osteonecrosis (0.3%) were reported among 4,550 patients, corresponding to an incidence of 5.2 per 10,000 patient-years⁴⁸. Of these, six cases occurred in the crossover group (placebo for the first 3 years, then denosumab for 7 years) and seven in the long-term group (denosumab for 10 years), showing no clear relationship between the duration of denosumab exposure and MRONJ risk⁴⁸. The 2022 AAOMS position paper stated that the cumulative incidence of MRONJ related to denosumab in osteoporosis patients is 0.3%, approximately 10 times higher than that of BPs⁷. Furthermore, the risk of MRONJ is reported to be significantly higher in patients who switch from BPs to denosumab compared to those on monotherapy⁴⁶.

Current research does not provide a definitive conclusion on whether denosumab or BPs carry a higher risk of MRONJ.

A large retrospective cohort study in Taiwan comparing 3,823 denosumab users with 5,139 BP users among 84,102 osteoporosis patients reported a lower incidence of MRONJ in the denosumab group (147 vs. 249 per 100,000 patient-years)⁴⁶. However, this study's longer observation period for denosumab compared to BPs should be considered. Conversely, a large cohort study in Switzerland reported a significantly higher incidence of MRONJ in denosumab users compared to BP users (283 vs. 45 per 100,000 patient-years)⁴⁷. It is important to note that 9 of the 12 patients who developed MRONJ had previously used BPs before switching to denosumab, with only 3 on denosumab monotherapy. Additionally, the BP group included patients on less expensive oral agents, making a direct comparison of risk difficult⁴⁷. While several animal studies have reported that denosumab induces MRONJ at a rate similar to or higher than zoledronate, clinical studies suggesting a relatively higher risk for denosumab are mainly from single-center studies with limited patient numbers⁴⁹. Thus, there has been not enough evidence to conclude that denosumab carries a higher risk than BPs.

3) Romosozumab

Case reports have described osteonecrosis associated with romosozumab, but most of these patients had a prior history of BP use, making it difficult to determine the role of romosozumab alone^{50,51}. In the FRAME randomized controlled trial, two cases of MRONJ were reported among 3,591 patients in the romosozumab group, an incidence of 0.03%-0.05%, which is similar to the risk associated with alendronate^{52,53}. An analysis of the U.S. Food and Drug Administration Adverse Event Reporting System (FAERS) also reported an association between romosozumab use and an increased risk of MRONJ⁵⁴. Further investigation is needed to clarify this association.

4) Selective estrogen receptor modulators (SERMs)

SERMs, which are antiresorptive agents, are known to have a relatively lower risk of MRONJ compared to BPs or denosumab due to their less potent inhibition of bone resorption. Cases of MRONJ in osteoporosis patients using SERMs have mostly been reported as case studies, often involving patients with a prior history of BP use or other risk factors. However, some case reports have described MRONJ in osteoporosis patients using only raloxifene without any prior use of other osteoporosis medications⁵⁵. A study analyzing the Korean National Health Insurance Service sample cohort from 2002 to 2019 reported 14 cases of MRONJ among

3,101 patients who used only SERMs⁵⁶. This study, however, did not account for other MRONJ risk factors in its analysis, limiting the interpretation of its findings⁵⁶. Due to the lack of studies analyzing precise prevalence, a definitive conclusion on the association between SERMs and MRONJ cannot be drawn at this time.

2. Malignant tumors with bone metastases or multiple myeloma

In patients with bone metastases from malignant tumors, the incidence of MRONJ with zoledronate use is reported to be 0.7%-4.0%, which is much higher than in osteoporosis patients^{57,58}. The incidence is slightly higher in multiple myeloma patients, at 2.4%-4%^{59,60}. This increased incidence is thought to be due to higher cumulative doses from frequent administration (12-15 times higher), with a relatively high incidence of 0.3%-0.7% reported even with oral BPs^{61,62}. This is also related to concomitant medications (anticancer drugs, steroids, antiangiogenic agents), poor general health, and oral hygiene⁶³. Christodoulou et al.⁶⁴ analyzed 116 patients with ONJ receiving IV BPs and found that while the incidence of MRONJ was 1.1% in patients receiving IV BPs alone, it increased to 16% in patients also receiving antiangiogenic agents such as bevacizumab and sunitinib.

The duration of BP therapy, especially at high doses, can influence the development of MRONJ, with incidence varying by duration⁶⁵. A recent systematic review reported that in cancer patients treated with zoledronate, the incidence of MRONJ was 1.6%-4% within the first two years of treatment, increasing to 3.8%-18% with more than two years of treatment⁶⁵. Similarly, for denosumab, the incidence was 1.9% within two years and rose to 6.9% after two years⁶⁵. The incidence of MRONJ can also vary by cancer type, and interpretation of incidence in these patient populations requires caution due to their relatively shorter follow-up periods related to life expectancy⁶⁵. In some studies with follow-up periods of about 8 years, the incidence of MRONJ in patients with metastatic cancer was reported to be as high as 30%^{66,67}.

In cancer patients, particularly those being treated for bone metastases, denosumab is administered at a dose of 120 mg every 4 weeks, which is about 12 times more potent than the osteoporosis treatment dose. In large-scale trials, the prevalence of MRONJ in denosumab users was reported to be between 0.8% and 2%, and a recent domestic study of 1,278 patients reported an incidence of 2.66%^{68,69}. However, in real-world clinical practice, the risk of MRONJ is reported to be

even higher, ranging from 5% to 12.6% in patients receiving combination therapy with biologic agents^{70,71}. An even higher incidence was observed in patients who switched from zoledronate to denosumab⁷². It is not yet clear whether the increased incidence of MRONJ in the denosumab group is due to denosumab itself or the total duration of therapy⁷³. (Supplementary Table 2)

3. Cancer treatment-induced bone loss (CTIBL)

In breast cancer patients receiving adjuvant zoledronate to prevent or reduce treatment-induced bone loss, the incidence of MRONJ is reported to be 0%-1.34% compared to 0%-0.24% in control groups, with rates up to 2.1% reported after more than 6 years of follow-up⁷⁴⁻⁷⁶. When oral BPs are used as adjuvant therapy in breast cancer patients, the incidence of MRONJ is reported to be 0%-0.27% compared to 0%-0.24% in controls^{73,75}. For ibandronate, an incidence of up to 1.94% has been reported when used in conjunction with endocrine therapy⁷⁷. (Supplementary Table 3)

4. Nonmalignant bone disease

In patients with giant cell tumor of bone receiving denosumab, the incidence of MRONJ is reported to vary widely, from 1%-13.8%⁷⁸⁻⁸¹. According to a systematic review, no cases of MRONJ were reported in 486 pediatric patients with osteogenesis imperfecta treated with BPs for 4.5-6.8 years⁸². Another systematic review also reported no cases of MRONJ in patients under 24 years of age who used BPs for various diseases^{83,84}. With the expansion of indications for antiresorptive agents, interest in the incidence of MRONJ in CTIBL and nonmalignant bone diseases is growing, but data are still limited, and further research is needed to clarify the risk in these conditions. (Supplementary Table 4)

5. Other medications associated with MRONJ

In addition to osteoporosis treatments, MRONJ can also be caused by steroids, immunomodulators, and anticancer drugs; lenalidomide, pomalidomide, sunitinib, imatinib, cabozantinib, sorafenib, bevacizumab, everolimus, temsirolimus, palbociclib, nivolumab, docetaxel, paclitaxel, methotrexate, letrozole, radium 223, prednisolone, and dexamethasone^{8,85}.

IV. Pathogenesis and Risk Factors

1. Pathogenesis

The pathogenesis of MRONJ is a complex, multifactorial process precipitated by the intersection of systemic pharmacological effects and the unique local vulnerabilities of the jawbone^{51,86}. The foundational mechanism is the profound suppression of bone remodeling induced by antiresorptive agents, which severely compromises the physiological capacity for skeletal repair and maintenance^{51,86}. This state of impaired bone turnover creates a systemic susceptibility, where local insults such as microbial infection, inflammation, or iatrogenic trauma can initiate a pathological cascade culminating in progressive, non-healing bone necrosis⁷. This process is amplified by a self-perpetuating cycle wherein suppressed repair, chronic infection, and a dysfunctional inflammatory response reinforce one another, leading to the refractory clinical presentation characteristic of MRONJ.

The jawbone is the principal, and often exclusive, site of MRONJ due to a confluence of distinct anatomical, metabolic, and environmental characteristics that render it uniquely vulnerable⁹. The alveolar bone of the mandible and maxilla possesses a metabolic turnover rate that is up to ten times higher than that of long bones. This heightened metabolic activity results in a disproportionately greater local accumulation of antiresorptive agents, particularly bone-seeking BPs, which leads to a more profound and localized suppression of remodeling where it is most needed to repair microdamage from masticatory forces^{8,87}. This pharmacologically compromised bone is covered by a thin, often friable, mucosal-periosteal barrier that is easily breached by dentoalveolar surgery, trauma from prosthetics, or chronic inflammatory

conditions like periodontitis. Such breaches provide a direct portal of entry for the complex oral microbiome, facilitating the establishment of persistent, low-grade infections by various organisms⁸⁸.

The primary pathogenic mechanisms are exacerbated by several synergistic factors. Drug-induced inhibition of angiogenesis, while mechanistically debated for certain drug classes, can further compromise the limited vascular supply to necrotic bone, impairing both nutrient delivery and immune cell trafficking^{88,89}. Concurrently, antiresorptive agents can induce immune dysregulation by altering macrophage polarization and T-cell function, which fosters a chronic, non-resolving inflammatory state rather than effective pathogen clearance⁷. Direct soft tissue toxicity from certain agents on oral keratinocytes and fibroblasts can delay mucosal healing, thereby perpetuating bone exposure⁹⁰. While several genetic polymorphisms have been investigated as potential predisposing factors, their role appears to be contributory rather than causative^{91,92}. Collectively, these factors converge on the uniquely susceptible jawbone to create the pathological cascade of MRONJ.

2. Risk factors

The risk of developing MRONJ is determined by a complex interplay of drug-related, local, and systemic factors¹¹. Key systemic and local co-factors that modify MRONJ risk are summarized in Table 2. A comprehensive risk assessment requires a thorough evaluation across all three domains to accurately stratify patients and guide preventive clinical strategies³.

While drug exposure and local trauma are primary determinants, a range of systemic and other local factors act as

Table 2. Summary of major risk factors for the development of MRONJ

Category	Risk factor
Drug-related	- High potency/IV route: Intravenous BPs (e.g., zoledronate), high-dose denosumab (120 mg). - Long duration of therapy: Cumulative exposure, especially >4 years for BPs.
Systemic	- Concomitant therapies: Systemic corticosteroids, antiangiogenic agents (e.g., bevacizumab), chemotherapy. - Demographics: Advanced age (>65 years). - Comorbidities: Malignancy (multiple myeloma, bone metastases), diabetes mellitus, rheumatoid arthritis, chronic kidney disease/dialysis, anemia, hypothyroidism.
Local	- Lifestyle: Smoking, obesity, poor oral hygiene. - Dentoalveolar surgery: Tooth extraction (most common trigger), dental implant placement, periapical surgery, periodontal surgery involving bone. - Pre-existing dental disease: Periodontitis, periapical pathology, dental abscesses. - Anatomical factors: Mandibular or palatal tori, prominent mylohyoid ridge. - Prosthetic trauma: Ill-fitting dentures causing chronic mucosal irritation.

(MRONJ: medication-related osteonecrosis of the jaw, IV: intravenous, BP: bisphosphonate)

Jin-Woo Kim et al: Medication-related osteonecrosis of the jaw: an evidence-based 2025 position statement from a Korean multidisciplinary task force. *J Korean Assoc Oral Maxillofac Surg* 2025

significant co-factors that compound a patient's overall risk profile²⁹. Tooth extraction remains the single most frequent trigger, precipitating up to 61% of all MRONJ cases⁹³. The risk is magnified when the procedure involves substantial bone trauma, such as osteotomy, or is performed in a site of pre-existing infection⁹⁴. A patient's systemic health status and concomitant medications also play a pivotal role⁹⁵.

1) Drug-related risk

The pharmacological profile of the antiresorptive therapy is the most critical determinant of MRONJ risk⁷. This risk is not a binary state but exists on a continuum modulated by the cumulative dose, duration of exposure, drug potency, and route of administration⁹⁶. Recent evidence indicates that risk increases progressively with the duration of therapy, particularly beyond 12 months of use, challenging earlier risk models based on fixed 3- or 4-year thresholds³⁸.

The clinical indication for therapy functions as a powerful risk multiplier⁹⁷. High-potency IV BPs, such as zoledronate, and high-dose denosumab regimens (120 mg monthly for oncologic indications) confer a substantially greater risk than lower-potency oral agents or low-dose osteoporosis regimens (e.g., denosumab 60 mg every 6 months)⁹⁸. Patients with malignancy not only receive drug dosages that are an order of magnitude higher and administered far more frequently, but they are also often exposed to synergistic risk factors, including concomitant corticosteroids, antiangiogenic agents, and chemotherapy¹¹. This convergence of factors results in an exponential, rather than merely additive, increase in overall risk, explaining why MRONJ incidence can be up to 100-fold higher in oncology populations (1%-15%) compared to osteoporosis populations (0.01%-0.10%)⁹⁹. Furthermore, switching from a BP to denosumab may also elevate risk due to the combined and cumulative suppressive effects on bone turnover⁴⁶.

2) Local risk factor

Dentoalveolar surgery is the most common precipitating event for MRONJ, and especially, tooth extraction and dental implant procedures represent a unique and significant category of iatrogenic risk⁹. The surgical trauma associated with implant placement, including osteotomy and flap elevation, can directly trigger necrosis¹⁰⁰. This risk is particularly acute in high-risk oncology patients, for whom elective implant therapy is generally considered contraindicated¹⁰¹. In low-risk osteoporosis patients, while evidence suggests that early implant failure rates are not significantly elevated, the potential

for MRONJ induction remains a critical consideration that necessitates thorough informed consent prior to the procedure¹⁰².

Furthermore, MRONJ can manifest years after successful implant osseointegration, a phenomenon termed "late implant-associated MRONJ."¹⁰³ This condition is pathologically distinct from conventional peri-implantitis, although it is often precipitated by it¹⁰⁴. Chronic inflammation at the implant-bone interface can breach the mucosal seal, introducing the oral microbiome to the pharmacologically compromised peri-implant bone¹⁰⁵. Consequently, the presence of an osseointegrated implant, particularly one with suboptimal oral hygiene, constitutes a long-term local risk factor that requires meticulous professional maintenance and patient surveillance¹⁰⁶.

V. Prevention of MRONJ

1. The critical role of pre-treatment dental evaluation and management

The most effective strategy for mitigating the risk of MRONJ is prevention^{28,107}. A cornerstone of this strategy is a comprehensive dental evaluation and the completion of any necessary dental treatment before a patient initiates high-risk antiresorptive therapy⁶. Numerous studies have demonstrated that implementing a preventive dental care protocol can significantly reduce the incidence of MRONJ^{108,109}. One meta-analysis reported that pre-treatment dental evaluation and preventive care reduced MRONJ incidence by 77.3% in cancer patients receiving high-dose BPs¹¹⁰.

The preventive protocol should include a thorough clinical and radiographic examination to identify and eliminate potential sources of infection and inflammation. Key management steps include³:

- Extraction of non-restorable teeth or teeth with a poor prognosis²⁸.
- Treatment of active periodontal and periapical disease¹⁰⁷.
- Adjustment or replacement of ill-fitting prostheses to prevent mucosal trauma⁹.
- Patient education on the importance of maintaining excellent oral hygiene and the signs and symptoms of MRONJ¹¹.

For patients scheduled to receive high-dose antiresorptives for oncologic indications, this dental evaluation is considered mandatory and should be completed ideally before therapy begins. For osteoporosis patients starting low-dose therapy, a pre-treatment evaluation is not essential but is strongly

recommended, either before treatment or within the first 6 months of initiation³.

2. Prophylactic drug holiday

The practice of temporarily discontinuing antiresorptive therapy before invasive dental procedures—a “prophylactic drug holiday”—remains one of the most controversial issues in MRONJ management⁷. In 2022, the AAOMS position paper—citing insufficient clinical evidence—deliberately offered no fixed time-based drug holiday recommendations, a change that has left many clinicians uncertain about how best to proceed⁷. In contrast, 2024 Italian position paper recommended that any prophylactic holiday for oral BP users be kept very short under 1 week⁹⁸.

Current evidence remains inconclusive on whether prophylactic drug holidays reduce MRONJ risk¹¹¹. A 2022 systematic review concluded that the available data are not strong enough to either support or refute the routine use of a drug holiday; in pooled analysis, the relative risk of MRONJ in patients who took a holiday was 0.73 (95% confidence interval: 0.51-1.06) compared to those who did not—a difference that was not statistically significant¹¹¹. Likewise, a systematic review in 2023 reported that short-term interruption of antiresorptive therapy prior to tooth extraction did not lower the incidence of MRONJ¹¹². However, a more recent study suggested that among patients with over 2 years of antiresorptive exposure, those who had a holiday of over 3 months experienced a significantly lower MRONJ risk than those with a holiday under 3 months¹¹³.

Interpreting these findings is complicated since many earlier studies pooled oral and IV BPs despite major pharmacokinetic differences between these agents¹¹⁴. For example, zoledronic acid has a much higher antiresorptive potency and

a far longer skeletal half-life than other BPs, a profile that could plausibly necessitate a more prolonged drug holiday¹¹⁵. Supporting this agent-specific perspective, a Korean nationwide cohort study of IV BP users found that MRONJ risk after a dental procedure began to decline around 90 days following the last ibandronate dose, whereas after zoledronate the risk did not begin to decrease until 6 months and only became significant after ≥ 1 year since the last dose¹¹⁶. Collectively, these data imply that if a drug holiday is considered, its optimal duration is likely to be drug-specific, reflecting differences in pharmacologic persistence and potency¹¹¹. Definitive guidance, however, will require prospective studies that balance any benefit in MRONJ risk reduction against the potential increase in fracture risk from interrupting therapy.

The Korean Multi-Society Task Force, recognizing this clinical need through its formal survey process, has developed a pragmatic, drug-specific guideline based on pharmacokinetic principles and expert consensus. This approach provides a structured framework that balances the theoretical benefit of reducing MRONJ risk with the distinct pharmacological profiles and systemic risks associated with each drug class. The committee’s recommendations are summarized in Table 3.

1) Recommendations for bisphosphonates

BPs have an extremely long skeletal retention, binding to bone and remaining present for months to years; this enduring presence complicates the concept of a meaningful drug holiday¹¹⁷. Nevertheless, the rationale for a temporary pause is that reducing or halting therapy may limit the amount of drug available at sites of active bone healing during the post-procedure remodeling phase¹¹⁶. For low risk patients with short exposure on BP and no additional risk factors, in general, no alteration of the antiresorptive regimen is necessary

Table 3. Prophylactic drug holiday recommendations before invasive dental procedures

Drug class	Recommended pre-procedure holiday	Recommended post-procedure healing period (wk)	Key clinical consideration
Bisphosphonates (alendronate, risedronate, and ibandronate PO & IV)	2 months (consider for patients with long-term use or other systemic risk factors)	6-8	Decision should be individualized based on fracture risk vs. MRONJ risk.
IV zoledronate	6-12 months	6-8	High potency and long skeletal retention necessitate a significantly longer holiday.
Denosumab	Perform dentoalveolar surgery 3-4 months after last injection	6-8	This timing minimizes both MRONJ risk and the risk of rebound vertebral fractures by fitting the procedure and healing within the 6-month dosing interval.

(PO: oral administration, IV: intravenous, MRONJ: medication-related osteonecrosis of the jaw)

Jin-Woo Kim et al. Medication-related osteonecrosis of the jaw: an evidence-based 2025 position statement from a Korean multidisciplinary task force. *J Korean Assoc Oral Maxillofac Surg* 2025

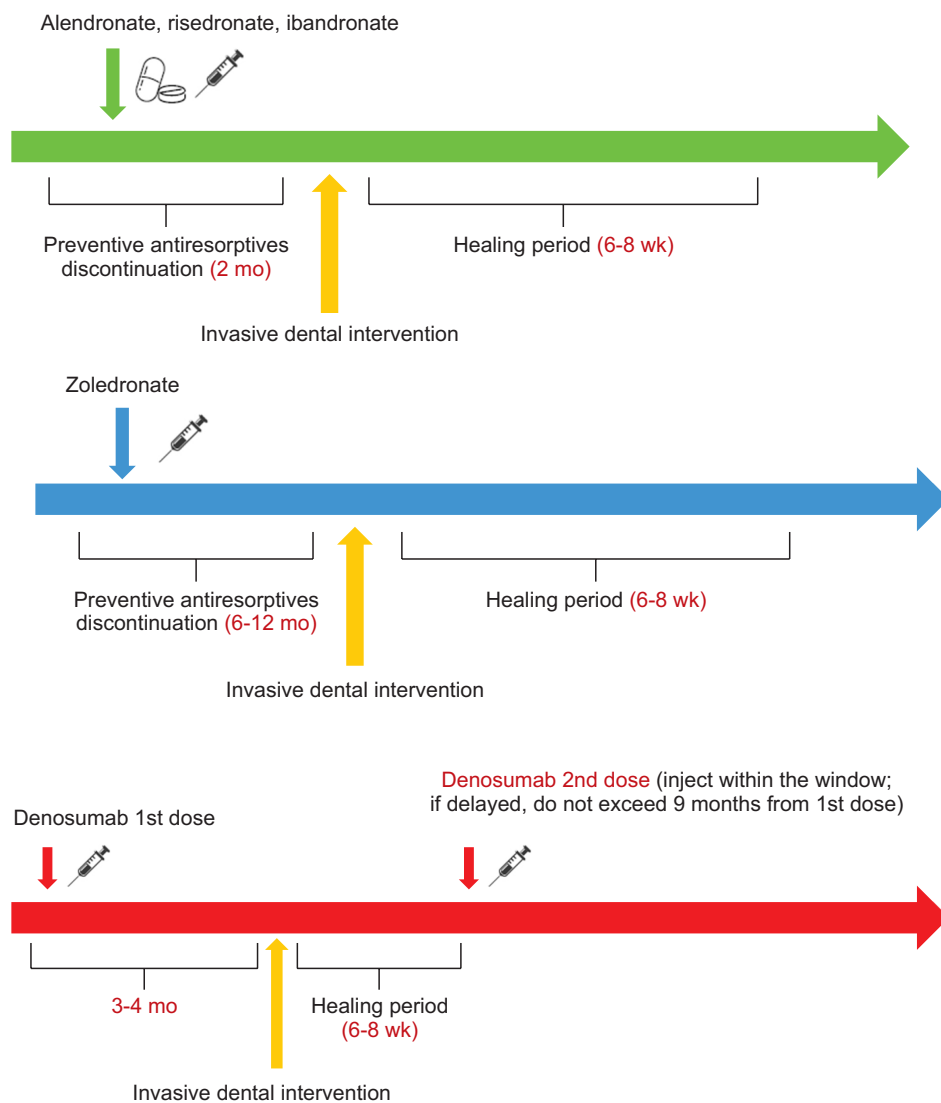


Fig. 1. Prophylactic drug holiday of bisphosphonate considering the medication-related osteonecrosis of the jaw risk. Jin-Woo Kim et al: Medication-related osteonecrosis of the jaw: an evidence-based 2025 position statement from a Korean multidisciplinary task force. J Korean Assoc Oral Maxillofac Surg 2025

Fig. 2. Denosumab administration and dental treatment considering risk of rebound fracture and medication-related osteonecrosis of the jaw risk. Jin-Woo Kim et al: Medication-related osteonecrosis of the jaw: an evidence-based 2025 position statement from a Korean multidisciplinary task force. J Korean Assoc Oral Maxillofac Surg 2025

prior to dental treatment. Invasive procedures can proceed without a drug holiday, though the patient should be informed (through an appropriate consent process) of the small long-term risk of implant failure or MRONJ.

- Alendronate, risedronate, ibandronate: For patients with prolonged BP therapy or significant risk factors, a drug holiday of 2 months before an invasive dental procedure may be considered.
- IV zoledronic acid: Owing to this drug’s high potency and prolonged effect, a substantially longer holiday of approximately 6-12 months is recommended before any elective invasive dental procedure. A recent Korean cohort study showed that MRONJ risk after zoledronate does not appreciably decline until at least 6 months (and is significantly reduced only after ≥ 12 months) since the last infusion¹¹⁶.
- Post-intervention period: Following a dental extraction

or other jaw surgery, resumption of BP therapy should be delayed for about 6-8 weeks to allow soft tissue and bone to heal without drug-related inhibition.

Any prophylactic drug holiday should be individualized based on the patient’s MRONJ risk and fracture risk, and planned with close communication between the dentist and the prescribing physician.(Fig. 1)

2) Recommendations for denosumab

Denosumab, unlike BPs, does not bind to bone. Its suppression of bone remodeling is reversible and dissipates within about 6 months after each injection⁴⁵. This pharmacokinetic characteristic makes the timing of invasive dental procedures in relation to denosumab dosing both more feasible and more critical¹¹⁸.(Fig. 2)

- Timing of intervention: Schedule invasive dental procedures ideally 3-4 months after the last denosumab dose.

At 3-4 months post-injection, the drug's effect on bone turnover has begun to decrease, while this timing still precedes the period of elevated risk for rebound vertebral fractures which typically starts around 6-9 months after an injection^{119,120}.

- Post-intervention period: Do not resume denosumab for approximately 6-8 weeks after intervention to allow proper mucosal and bony healing. By ensuring that the procedure and initial healing occur within a single 6-month dosing interval, this strategy minimizes the risk of rapid bone loss or fractures due to denosumab's rebound effect upon delayed dosing. If an extended drug holiday is necessary in a high-fracture-risk patient, consider interim therapy with a SERM (e.g. raloxifene) to partially mitigate the rebound effect, although this approach may not fully prevent it^{97,121,122}.

VI. Management of Established MRONJ and Recurrence

The treatment of established MRONJ is guided by the stage of the disease, with the primary goals being to eliminate pain, control infection, and prevent the progression of bone necrosis⁷. The committee's stage-based treatment recommendations are outlined in Table 1. Conservative, non-operative management is the foundation of treatment for all stages and may be the definitive therapy for early-stage disease⁷. This includes the use of antimicrobial mouth rinses (e.g., 0.12% chlorhexidine), systemic antibiotic therapy for stages with active infection (Stage 2 and 3), pain management, and debridement of loose bony sequestra^{6,7}.

While past guidelines often reserved surgical intervention for advanced, refractory disease (Stage 3), a paradigm shift has occurred based on accumulating evidence¹²³. Recent studies consistently demonstrate that surgical treatment yields significantly higher rates of complete and long-term resolution compared to conservative management alone¹²⁴⁻¹²⁷. Success rates for surgical resection are reported to be in the range of 60%-90%, whereas conservative therapy often results in disease stabilization at best, with complete healing rates reported from 0% to 54%^{124,125,128}. One study found that among 92 Stage 1 lesions managed conservatively, 91.3% still had exposed bone, and many progressed to a higher stage requiring eventual surgery¹²⁸.

Therefore, this committee recommends that surgical intervention should be considered for all stages of MRONJ, including Stage 1, particularly if the lesion persists or if the

patient's quality of life is affected¹²⁸. The surgical principle is the complete resection of all necrotic bone back to healthy, bleeding bone margins, followed by a tension-free primary soft tissue closure¹²⁹. Early surgical management can prevent the progression to more extensive lesions, reduce long-term morbidity, and improve patient quality of life¹²⁸.

1. Adjunctive therapies: the role of teriparatide and other modalities

- Teriparatide: Among various adjunctive therapies, teriparatide, a recombinant human parathyroid hormone analog (rhPTH[1-34]), has the most robust evidence supporting its use in MRONJ management¹³⁰⁻¹³⁶. As a bone anabolic agent, it stimulates bone formation and increases bone remodeling, directly counteracting the suppressed bone turnover state induced by antiresorptive drugs^{137,138}. A placebo-controlled, randomized trial demonstrated that a 6-month course of daily teriparatide (20 µg) significantly promoted the resolution of MRONJ lesions when combined with surgical treatment¹³⁰. Both daily and weekly formulations have shown efficacy^{139,140}. It is important to note, however, that transitioning from denosumab to teriparatide is generally not recommended for osteoporosis management due to a risk of transient bone density loss; therefore, its use in denosumab-related MRONJ requires careful multidisciplinary assessment of fracture risk¹¹⁸. (Supplementary Table 5)

- Other adjunctive therapies: Several other modalities have been explored to enhance healing in MRONJ, though the evidence for their efficacy is less compelling.

- Recombinant human bone morphogenetic protein-2: Can induce bone formation and may be beneficial when applied to surgical defects, particularly in combination with other carriers like platelet concentrates¹⁴¹⁻¹⁴³.

- Hyperbaric oxygen therapy: May promote angiogenesis and stimulate bone turnover, but clinical trials have shown mixed results, with no significant benefit over standard care in some studies¹⁴⁴.

- Low-level laser therapy: May aid in pain reduction and promote mucosal healing, but its effect on bone necrosis is limited, especially in advanced stages^{145,146}.

- Autologous platelet concentrates: Preparations like platelet-rich plasma and platelet-rich fibrin can be applied to surgical sites to deliver a high concentration of growth factors, potentially enhancing soft tissue and bone healing. However, systematic reviews have found

the evidence for their efficacy in treating or preventing MRONJ to be inconsistent¹⁴⁷⁻¹⁴⁹.

- Furthermore, preliminary studies on polydeoxyribonucleotide suggest it may be a promising agent for enhancing soft tissue and bone healing in MRONJ, warranting further investigation.

2. Therapeutic drug holiday and resumption of antiresorptive therapy

Once MRONJ is diagnosed, the decision of whether to continue or temporarily halt antiresorptive therapy—a “therapeutic drug holiday”—is complex. This decision places the localized need for jaw healing in direct conflict with the systemic risk of skeletal-related events (SREs) or osteoporotic fractures¹⁵⁰. The existing body of literature presents a divided view on the efficacy of a therapeutic drug holiday for established MRONJ¹¹. The conflicting findings are not arbitrary but rather reflect significant heterogeneity across studies in terms of patient populations (oncology versus osteoporosis), the specific antiresorptive agents used, and the primary treatment modalities employed for MRONJ¹⁵¹.

Several retrospective analyses and case series suggest a tangible benefit to discontinuing therapy. An analysis by Hinson et al.¹⁵² reported that patients who stopped BP treatment at the time of MRONJ diagnosis experienced symptom resolution approximately six months sooner than those who continued the medication. Similarly, a Korean retrospective study of 54 MRONJ patients found a statistically significant correlation between a longer drug holiday (median 9 months) and a more favorable prognosis following surgical treatment¹⁵³. Further supporting this view, a meta-analysis involving 13 clinical studies reported a substantially higher complete cure rate in patients who underwent a drug holiday (85%) compared to those who did not (56.4%)¹⁵⁴.

Conversely, an equally compelling set of studies has failed to demonstrate a significant correlation between drug discontinuation and improved MRONJ outcomes¹³². For instance, large retrospective studies from Japan, which analyzed outcomes in both osteoporosis and oncology patients, found that drug holidays of various durations (ranging from 60 to 180 days) did not lead to better surgical results¹⁵⁵. Other clinical reports have similarly concluded that discontinuing potent agents like zoledronate or denosumab did not resolve established MRONJ lesions¹⁵⁶. These disparate findings highlight that the potential benefit of a drug holiday is likely influenced by a confluence of factors, including the underlying dis-

ease, the specific drug’s pharmacology, and the stage of the MRONJ lesion¹⁵⁷.

The decision to implement a therapeutic holiday must be informed by the distinct pharmacological properties of BPs and denosumab⁸⁶. BPs are characterized by their extremely long skeletal retention; they bind avidly to hydroxyapatite and can remain embedded in the bone matrix for months to years¹²⁰. This prolonged biological presence means that even after therapy is discontinued, the drug continues to exert its antiresorptive effects locally¹¹. Consequently, the biological impact of a short-term drug holiday on the healing of an established MRONJ lesion is likely limited. While some position papers suggest a modest benefit, the prevailing view, grounded in pharmacokinetics, is that discontinuation offers a marginal, if any, immediate advantage for healing⁷. Nonetheless, a short-term perioperative discontinuation as suggested in Italian guidelines⁹⁸, may be considered a pragmatic strategy to limit the accumulation of additional drug at a surgical site during the critical healing phase, even if this approach is not supported by robust evidence.

Unlike BPs, denosumab does not bind to bone, and its potent antiresorptive effect is fully reversible, dissipating within approximately six months of the last injection¹²⁰. While this reversibility theoretically creates an opportunity for a drug holiday to facilitate jaw healing, it is inextricably linked to a risk of rebound fractures¹¹⁹. Cessation of denosumab leads to a rapid surge in bone turnover that overshoots baseline levels, resulting in accelerated bone loss and a high risk of multiple, spontaneous fractures¹¹⁹.

1) Recommendations for resumption of therapy

Given the clinical equipoise and the need for practical guidance, the decision to halt or continue therapy must be individualized, weighing the severity and symptoms of the MRONJ lesion against the patient’s systemic risk for fractures or SREs.

A foundational principle is the establishment of a minimum post-operative healing period. Following surgical intervention for MRONJ, the committees recommend to delay the resumption of any antiresorptive therapy for a minimum of 6-8 weeks. This period allows for initial soft tissue epithelialization and maturation, providing a window for healing without the inhibitory effects of the medication⁹.

For high risk patients with oncologic disease receiving high-dose therapy or osteoporosis patients with a very high imminent fracture risk, antiresorptive therapy should be resumed promptly after the initial 6-8 week healing period is

Table 4. Therapeutic drug holiday and resumption recommendations for MRONJ treatment

Patient risk group	Recommended minimum healing period (wk)	Criteria for resuming medication
High-risk patients (e.g., patients with oncologic disease, very high imminent fracture risk)	6-8	Resume promptly after the initial healing period upon confirmation of stable soft tissue coverage.
Lower-risk patients (e.g., osteoporosis patients with a lower fracture risk)	6-8	Consider extending the holiday until complete clinical and radiographic resolution of the MRONJ lesion.
Patients on denosumab	6-8	Any planned delay should not exceed 3 months from the originally scheduled date (i.e., a maximum of 9 months from the last injection).

(MRONJ: medication-related osteonecrosis of the jaw)

Jin-Woo Kim et al: Medication-related osteonecrosis of the jaw: an evidence-based 2025 position statement from a Korean multidisciplinary task force. *J Korean Assoc Oral Maxillofac Surg* 2025

complete and stable soft tissue coverage is confirmed. The primary goal is to minimize the duration of systemic skeletal vulnerability¹⁵⁸. For osteoporosis patients with a lower fracture risk, a more extended therapeutic holiday, potentially until the MRONJ lesion has demonstrated complete clinical and radiographic resolution, may be considered¹²⁰.

For patients on denosumab, a highly specific guideline is necessary to mitigate the risk of rebound phenomena. Any planned delay in the next scheduled dose to facilitate MRONJ treatment should not exceed 3 months from the originally scheduled date. This corresponds to a maximum interval of 9 months from the last injection¹¹⁸. (Table 4)

3. Risk factors for recurrence

Despite successful initial treatment, MRONJ has a significant rate of recurrence. The most significant predictors of recurrence are associated with the intensity of the antiresorptive therapy and the patient's underlying disease state. The cumulative dose and duration of antiresorptive therapy are strongly correlated with recurrence risk. For potent agents like zoledronate, continuous use for over 18 months has been identified as a significant risk factor. Perhaps the most critical and modifiable factor is the early resumption of antiresorptive therapy after the initial MRONJ lesion has been treated. A 13-year cohort study from Hong Kong provides a compelling illustration: the only two cases of recurrence occurred in patients who resumed potent antiresorptive therapy within months of treatment¹⁵⁹. This suggests that an aggressive resumption of therapy can directly trigger a recurrence.

The clinical presentation of the initial MRONJ episode is also predictive. Patients who present with an advanced stage of disease (Stage 2 or 3) are at a higher risk of recurrence compared to those with Stage 1 lesions. Furthermore, lesions located in the maxilla have been consistently associated with

a greater likelihood of recurrence. Finally, the underlying diagnosis remains a powerful determinant; patients receiving high-dose IV therapy for metastatic bone disease have a significantly higher recurrence risk than osteoporosis patients on low-dose regimens. This is likely a reflection of the synergistic effect of higher drug potency, longer duration, and the frequent use of concomitant corticosteroids or chemotherapy in the oncology setting.

While pharmacological factors create systemic susceptibility, the primary local driver of recurrence is the incomplete surgical resection of necrotic bone during the initial treatment. This observation suggests that many instances of "recurrence" are not truly new disease events but rather the clinical manifestation of a persistent, inadequately treated primary lesion. The boundary between necrotic, non-remodeling bone and healthy, viable bone is often difficult to discern with the naked eye, leading to the unintentional retention of microscopic foci of compromised bone. These residual areas can act as a nidus for subsequent infection and breakdown, leading to clinical recurrence months or years later. To help address this surgical challenge, emerging technologies such as biofluorescence-guided systems are being investigated as intraoperative adjuncts to aid in the differentiation of viable bone from necrotic margins.

This concept is supported by multiple lines of evidence. Studies have shown significantly higher recurrence rates in patients with postoperative radiographic evidence of residual osteolysis or irregular periosteal reactions¹. Furthermore, patients who undergo a conservative debridement or marginal resection have a recurrence rate that is three to four times higher than those who receive a complete resection with wide, healthy margins¹. This reframes the problem of recurrence from being an inherent patient characteristic to being, in large part, a consequence of the initial treatment's thoroughness. It places immense importance on optimizing the

primary surgical intervention.

4. Strategies for recurrence prevention and management

Preventing MRONJ recurrence requires a multi-pronged, proactive strategy that begins with comprehensive initial treatment and extends to careful, personalized long-term pharmacological management. The most effective way to prevent recurrence is to ensure the complete and definitive resolution of the primary MRONJ episode.

Thorough Primary Treatment reinforces the recommendation for early and aggressive surgical intervention. The goal should be a complete resection of all non-viable bone with sufficiently wide margins to reach healthy, bleeding bone, thereby removing the nidus for potential recurrence. Evidence consistently shows that this approach yields higher rates of complete mucosal healing and lower recurrence rates compared to more conservative methods.

The implementation of a standardized pre- and post-operative antibiotic protocol has been shown to be an effective adjunctive measure. Studies have reported that the use of perioperative antibiotics can reduce MRONJ recurrence rates from approximately 30%-35% to 18%-20%^{3,160}. After an MRONJ episode has been treated, regular oral examinations at 6- to 12-month intervals are crucial for detecting any early signs of recurrence, allowing for prompt intervention.

It is crucial to establish an optimal treatment plan by comprehensively considering the patient's underlying disease, the specific medication used, and the duration of therapy^{161,162}. For instance, this may involve shortening the duration of zoledronate administration or implementing continuous monitoring for high-risk patients¹⁶³.

According to recent reports, switching to teriparatide monotherapy is not a panacea for MRONJ that develops during denosumab treatment¹⁶⁴. As recommended in the guidelines for atypical femoral fractures¹⁶⁵, an alternative strategy such as sequential therapy with teriparatide followed by raloxifene may be considered to minimize recurrence after MRONJ treatment. However, upon discontinuing denosumab and transitioning to teriparatide, different patterns of change in spine and hip bone mineral density are observed; therefore, DXA follow-up at 6-month intervals is recommended¹¹⁸. A strategy of switching to alendronate or raloxifene after discontinuing denosumab¹⁶⁶ contributes to the maintenance of systemic BMD but may offer limited hip protection, warranting caution in high-risk patients.

In the previously report from Hong Kong¹⁵⁹, 7 out of 8 pa-

tients (87.5%) who underwent sequential therapy transitioning from teriparatide to raloxifene (for 18-24 months) after an MRONJ episode showed stabilization or improvement in BMD, with no reported recurrences. Conversely, two patients who immediately resumed treatment with an antiresorptive agent of the same class following MRONJ treatment both experienced recurrence. Therefore, for patients with a relatively low fracture risk (T-score >-2.5 or FRAX major osteoporotic fracture risk <20%), a short-term drug holiday or low-dose/intermittent therapy should be considered first. For high-risk patients, an approach that manages fracture risk while avoiding excessive re-administration, such as teriparatide-based sequential therapy, may be considered.

VII. Conclusion and Future Directions

This 2025 Korean Position Statement on MRONJ was developed to provide clear, evidence-based, and clinically practical guidelines for a growing health concern. The committee, representing five key medical and dental societies, has established a consensus that emphasizes a proactive and comprehensive approach. Key recommendations include:

- (1) Definition and staging: Adherence to the standard diagnostic criteria, with the crucial addition of allowing diagnosis based on definitive radiographic or clinical findings prior to 8 weeks, and the retention of Stage 0 to facilitate early detection.
- (2) Prevention: A strong emphasis on pre-treatment dental evaluation and management as the most effective preventive measure.
- (3) Prophylactic drug holidays: Provision of specific, drug-class-dependent recommendations for temporary discontinuation of antiresorptives around invasive dental procedures, offering pragmatic guidance where international consensus is lacking (see IV. Pathogenesis and Risk Factors, 1. Pathogenesis for details).
- (4) Treatment: Early surgical intervention can be recommended as the primary treatment modality for all stages of MRONJ, based on superior long-term resolution rates.
- (5) Recurrence: Identification of key risk factors and advocacy for personalized post-treatment management, including advanced sequential therapy strategies for high-risk patients.

1. Identifying knowledge gaps and proposing a research agenda

Despite significant advances, many questions regarding MRONJ remain unanswered. This committee has identified several key areas that require future research to further refine clinical practice:

- **Prospective comparative studies:** There is a pressing need for large-scale, prospective cohort studies to directly compare the long-term outcomes (resolution, recurrence, quality of life) of different treatment strategies, including conservative vs. surgical management and the efficacy of various adjunctive therapies.
- **Biomarker discovery:** Research is needed to identify and validate reliable blood or salivary biomarkers that can accurately predict an individual's risk of developing MRONJ or experiencing a recurrence. Such markers would enable truly personalized risk stratification and management.
- **Long-term impact of drug holidays:** The long-term effects of both prophylactic and therapeutic drug holidays on systemic outcomes—namely, fracture risk and cancer progression—are not well understood. Multidisciplinary, long-term follow-up studies are essential to clarify the risk-benefit balance.
- **Risk of newer agents:** While this paper focuses on BPs and denosumab, the MRONJ risk associated with newer osteoporosis medications, such as romosozumab, needs to be evaluated in large, prospective clinical studies.
- **Pharmacogenomics:** Investigating the genetic basis of MRONJ susceptibility is a critical frontier. Identifying genetic polymorphisms related to bone metabolism, immunity, or angiogenesis could allow for the screening of high-risk individuals and the development of personalized preventive strategies.

It is the hope of this committee that these guidelines will standardize and improve the care of patients with MRONJ, and that the proposed research agenda will stimulate further investigation to address the remaining uncertainties in this complex field.

ORCID

Jin-Woo Kim, <https://orcid.org/0000-0002-1672-5730>

Sung-Hye Kong, <https://orcid.org/0000-0002-8791-0909>

Jae-Young Kim, <https://orcid.org/0000-0002-9423-438X>

Mi Kyung Kwak, <https://orcid.org/0000-0002-8092-2560>

Jun-Young Kim, <https://orcid.org/0000-0002-6596-6135>

Ji-Hyeon Oh, <https://orcid.org/0000-0002-6050-7175>

Hyung-Youl Park, <https://orcid.org/0000-0002-0084-8867>

BeomTaek Kim, <https://orcid.org/0000-0002-0395-0410>

Young-Kyun Lee, <https://orcid.org/0000-0001-6564-4294>

Jeong Joon Han, <https://orcid.org/0000-0001-8975-0198>

Moon-Young Kim, <https://orcid.org/0000-0001-9596-7481>

Yong Jun Choi, <https://orcid.org/0000-0003-3960-8470>

Yong-Dae Kwon, <https://orcid.org/0000-0001-9620-4814>

Kwang-Sup Song, <https://orcid.org/0000-0002-9238-8908>

Beom-Jun Kim, <https://orcid.org/0000-0001-8591-1759>

Sun-Jong Kim, <https://orcid.org/0000-0003-3659-2848>

Seung-Hoon Baek, <https://orcid.org/0000-0002-8909-3287>

Dong Ock Lee, <https://orcid.org/0000-0002-9009-3508>

Han Seok Choi, <https://orcid.org/0000-0002-6506-4342>

Ha Young Kim, <https://orcid.org/0000-0002-0651-2213>

Tae-Geon Kwon, <https://orcid.org/0000-0003-2799-0510>

Authors' Contributions

J.W.K., D.O.L., H.S.C., H.Y.K., and T.G.K. were responsible for the conception and design of the study. S.H.K., J.Y.K., M.K.K., J.Y.K., J.H.O., H.Y.P., B.T.K., Y.L., J.J.H., M.Y.K., Y.J.C., Y.D.K., K.S.S., B.J.K., S.J.K., and S.H.B. contributed to the acquisition, analysis, and interpretation of data. All authors participated in drafting the manuscript or revising it critically for important intellectual content, and all authors approved the final manuscript.

Funding

No funding to declare.

Acknowledgements

The authors gratefully acknowledge the support and encouragement of the following presidents for the medication-related osteonecrosis of the jaw (MRONJ) Position Meeting: Ki-Hyun Baek (Korean Society for Bone and Mineral Research), Boo-Kyu Lee (Korean Association of Oral and Maxillofacial Surgeons), Jung-Keun Lee (Korean Association of Maxillofacial Plastic and Reconstructive Surgeons), Yoon-Sok Chung (Korean Endocrine Society), and Hee-Dong Chae (Korean Society of Osteoporosis).

Society endorsement and editorial coordination: This consensus statement was developed under the auspices of the participating five societies and submitted with a request for

coordinated co-publication. We thank both editorial offices for their cooperation in ensuring accurate and simultaneous dissemination to both medical and surgical communities.

Supplementary Materials

Supplementary data is available at <https://www.jkaoms.org>.

Conflict of Interest

No potential conflict of interest relevant to this article was reported.

References

1. Korea Disease Control and Prevention Agency (KDCA). Korea National Health and Nutrition Examination Survey 2022 (KNHANES IX-1). KDCA; 2022.
2. Korean Society for Bone and Mineral Research (KSBMR). Osteoporosis and osteoporotic fracture: FACT SHEET 2023. KSBMR; 2023.
3. Kim JW, Kwak MK, Han JJ, Lee ST, Kim HY, Kim SH, et al. Medication related osteonecrosis of the jaw: 2021 position statement of the Korean Society for Bone and Mineral Research and the Korean Association of Oral and Maxillofacial Surgeons. *J Bone Metab* 2021;28:279-96. <https://doi.org/10.11005/jbm.2021.28.4.279>
4. National Health Insurance Service Ilsan Hospital. Analysis of trends and factors of medication-related osteonecrosis of the jaw in osteoporosis patients treated with bisphosphonates or denosumab in dental care (Research Report NHIMC-2022-PR-023) [Internet]. Goyang: National Health Insurance Service Ilsan Hospital [cited 2025 Nov 18]. Available from: <https://repository.nhmc.or.kr/bitstream/2023.oak/263/2/NHIMC-2022-PR-023.pdf>
5. Advisory Task Force on Bisphosphonate-Related Osteonecrosis of the Jaws, American Association of Oral and Maxillofacial Surgeons. American Association of Oral and Maxillofacial Surgeons position paper on bisphosphonate-related osteonecrosis of the jaws. *J Oral Maxillofac Surg* 2007;65:369-76. <https://doi.org/10.1016/j.joms.2006.11.003>
6. Ruggiero SL, Dodson TB, Fantasia J, Goodday R, Aghaloo T, Mehrotra B, et al.; American Association of Oral and Maxillofacial Surgeons. American Association of Oral and Maxillofacial Surgeons position paper on medication-related osteonecrosis of the jaw--2014 update. *J Oral Maxillofac Surg* 2014;72:1938-56. <https://doi.org/10.1016/j.joms.2014.04.031>
7. Ruggiero SL, Dodson TB, Aghaloo T, Carlson ER, Ward BB, Kademani D. American Association of Oral and Maxillofacial Surgeons' position paper on medication-related osteonecrosis of the jaws--2022 update. *J Oral Maxillofac Surg* 2022;80:920-43. <https://doi.org/10.1016/j.joms.2022.02.008>
8. Kim KM, Rhee Y, Kwon YD, Kwon TG, Lee JK, Kim DY. Medication related osteonecrosis of the jaw: 2015 position statement of the Korean Society for Bone and Mineral Research and the Korean Association of Oral and Maxillofacial Surgeons. *J Bone Metab* 2015;22:151-65. <https://doi.org/10.11005/jbm.2015.22.4.151>
9. Yoneda T, Hagino H, Sugimoto T, Ohta H, Takahashi S, Soen S, et al. Antiresorptive agent-related osteonecrosis of the jaw: position paper 2017 of the Japanese Allied Committee on Osteonecrosis of the Jaw. *J Bone Miner Metab* 2017;35:6-19. <https://doi.org/10.1007/s00774-016-0810-7>
10. Colella G, Campisi G, Fusco V. American Association of Oral and Maxillofacial Surgeons position paper: bisphosphonate-related osteonecrosis of the jaws-2009 update: the need to refine the BRONJ definition. *J Oral Maxillofac Surg* 2009;67:2698-9. <https://doi.org/10.1016/j.joms.2009.07.097>
11. Khan AA, Morrison A, Hanley DA, Felsenberg D, McCauley LK, O'Ryan F, et al.; International Task Force on Osteonecrosis of the Jaw. Diagnosis and management of osteonecrosis of the jaw: a systematic review and international consensus. *J Bone Miner Res* 2015;30:3-23. <https://doi.org/10.1002/jbmr.2405>
12. Klingelhöffer C, Klingelhöffer M, Müller S, Ettl T, Wahlmann U. Can dental panoramic radiographic findings serve as indicators for the development of medication-related osteonecrosis of the jaw? *Dentomaxillofac Radiol* 2016;45:20160065. <https://doi.org/10.1259/dmfr.20160065>
13. Arce K, Assael LA, Weissman JL, Markiewicz MR. Imaging findings in bisphosphonate-related osteonecrosis of jaws. *J Oral Maxillofac Surg* 2009;67(5 Suppl):75-84. <https://doi.org/10.1016/j.joms.2008.12.002>
14. Ko YY, Yang WF, Leung YY. The role of cone beam computed tomography (CBCT) in the diagnosis and clinical management of medication-related osteonecrosis of the jaw (MRONJ). *Diagnostics* (Basel) 2024;14:1700. <https://doi.org/10.3390/diagnostics14161700>
15. Guggenberger R, Fischer DR, Metzler P, Andreisek G, Nanz D, Jacobsen C, et al. Bisphosphonate-induced osteonecrosis of the jaw: comparison of disease extent on contrast-enhanced MR imaging, [18F] fluoride PET/CT, and conebeam CT imaging. *AJNR Am J Neuroradiol* 2013;34:1242-7. <https://doi.org/10.3174/ajnr.a3355>
16. Arijji Y, Arijji E. Role of magnetic resonance imaging in diagnosis of bisphosphonate-related osteonecrosis of the jaw. *Oral Radiol* 2013;29:111-20. <https://doi.org/10.1007/s11282-013-0124-6>
17. Dore F, Filippi L, Biasotto M, Chiandussi S, Cavalli F, Di Lenarda R. Bone scintigraphy and SPECT/CT of bisphosphonate-induced osteonecrosis of the jaw. *J Nucl Med* 2009;50:30-5. <https://doi.org/10.2967/jnumed.107.048785>
18. Ogura I, Kobayashi E, Nakahara K, Igarashi K, Haga-Tsujimura M, Toshima H. Quantitative SPECT/CT imaging for medication-related osteonecrosis of the jaw: a preliminary study using volume-based parameters, comparison with chronic osteomyelitis. *Ann Nucl Med* 2019;33:776-82. <https://doi.org/10.1007/s12149-019-01390-5>
19. Toshima H, Ogura I. Assessment of inflammatory jaw pathologies using bone SPECT/CT maximum standardized uptake value. *Dentomaxillofac Radiol* 2020;49:20200043. <https://doi.org/10.1259/dmfr.20200043>
20. Park JH, Yoon DM, Yoon HJ, Kim JW. Utility of quantitative standardized uptake value from pre-operative bone SPECT/CT for predicting post-surgical MRONJ healing response. *EJNMMI Res* 2025;15:29. <https://doi.org/10.1186/s13550-025-01220-y>
21. Marx RE, Cillo JE Jr, Ulloa JJ. Oral bisphosphonate-induced osteonecrosis: risk factors, prediction of risk using serum CTX testing, prevention, and treatment. *J Oral Maxillofac Surg* 2007;65:2397-410. <https://doi.org/10.1016/j.joms.2007.08.003>
22. Awad ME, Sun C, Jernigan J, Elsalanty M. Serum C-terminal cross-linking telopeptide level as a predictive biomarker of osteonecrosis after dentoalveolar surgery in patients receiving bisphosphonate therapy: systematic review and meta-analysis. *J Am Dent Assoc* 2019;150:664-75.e8. <https://doi.org/10.1016/j.adaj.2019.03.006>
23. Traboulsi-Garet B, Jorba-García A, Camps-Font O, Alves FA, Figueiredo R, Valmaseda-Castellón E. Is serum C-terminal telopeptide cross-link of type I collagen a reliable parameter for predicting the risk of medication-related osteonecrosis of the jaws? A systematic review and meta-analysis of diagnostic test accuracy. *Clin Oral Investig* 2022;26:2371-82. <https://doi.org/10.1007/s00784-022-04383-3>

24. Kim JW, Kong KA, Kim SJ, Choi SK, Cha IH, Kim MR. Prospective biomarker evaluation in patients with osteonecrosis of the jaw who received bisphosphonates. *Bone* 2013;57:201-5. <https://doi.org/10.1016/j.bone.2013.08.005>
25. Park JH, Cho S, Kim SJ, Jeong TD, Mun YC, Kim JW. Serum biomarkers for bisphosphonate-related osteonecrosis of the jaw: a prospective clinical study. *Osteoporos Int* 2022;33:367-77. <https://doi.org/10.1007/s00198-021-06137-5>
26. Kim JW, Cha IH, Kim SJ, Kim MR. Biomarkers for bisphosphonate-related osteonecrosis of the jaw. *Clin Implant Dent Relat Res* 2016;18:281-91. <https://doi.org/10.1111/cid.12297>
27. Lorenzo-Pouso AI, Pérez-Sayáns M, González-Palanca S, Chamorro-Petronacci C, Bagán J, García-García A. Biomarkers to predict the onset of bisphosphonate-related osteonecrosis of the jaw: a systematic review. *Med Oral Patol Oral Cir Bucal* 2019;24:e26-36. <https://doi.org/10.4317/medoral.22763>
28. Ruggiero S, Gralow J, Marx RE, Hoff AO, Schubert MM, Huryn JM, et al. Practical guidelines for the prevention, diagnosis, and treatment of osteonecrosis of the jaw in patients with cancer. *J Oncol Pract* 2006;2:7-14. <https://doi.org/10.1200/jop.2006.2.1.7>
29. Kawahara M, Kuroshima S, Sawase T. Clinical considerations for medication-related osteonecrosis of the jaw: a comprehensive literature review. *Int J Implant Dent* 2021;7:47. <https://doi.org/10.1186/s40729-021-00323-0>
30. Gaêta-Araujo H, Vanderhaeghen O, Vasconcelos KF, Coucke W, Coropciuc R, Politis C, et al. Osteomyelitis, osteoradionecrosis, or medication-related osteonecrosis of the jaws? Can CBCT enhance radiographic diagnosis? *Oral Dis* 2021;27:312-9. <https://doi.org/10.1111/odi.13534>
31. Patel S, Choyee S, Uyanne J, Nguyen AL, Lee P, Sedghizadeh PP, et al. Non-exposed bisphosphonate-related osteonecrosis of the jaw: a critical assessment of current definition, staging, and treatment guidelines. *Oral Dis* 2012;18:625-32. <https://doi.org/10.1111/j.1601-0825.2012.01911.x>
32. Schiodt M, Otto S, Fedele S, Bedogni A, Nicolatou-Galitis O, Guggenberger R, et al. Workshop of European task force on medication-related osteonecrosis of the jaw-Current challenges. *Oral Dis* 2019;25:1815-21. <https://doi.org/10.1111/odi.13160>
33. Fedele S, Bedogni G, Scoletta M, Favia G, Colella G, Agrillo A, et al. Up to a quarter of patients with osteonecrosis of the jaw associated with antiresorptive agents remain undiagnosed. *Br J Oral Maxillofac Surg* 2015;53:13-7. <https://doi.org/10.1016/j.bjoms.2014.09.001>
34. Grbic JT, Black DM, Lyles KW, Reid DM, Orwoll E, McClung M, et al. The incidence of osteonecrosis of the jaw in patients receiving 5 milligrams of zoledronic acid: data from the health outcomes and reduced incidence with zoledronic acid once yearly clinical trials program. *J Am Dent Assoc* 2010;141:1365-70. <https://doi.org/10.14219/jada.archive.2010.0082>
35. Tennis P, Rothman KJ, Bohn RL, Tan H, Zavras A, Laskarides C, et al. Incidence of osteonecrosis of the jaw among users of bisphosphonates with selected cancers or osteoporosis. *Pharmacoepidemiol Drug Saf* 2012;21:810-7. <https://doi.org/10.1002/pds.3292>
36. Lee JK, Kim KW, Choi JY, Moon SY, Kim SG, Kim CH, et al. Bisphosphonates-related osteonecrosis of the jaw in Korea: a preliminary report. *J Korean Assoc Oral Maxillofac Surg* 2013;39:9-13. <https://doi.org/10.5125/jkaoms.2013.39.1.9>
37. Kim SH, Lee YK, Kim TY, Ha YC, Jang S, Kim HY. Incidence of and risk for osteonecrosis of the jaw in Korean osteoporosis patients treated with bisphosphonates: a nationwide cohort-study. *Bone* 2021;143:115650. <https://doi.org/10.1016/j.bone.2020.115650>
38. Park JH, Kwoen MJ, Lee JR, Kim KS, Lee HJ, Kim JW, et al. Gradual, but not sudden, dose-dependent increase of ONJ risk with bisphosphonate exposure: a nationwide cohort study in women with osteoporosis. *Front Endocrinol (Lausanne)* 2021;12:774820. <https://doi.org/10.3389/fendo.2021.774820>
39. Kim HY, Kim JW, Kim SJ, Lee SH, Lee HS. Uncertainty of current algorithm for bisphosphonate-related osteonecrosis of the jaw in population-based studies: a systematic review. *J Bone Miner Res* 2017;32:584-91. <https://doi.org/10.1002/jbmr.3017>
40. Wang Q, Yu Q, Zeng P, Ai W. Efficacy and safety of annual infusion of zoledronic acid and weekly oral alendronate in the treatment of primary osteoporosis: a meta-analysis. *J Clin Pharmacol* 2023;63:455-65. <https://doi.org/10.1002/jcph.2181>
41. Lo JC, O'Ryan FS, Gordon NP, Yang J, Hui RL, Martin D, et al.; Predicting Risk of Osteonecrosis of the Jaw with Oral Bisphosphonate Exposure (PROBE) Investigators. Prevalence of osteonecrosis of the jaw in patients with oral bisphosphonate exposure. *J Oral Maxillofac Surg* 2010;68:243-53. <https://doi.org/10.1016/j.joms.2009.03.050>
42. Grbic JT, Landesberg R, Lin SQ, Mesenbrink P, Reid IR, Leung PC, et al.; Health Outcomes and Reduced Incidence with Zoledronic Acid Once Yearly Pivotal Fracture Trial Research Group. Incidence of osteonecrosis of the jaw in women with postmenopausal osteoporosis in the health outcomes and reduced incidence with zoledronic acid once yearly pivotal fracture trial. *J Am Dent Assoc* 2008;139:32-40. <https://doi.org/10.14219/jada.archive.2008.0017>
43. Sieber P, Lardelli P, Kraenzlin CA, Kraenzlin ME, Meier C. Intravenous bisphosphonates for postmenopausal osteoporosis: safety profiles of zoledronic acid and ibandronate in clinical practice. *Clin Drug Investig* 2013;33:117-22. <https://doi.org/10.1007/s40261-012-0041-1>
44. Clark ASE, Glenny AM. The issue with incidence: a scoping review of reported medication-related osteonecrosis of the jaws (MRONJ) incidence around the globe. *BMJ Public Health* 2025;3:e002009. <https://doi.org/10.1136/bmjph-2024-002009>
45. Bone HG, Wagman RB, Brandi ML, Brown JP, Chapurlat R, Cummings SR, et al. 10 years of denosumab treatment in postmenopausal women with osteoporosis: results from the phase 3 randomised FREEDOM trial and open-label extension. *Lancet Diabetes Endocrinol* 2017;5:513-23. [https://doi.org/10.1016/s2213-8587\(17\)30138-9](https://doi.org/10.1016/s2213-8587(17)30138-9)
46. Liu FC, Luk KC, Chen YC. Risk comparison of osteonecrosis of the jaw in osteoporotic patients treated with bisphosphonates vs. denosumab: a multi-institutional retrospective cohort study in Taiwan. *Osteoporos Int* 2023;34:1729-37. <https://doi.org/10.1007/s00198-023-06818-3>
47. Everts-Graber J, Lehmann D, Burkard JP, Schaller B, Gahl B, Häuselmann H, et al. Risk of osteonecrosis of the jaw under denosumab compared to bisphosphonates in patients with osteoporosis. *J Bone Miner Res* 2022;37:340-8. <https://doi.org/10.1002/jbmr.4472>
48. Watts NB, Grbic JT, Binkley N, Papapoulos S, Butler PW, Yin X, et al. Invasive oral procedures and events in postmenopausal women with osteoporosis treated with denosumab for up to 10 years. *J Clin Endocrinol Metab* 2019;104:2443-52. <https://doi.org/10.1210/je.2018-01965>
49. Williams DW, Lee C, Kim T, Yagita H, Wu H, Park S, et al. Impaired bone resorption and woven bone formation are associated with development of osteonecrosis of the jaw-like lesions by bisphosphonate and anti-receptor activator of NF- κ B ligand antibody in mice. *Am J Pathol* 2014;184:3084-93. <https://doi.org/10.1016/j.ajpath.2014.07.010>
50. Száraz D, Peřina V, Treglerová J, Macháček C, Zendulka O, Bořilová Linhartová P. Case report: single low-dose of denosumab as a trigger of MRONJ development in a patient with osteoporosis after bisphosphonate therapy. *Front Oral Health* 2024;5:1473049. <https://doi.org/10.3389/froh.2024.1473049>
51. Lee K, Kim K, Kim JY, Kim JW, Kang YH, Kim YH, et al. Mechanisms underlying medication-related osteonecrosis of the jaw. *Oral Dis* 2025;31:1073-83. <https://doi.org/10.1111/odi.15198>
52. Cosman F, Crittenden DB, Adachi JD, Binkley N, Czerwinski E, Ferrari S, et al. Romosozumab treatment in postmenopausal wom-

- en with osteoporosis. *N Engl J Med* 2016;375:1532-43. <https://doi.org/10.1056/nejmoa1607948>
53. Cosman F, Crittenden DB, Ferrari S, Lewiecki EM, Jaller-Raad J, Zerbin C, et al. Romosozumab FRAME study: a post hoc analysis of the role of regional background fracture risk on nonvertebral fracture outcome. *J Bone Miner Res* 2018;33:1407-16. <https://doi.org/10.1002/jbmr.3439>
 54. Peng J, Wang H, Liu Z, Xu ZL, Wang MX, Chen QM, et al. Real-world study of antiresorptive-related osteonecrosis of jaw based on the US Food and Drug Administration adverse event reporting system database. *Front Pharmacol* 2022;13:1017391. <https://doi.org/10.3389/fphar.2022.1017391>
 55. Bindakhil M, Shanti RM, Mupparapu M. Raloxifene-induced osteonecrosis of the jaw (MRONJ) with no exposure to bisphosphonates: clinical and radiographic findings. *Quintessence Int* 2021;52:258-63. <https://doi.org/10.3290/j.qi.b912675>
 56. Ko SY, Hwang TY, Baek K, Park C. Incidence and severity of medication-related osteonecrosis of the jaw in patients with osteoporosis using data from a Korean nationwide sample cohort in 2002 to 2019: a retrospective study. *J Yeungnam Med Sci* 2024;41:39-44. <https://doi.org/10.12701/jyms.2023.01116>
 57. Coleman R, Woodward E, Brown J, Cameron D, Bell R, Dodwell D, et al. Safety of zoledronic acid and incidence of osteonecrosis of the jaw during adjuvant therapy in a randomised phase III trial (AZURE: BIG 01-04) for women with stage II/III breast cancer. *Breast Cancer Res Treat* 2011;127:429-38. <https://doi.org/10.1007/s10549-011-1429-y>
 58. Coleman R, Cameron D, Dodwell D, Bell R, Wilson C, Rathbone E, et al. Adjuvant zoledronic acid in patients with early breast cancer: final efficacy analysis of the AZURE (BIG 01/04) randomised open-label phase 3 trial. *Lancet Oncol* 2014;15:997-1006. [https://doi.org/10.1016/s1470-2045\(14\)70302-x](https://doi.org/10.1016/s1470-2045(14)70302-x)
 59. Hoff AO, Toth BB, Altundag K, Johnson MM, Warneke CL, Hu M, et al. Frequency and risk factors associated with osteonecrosis of the jaw in cancer patients treated with intravenous bisphosphonates. *J Bone Miner Res* 2008;23:826-36. <https://doi.org/10.1359/jbmr.080205>
 60. Raje N, Terpos E, Willenbacher W, Shimizu K, García-Sanz R, Durie B, et al. Denosumab versus zoledronic acid in bone disease treatment of newly diagnosed multiple myeloma: an international, double-blind, double-dummy, randomized, controlled, phase 3 study. *Lancet Oncol* 2018;19:370-81. [https://doi.org/10.1016/s1470-2045\(18\)30072-x](https://doi.org/10.1016/s1470-2045(18)30072-x)
 61. Himelstein AL, Foster JC, Khatcheressian JL, Roberts JD, Seisler DK, Novotny PJ, et al. Effect of longer-interval vs standard dosing of zoledronic acid on skeletal events in patients with bone metastases: a randomized clinical trial. *JAMA* 2017;317:48-58. <https://doi.org/10.1001/jama.2016.19425>
 62. Barrett-Lee P, Casbard A, Abraham J, Hood K, Coleman R, Simmonds P, et al. Oral ibandronic acid versus intravenous zoledronic acid in treatment of bone metastases from breast cancer: a randomized, open-label, non-inferiority phase 3 trial. *Lancet Oncol* 2014;15:114-22. [https://doi.org/10.1016/s1470-2045\(13\)70539-4](https://doi.org/10.1016/s1470-2045(13)70539-4)
 63. Querrer R, Ferrare N, Melo N, Stefani CM, Dos Reis PED, Mesquita CRM, et al. Differences between bisphosphonate-related and denosumab-related osteonecrosis of the jaws: a systematic review. *Support Care Cancer* 2021;29:2811-20. <https://doi.org/10.1007/s00520-020-05855-6>
 64. Christodoulou C, Pervena A, Klouvas G, Galani E, Falagas ME, Tsakalos G, et al. Combination of bisphosphonates and antiangiogenic factors induces osteonecrosis of the jaw more frequently than bisphosphonates alone. *Oncology* 2009;76:209-11. <https://doi.org/10.1159/000201931>
 65. Ng TL, Tu MM, Ibrahim MFK, Basulaiman B, McGee SF, Srikanthan A, et al. Long-term impact of bone-modifying agents for the treatment of bone metastases: a systematic review. *Support Care Cancer* 2021;29:925-43. <https://doi.org/10.1007/s00520-020-05556-0>
 66. Amigues C, Fresse A, Roux CH, Gauthier S, Vieillard MH, Drici MD, et al. Zoledronate and osteonecrosis of the jaw in osteoporosis: incidence and risk factors. *Joint Bone Spine* 2023;90:105599. <https://doi.org/10.1016/j.jbspin.2023.105599>
 67. Hata H, Imamachi K, Ueda M, Matsuzaka M, Hiraga H, Osanai T, et al. Prognosis by cancer type and incidence of zoledronic acid-related osteonecrosis of the jaw: a single-center retrospective study. *Support Care Cancer* 2022;30:4505-14. <https://doi.org/10.1007/s00520-022-06839-4>
 68. Henry D, Vadhan-Raj S, Hirsh V, von Moos R, Hungria V, Costa L, et al. Delaying skeletal-related events in a randomized phase 3 study of denosumab versus zoledronic acid in patients with advanced cancer: an analysis of data from patients with solid tumors. *Support Care Cancer* 2014;22:679-87. <https://doi.org/10.1007/s00520-013-2022-1>
 69. Moon C, Kim H, Park JH, Park W, Kim HJ, Jung YS, et al. High-dose denosumab (Xgeva®) associated medication-related osteonecrosis of the jaws (MRONJ): incidence and clinical characteristics in a retrospective analysis of 1278 patients. *Support Care Cancer* 2024;32:774. <https://doi.org/10.1007/s00520-024-08974-6>
 70. Ikesue H, Mouri M, Tomita H, Hirabatake M, Ikemura M, Muroi N, et al. Associated characteristics and treatment outcomes of medication-related osteonecrosis of the jaw in patients receiving denosumab or zoledronic acid for bone metastases. *Support Care Cancer* 2021;29:4763-72. <https://doi.org/10.1007/s00520-021-06018-x>
 71. Ikesue H, Doi K, Morimoto M, Hirabatake M, Muroi N, Yamamoto S, et al. Risk evaluation of denosumab and zoledronic acid for medication-related osteonecrosis of the jaw in patients with bone metastases: a propensity score-matched analysis. *Support Care Cancer* 2022;30:2341-8. <https://doi.org/10.1007/s00520-021-06634-7>
 72. Loysen T, Van Cann T, Schöffski P, Clement PM, Bechter O, Spriet I, et al. Incidence of osteonecrosis of the jaw in patients with bone metastases treated sequentially with bisphosphonates and denosumab. *Acta Clin Belg* 2018;73:100-9. <https://doi.org/10.1080/17843286.2017.1348001>
 73. Srivastava A, Noguera Gonzalez GM, Geng Y, Won AM, Cabanillas ME, Naing A, et al. Prevalence of medication-related osteonecrosis of the jaw in patients treated with sequential antiresorptive drugs: systematic review and meta-analysis. *Support Care Cancer* 2021;29:2305-17. <https://doi.org/10.1007/s00520-020-05882-3>
 74. Mauri D, Valachis A, Polyzos IP, Polyzos NP, Kamposioras K, Pesce LL. Osteonecrosis of the jaw and use of bisphosphonates in adjuvant breast cancer treatment: a meta-analysis. *Breast Cancer Res Treat* 2009;116:433-9. <https://doi.org/10.1007/s10549-009-0432-z>
 75. Valachis A, Polyzos NP, Coleman RE, Gnant M, Eidtmann H, Brufsky AM, et al. Adjuvant therapy with zoledronic acid in patients with breast cancer: a systematic review and meta-analysis. *Oncologist* 2013;18:353-61. <https://doi.org/10.1634/theoncologist.2012-0261>
 76. Rathbone EJ, Brown JE, Marshall HC, Collinson M, Liversedge V, Murden GA, et al. Osteonecrosis of the jaw and oral health-related quality of life after adjuvant zoledronic acid: an AZURE trial sub-protocol (BIG01/04). *J Clin Oncol* 2013;31:2685-91. <https://doi.org/10.1200/jco.2012.46.4792>
 77. Vliek SB, Noordhoek I, Meershoek-Klein Kranenbarg E, van Rossum AGJ, Dezentje VO, Jager A, et al. Daily oral ibandronate with adjuvant endocrine therapy in postmenopausal women with estrogen receptor-positive breast cancer (BOOG 2006-04): randomized phase III TEAM-IIB trial. *J Clin Oncol* 2022;40:2934-45. <https://doi.org/10.1200/jco.21.00311>
 78. Palmerini E, Chawla NS, Ferrari S, Sudan M, Picci P, Marchesi E, et al. Denosumab in advanced/unresectable giant-cell tumour of bone: for how long? *Eur J Cancer* 2017;76:118-24. <https://doi.org/10.1016/j.ejca.2017.05.011>

- org/10.1016/j.ejca.2017.01.028
79. Raimondi A, Simeone N, Guzzo M, Maniezzo M, Collini P, Morosi C, et al. Rechallenge of denosumab in jaw osteonecrosis of patients with unresectable giant cell tumour of bone: a case series analysis and literature review. *ESMO Open* 2020;5:e000663. <https://doi.org/10.1136/esmoopen-2019-000663>
 80. Rutkowski P, Gaston L, Borkowska A, Stacchiotti S, Gelderblom H, Baldi GG, et al. Denosumab treatment of inoperable or locally advanced giant cell tumor of bone: multicenter analysis outside clinical trial. *Eur J Surg Oncol* 2018;44:1384-90. <https://doi.org/10.1016/j.ejso.2018.03.017>
 81. Jiang CY, Zhao L, Schuetz SM, Chugh R. Giant cell tumor of bone: effect of longer dosing intervals of denosumab on tumor control and bone-related complications. *Oncologist* 2022;27:595-9. <https://doi.org/10.1093/oncolo/oyac066>
 82. Duarte NT, Rech BO, Martins IG, Franco JB, Ortega KL. Can children be affected by bisphosphonate-related osteonecrosis of the jaw? A systematic review. *Int J Oral Maxillofac Surg* 2020;49:183-91. <https://doi.org/10.1016/j.ijom.2019.08.004>
 83. Henneidge AA, Jayasinghe J, Khajeh J, Macfarlane TV. Systematic review on the incidence of bisphosphonate-related osteonecrosis of the jaw in children diagnosed with osteogenesis imperfecta. *J Oral Maxillofac Res* 2013;4:e1. <https://doi.org/10.5037/jomr.2013.4401>
 84. Constantino CS, Krzak JJ, Fial AV, Kruger KM, Rammer JR, Radmanovic K, et al. Effect of bisphosphonates on function and mobility among children with osteogenesis imperfecta: a systematic review. *J Bone Miner Res Plus* 2019;3:e10216. <https://doi.org/10.1002/jbm4.10216>
 85. Ahdi HS, Wichelmann TA, Pandravada S, Ehrenpreis ED. Medication-induced osteonecrosis of the jaw: a review of cases from the Food and Drug Administration Adverse Event Reporting System (FAERS). *BMC Pharmacol Toxicol* 2023;24:15. <https://doi.org/10.1186/s40360-023-00657-y>
 86. Baron R, Ferrari S, Russell RG. Denosumab and bisphosphonates: different mechanisms of action and effects. *Bone* 2011;48:677-92. <https://doi.org/10.1016/j.bone.2010.11.020>
 87. Kim JW, Landayan ME, Lee JY, Tatad JC, Kim SJ, Kim MR, et al. Role of microcracks in the pathogenesis of bisphosphonate-related osteonecrosis of the jaw. *Clin Oral Invest* 2016;20:2251-8. <https://doi.org/10.1007/s00784-016-1718-2>
 88. He L, Sun X, Liu Z, Qiu Y, Niu Y. Pathogenesis and multidisciplinary management of medication-related osteonecrosis of the jaw. *Int J Oral Sci* 2020;12:30. <https://doi.org/10.1038/s41368-020-00093-2>
 89. Ristow O, Gerngroß C, Schwaiger M, Hohlweg-Majert B, Kehl V, Jansen H, et al. Is bone turnover of jawbone and its possible over-suppression by bisphosphonates of etiologic importance in pathogenesis of bisphosphonate-related osteonecrosis? *J Oral Maxillofac Surg* 2014;72:903-10. <https://doi.org/10.1016/j.joms.2013.11.005>
 90. Landesberg R, Woo V, Cremers S, Cozin M, Marolt D, Vunjak-Novakovic G, et al. Potential pathophysiological mechanisms in osteonecrosis of the jaw. *Ann N Y Acad Sci* 2011;1218:62-79. <https://doi.org/10.1111/j.1749-6632.2010.05835.x>
 91. Kim JW, Yee J, Oh SH, Kim SH, Kim SJ, Chung JE, et al. Machine learning approaches for predicting bisphosphonate-related osteonecrosis in women with osteoporosis using VEGFA gene polymorphisms. *J Pers Med* 2021;11:541. <https://doi.org/10.3390/jpm11060541>
 92. Choi SY, Kim JW, Oh SH, Cheon S, Yee J, Kim SJ, et al. Prediction of medication-related osteonecrosis of the jaws using machine learning methods from *estrogen receptor 1* polymorphisms and clinical information. *Front Med (Lausanne)* 2023;10:1140620. <https://doi.org/10.3389/fmed.2023.1140620>
 93. Gaudin E, Seidel L, Bacevic M, Rompen E, Lambert F. Occurrence and risk indicators of medication-related osteonecrosis of the jaw after dental extraction: a systematic review and meta-analysis. *J Clin Periodontol* 2015;42:922-32. <https://doi.org/10.1111/jcpe.12455>
 94. Soutome S, Otsuru M, Hayashida S, Murata M, Yanamoto S, Sawada S, et al. Relationship between tooth extraction and development of medication-related osteonecrosis of the jaw in cancer patients. *Sci Rep* 2021;11:17226. <https://doi.org/10.1038/s41598-021-96480-8>
 95. Saad F, Brown JE, Van Poznak C, Ibrahim T, Stemmer SM, Stopeck AT, et al. Incidence, risk factors, and outcomes of osteonecrosis of the jaw: integrated analysis from three blinded active-controlled phase III trials in cancer patients with bone metastases. *Ann Oncol* 2012;23:1341-7. <https://doi.org/10.1093/annonc/mdr435>
 96. Aljohani S, Gaudin R, Weiser J, Tröltzsch M, Ehrenfeld M, Kaeppler G, et al. Osteonecrosis of the jaw in patients treated with denosumab: a multicenter case series. *J Craniomaxillofac Surg* 2018;46:1515-25. <https://doi.org/10.1016/j.jcms.2018.05.046>
 97. Yarom N, Shapiro CL, Peterson DE, Van Poznak CH, Bohlke K, Ruggiero SL, et al. Medication-related osteonecrosis of the jaw: MASCC/ISOO/ASCO clinical practice guideline. *J Clin Oncol* 2019;37:2270-90. <https://doi.org/10.1200/jco.19.01186>
 98. Bedogni A, Mauceri R, Fusco V, Bertoldo F, Bettini G, Di Fede O, et al. Italian position paper (SIPMO-SICMF) on medication-related osteonecrosis of the jaw (MRONJ). *Oral Dis* 2024;30:3679-709. <https://doi.org/10.1111/odi.14887>
 99. Tani M, Hatano K, Yoshimura A, Horibe Y, Liu Y, Sassi N, et al. Cumulative incidence and risk factors for medication-related osteonecrosis of the jaw during long-term prostate cancer management. *Sci Rep* 2024;14:13451. <https://doi.org/10.1038/s41598-024-64440-7>
 100. Giovannacci I, Meleti M, Manfredi M, Mortellaro C, Greco Lucchina A, Bonanini M, et al. Medication-related osteonecrosis of the jaw around dental implants: implant surgery-triggered or implant presence-triggered osteonecrosis? *J Craniofac Surg* 2016;27:697-701. <https://doi.org/10.1097/scs.0000000000002564>
 101. Al-Nawas B, Lambert F, Andersen SWM, Bornstein MM, Gahlert M, Jokstad A, et al. Group 3 ITI consensus report: materials and antiresorptive drug-associated outcomes in implant dentistry. *Clin Oral Implants Res* 2023;34 Suppl 26:169-76. <https://doi.org/10.1111/clr.14135>
 102. Jung J, Ryu JI, Shim GJ, Kwon YD. Effect of agents affecting bone homeostasis on short- and long-term implant failure. *Clin Oral Implants Res* 2023;34 Suppl 26:143-68. <https://doi.org/10.1111/clr.14144>
 103. Escobedo MF, Cobo JL, Junquera S, Milla J, Olay S, Junquera LM. Medication-related osteonecrosis of the jaw. Implant presence-triggered osteonecrosis: case series and literature review. *J Stomatol Oral Maxillofac Surg* 2020;121:40-8. <https://doi.org/10.1016/j.jormas.2019.04.012>
 104. Lazarovici TS, Yahalom R, Taicher S, Schwartz-Arad D, Peleg O, Yarom N. Bisphosphonate-related osteonecrosis of the jaw associated with dental implants. *J Oral Maxillofac Surg* 2010;68:790-6. <https://doi.org/10.1016/j.joms.2009.09.017>
 105. Otto S, Aljohani S, Fliefel R, Ecke S, Ristow O, Burian E, et al. Infection as an important factor in medication-related osteonecrosis of the jaw (MRONJ). *Medicina (Kaunas)* 2021;57:463. <https://doi.org/10.3390/medicina57050463>
 106. Sher J, Kirkham-Ali K, Luo JD, Miller C, Sharma D. Dental implant placement in patients with a history of medications related to osteonecrosis of the jaws: a systematic review. *J Oral Implantol* 2021;47:249-68. <https://doi.org/10.1563/aaid-joi-d-19-00351>
 107. Campisi G, Mauceri R, Bertoldo F, Bettini G, Biasotto M, Colella G, et al. Medication-related osteonecrosis of jaws (MRONJ) prevention and diagnosis: Italian consensus update 2020. *Int J Environ Res Public Health* 2020;17:5998. <https://doi.org/10.3390/ijerph17165998>
 108. Dimopoulos MA, Kastritis E, Bamia C, Melakopoulos I, Gika D, Roussou M, et al. Reduction of osteonecrosis of the jaw (ONJ) after implementation of preventive measures in patients with multiple

- myeloma treated with zoledronic acid. *Ann Oncol* 2009;20:117-20. <https://doi.org/10.1093/annonc/mdn554>
109. Bonacina R, Mariani U, Villa F, Villa A. Preventive strategies and clinical implications for bisphosphonate-related osteonecrosis of the jaw: a review of 282 patients. *J Can Dent Assoc* 2011;77:b147.
 110. Karna H, Gonzalez J, Radia HS, Sedghizadeh PP, Enciso R. Risk-reductive dental strategies for medication related osteonecrosis of the jaw among cancer patients: a systematic review with meta-analyses. *Oral Oncol* 2018;85:15-23. <https://doi.org/10.1016/j.oraloncology.2018.08.003>
 111. Aboalela AA, Farook FF, Alqahtani AS, Almousa MA, Alanazi RT, Almohammadi DS. The effect of antiresorptive drug holidays on medication-related osteonecrosis of the jaw: a systematic review and meta-analysis. *Cureus* 2022;14:e30485. <https://doi.org/10.7759/cureus.30485>
 112. Takeda D, Kurita H, Kashima Y, Hasegawa T, Miyakoshi M, Yamada SI, et al. Is withdrawal of antiresorptive agents necessary before and after tooth extraction? A systematic review. *Clin Oral Investig* 2023;28:38. <https://doi.org/10.1007/s00784-023-05462-9>
 113. Wei LY, Cheng YW, Chiu WY, Kok SH, Chang HH, Cheng SJ, et al. Risk factors influencing medication-related osteonecrosis of the jaws (MRONJ) following dental extraction among osteoporotic patients in Taiwan. *Head Neck* 2025;47:1151-61. <https://doi.org/10.1002/hed.28011>
 114. Kim HY. Review and update of the risk factors and prevention of antiresorptive-related osteonecrosis of the jaw. *Endocrinol Metab* 2021;36:917-27. <https://doi.org/10.3803/enm.2021.1170>
 115. Reid IR. Zoledronate: efficacy and safety. *J Bone Miner Res* 2006;21 Suppl 2:P83-7. <https://doi.org/10.1359/jbmr.06s215>
 116. Park JH, Kong SH, Lee J, Oh J, Lee JR, Lee HJ, et al. Time since last intravenous bisphosphonate and risk of osteonecrosis of the jaw in osteoporotic patients. *Nat Commun* 2025;16:4367. <https://doi.org/10.1038/s41467-025-59718-x>
 117. Watts NB, Diab DL. Long-term use of bisphosphonates in osteoporosis. *J Clin Endocrinol Metab* 2010;95:1555-65. <https://doi.org/10.1210/jc.2009-1947>
 118. Leder BZ, Tsai JN, Uihlein AV, Wallace PM, Lee H, Neer RM, et al. Denosumab and teriparatide transitions in postmenopausal osteoporosis (the DATA-Switch study): extension of a randomised controlled trial. *Lancet* 2015;386:1147-55. [https://doi.org/10.1016/s0140-6736\(15\)61120-5](https://doi.org/10.1016/s0140-6736(15)61120-5)
 119. Cummings SR, Ferrari S, Eastell R, Gilchrist N, Jensen JB, McClung M, et al. Vertebral fractures after discontinuation of denosumab: a post hoc analysis of the randomized placebo-controlled FREEDOM trial and its extension. *J Bone Miner Res* 2018;33:190-8. <https://doi.org/10.1002/jbmr.3337>
 120. Tsourdi E, Langdahl B, Cohen-Solal M, Aubry-Rozier B, Eriksen EF, Gueñabens N, et al. Discontinuation of denosumab therapy for osteoporosis: a systematic review and position statement by ECTS. *Bone* 2017;105:11-7. <https://doi.org/10.1016/j.bone.2017.08.003>
 121. Srivastava A, Noguera Gonzalez GM, Geng Y, Won AM, Myers J, Li Y, et al. Medication-related osteonecrosis of the jaw in patients treated concurrently with antiresorptive and antiangiogenic agents: systematic review and meta-analysis. *J Immunother Precis Oncol* 2021;4:196-207. <https://doi.org/10.36401/jipo-21-14>
 122. Diana A, Carlino F, Giunta EF, Franzese E, Guerrero LP, Di Lauro V, et al. Cancer treatment-induced bone loss (CTIBL): state of the art and proper management in breast cancer patients on endocrine therapy. *Curr Treat Options Oncol* 2021;22:45. <https://doi.org/10.1007/s11864-021-00835-2>
 123. Carlson ER. Management of antiresorptive osteonecrosis of the jaws with primary surgical resection. *J Oral Maxillofac Surg* 2014;72:655-7. <https://doi.org/10.1016/j.joms.2013.12.007>
 124. Favia G, Tempesta A, Limongelli L, Crincoli V, Maiorano E. Medication-related osteonecrosis of the jaw: surgical or non-surgical treatment? *Oral Dis* 2018;24:238-42. <https://doi.org/10.1111/odi.12764>
 125. Hoefert S, Yuan A, Munz A, Grimm M, Elayouti A, Reinert S. Clinical course and therapeutic outcomes of operatively and non-operatively managed patients with denosumab-related osteonecrosis of the jaw (DRONJ). *J Craniomaxillofac Surg* 2017;45:570-8. <https://doi.org/10.1016/j.jcms.2017.01.013>
 126. Hamid A, Thomas S, Bell C, Gormley M. Case series of medication-related osteonecrosis of the jaw (MRONJ) patients prescribed a drug holiday. *Br J Oral Maxillofac Surg* 2023;61:227-32. <https://doi.org/10.1016/j.bjoms.2023.02.003>
 127. Natsu M, Meuric V, Roginski P, Gamby R, Lejeune S. Medication-related osteonecrosis of the jaw: evaluation of a therapeutic strategy in oral surgery. *J Stomatol Oral Maxillofac Surg* 2024;101877. <https://doi.org/10.1016/j.jormas.2024.101877>
 128. Ristow O, Rückschloß T, Müller M, Berger M, Kargus S, Pautke C, et al. Is the conservative non-surgical management of medication-related osteonecrosis of the jaw an appropriate treatment option for early stages? A long-term single-center cohort study. *J Craniomaxillofac Surg* 2019;47:491-99. <https://doi.org/10.1016/j.jcms.2018.12.014>
 129. Kim HY, Lee SJ, Kim SM, Myoung H, Hwang SJ, Choi JY, et al. Extensive surgical procedures result in better treatment outcomes for bisphosphonate-related osteonecrosis of the jaw in patients with osteoporosis. *J Oral Maxillofac Surg* 2017;75:1404-13. <https://doi.org/10.1016/j.joms.2016.12.014>
 130. Sim IW, Borromeo GL, Tsao C, Hardiman R, Hofman MS, Papatziomos Hjelle C, et al. Teriparatide promotes bone healing in medication-related osteonecrosis of the jaw: a placebo-controlled, randomized trial. *J Clin Oncol* 2020;38:2971-80. <https://doi.org/10.1200/jco.19.02192>
 131. Choi SY, Yoon D, Kim KM, Kim SJ, Kim HY, Kim JW, et al. Adjunctive recombinant human parathyroid hormone agents for the treatment of medication-related osteonecrosis of the jaw: a report of three cases. *J Korean Assoc Oral Maxillofac Surg* 2024;50:103-9. <https://doi.org/10.5125/jkaoms.2024.50.2.103>
 132. Morishita K, Yamada SI, Kawakita A, Hashidume M, Tachibana A, Takeuchi N, et al. Treatment outcomes of adjunctive teriparatide therapy for medication-related osteonecrosis of the jaw (MRONJ): a multicenter retrospective analysis in Japan. *J Orthop Sci* 2020;25:1079-83. <https://doi.org/10.1016/j.jos.2020.01.012>
 133. Kim JY, Park JH, Jung HD, Jung YS. Treatment of medication-related osteonecrosis of the jaw around the dental implant with a once-weekly teriparatide: a case report and literature review. *J Oral Implantol* 2019;45:403-7. <https://doi.org/10.1563/aaid-joid-19-00040>
 134. Kim KM, Park W, Oh SY, Kim HJ, Nam W, Lim SK, et al. Distinctive role of 6-month teriparatide treatment on intractable bisphosphonate-related osteonecrosis of the jaw. *Osteoporos Int* 2014;25:1625-32. <https://doi.org/10.1007/s00198-014-2622-8>
 135. Jung J, Yoo HY, Kim GT, Lee JW, Lee YA, Kim DY, et al. Short-term teriparatide and recombinant human bone morphogenetic protein-2 for regenerative approach to medication-related osteonecrosis of the jaw: a preliminary study. *J Bone Miner Res* 2017;32:2445-52. <https://doi.org/10.1002/jbmr.3237>
 136. Ohbayashi Y, Iwasaki A, Nakai F, Mashiba T, Miyake M. A comparative effectiveness pilot study of teriparatide for medication-related osteonecrosis of the jaw: daily versus weekly administration. *Osteoporos Int* 2020;31:577-85. <https://doi.org/10.1007/s00198-019-05199-w>
 137. Rubin MR, Bilezikian JP. The anabolic effects of parathyroid hormone therapy. *Clin Geriatr Med* 2003;19:415-32. [https://doi.org/10.1016/s0749-0690\(02\)00074-5](https://doi.org/10.1016/s0749-0690(02)00074-5)
 138. Neer RM, Arnaud CD, Zanchetta JR, Prince R, Gaich GA, Reginster JY, et al. Effect of parathyroid hormone (1-34) on fractures and bone mineral density in postmenopausal women with osteoporosis. *N Engl J Med* 2001;344:1434-42. <https://doi.org/10.1056/nejm200105103441904>
 139. Yoshiga D, Yoshioka I, Habu M, Sasaguri M, Tominaga K. Effec-

- tive ancillary role and long-term course of daily or weekly teriparatide treatment on refractory medication-related osteonecrosis of the jaw: a clinical case series. *Br J Oral Maxillofac Surg* 2022;60:604-9. <https://doi.org/10.1016/j.bjoms.2021.10.004>
140. Kim KM, Kim S, Hwang H, Kim HY, Kim D, Park JH, et al. Effects of daily versus weekly teriparatide for medication-related osteonecrosis of the jaw: a case-control study. *Oral Dis* 2024;30:3286-95. <https://doi.org/10.1111/odi.14801>
 141. Park JH, Kim JW, Kim SJ. Does the addition of bone morphogenetic protein 2 to platelet-rich fibrin improve healing after treatment for medication-related osteonecrosis of the jaw? *J Oral Maxillofac Surg* 2017;75:1176-84. <https://doi.org/10.1016/j.joms.2016.12.005>
 142. Kim JW, Kim SJ, Kim MR. Simultaneous application of bone morphogenetic protein-2 and platelet-rich fibrin for the treatment of bisphosphonate-related osteonecrosis of jaw. *J Oral Implantol* 2016;42:205-8. <https://doi.org/10.1563/aaid-joi-d-14-00309>
 143. Moraes-da-Silva AF, Maluf G, Rubira-Bullen IRF, Santos PSDS. Bone morphogenetic protein 2 plus leukocyte and platelet-rich fibrin for the treatment of MRONJ. *J Craniofac Surg* 2023;34:e338-41. <https://doi.org/10.1097/scs.00000000000009059>
 144. Freiberger JJ, Padilla-Burgos R, McGraw T, Suliman HB, Kraft KH, Stolp BW, et al. What is the role of hyperbaric oxygen in the management of bisphosphonate-related osteonecrosis of the jaw: a randomized controlled trial of hyperbaric oxygen as an adjunct to surgery and antibiotics. *J Oral Maxillofac Surg* 2012;70:1573-83. <https://doi.org/10.1016/j.joms.2012.04.001>
 145. Li FL, Wu CB, Sun HJ, Zhou Q. Effectiveness of laser-assisted treatments for medication-related osteonecrosis of the jaw: a systematic review. *Br J Oral Maxillofac Surg* 2020;58:256-67. <https://doi.org/10.1016/j.bjoms.2019.12.001>
 146. Scoletta M, Arduino PG, Reggio L, Dalmaso P, Mozzati M. Effect of low-level laser irradiation on bisphosphonate-induced osteonecrosis of the jaws: preliminary results of a prospective study. *Photomed Laser Surg* 2010;28:179-84. <https://doi.org/10.1089/pho.2009.2501>
 147. Fortunato L, Bennardo F, Buffone C, Giudice A. Is the application of platelet concentrates effective in the prevention and treatment of medication-related osteonecrosis of the jaw? A systematic review. *J Craniomaxillofac Surg* 2020;48:268-85. <https://doi.org/10.1016/j.jcms.2020.01.014>
 148. Kim JW, Kim SJ, Kim MR. Leucocyte-rich and platelet-rich fibrin for the treatment of bisphosphonate-related osteonecrosis of the jaw: a prospective feasibility study. *Br J Oral Maxillofac Surg* 2014;52:854-9. <https://doi.org/10.1016/j.bjoms.2014.07.256>
 149. Del Fabbro M, Gallesio G, Mozzati M. Autologous platelet concentrates for bisphosphonate-related osteonecrosis of the jaw treatment and prevention: a systematic review of the literature. *Eur J Cancer* 2015;51:62-74. <https://doi.org/10.1016/j.ejca.2014.10.015>
 150. Hellstein JW, Adler RA, Edwards B, Jacobsen PL, Kalmar JR, Koka S, et al. Managing the care of patients receiving antiresorptive therapy for prevention and treatment of osteoporosis: executive summary of recommendations from the American Dental Association Council on Scientific Affairs. *J Am Dent Assoc* 2011;142:1243-51. <https://doi.org/10.14219/jada.archive.2011.0108>
 151. Hayashida S, Yanamoto S, Fujita S, Hasegawa T, Komori T, Kojima Y, et al. Drug holiday clinical relevance verification for antiresorptive agents in medication-related osteonecrosis cases of the jaw. *J Bone Miner Metab* 2020;38:126-34. <https://doi.org/10.1007/s00774-019-01035-7>
 152. Hinson AM, Siegel ER, Stack BC Jr. Temporal correlation between bisphosphonate termination and symptom resolution in osteonecrosis of the jaw: a pooled case report analysis. *J Oral Maxillofac Surg* 2015;73:53-62. <https://doi.org/10.1016/j.joms.2014.07.012>
 153. Kim YH, Lee HK, Song SI, Lee JK. Drug holiday as a prognostic factor of medication-related osteonecrosis of the jaw. *J Korean Assoc Oral Maxillofac Surg* 2014;40:206-10. <https://doi.org/10.5125/jkaoms.2014.40.5.206>
 154. Ramaglia L, Guida A, Iorio-Siciliano V, Cuzzo A, Blasi A, Sculean A. Stage-specific therapeutic strategies of medication-related osteonecrosis of the jaws: a systematic review and meta-analysis of the drug suspension protocol. *Clin Oral Investig* 2018;22:597-615. <https://doi.org/10.1007/s00784-017-2325-6>
 155. Otsuru M, Soutome S, Omori K, Suyama K, Morishita K, Hayashida S, et al. Relationship between drug holidays of antiresorptive agents and surgical outcomes in cancer patients with medication-related osteonecrosis of the jaw. *Int J Environ Res Public Health* 2022;19:4624. <https://doi.org/10.3390/ijerph19084624>
 156. Hadaya D, Soundia A, Gkouveris I, Bezouglaia O, Dry SM, Pirihi FQ, et al. Antiresorptive-type and discontinuation-timing affect ONJ burden. *J Dent Res* 2021;100:746-53. <https://doi.org/10.1177/0022034520986804>
 157. Malan J, Ettinger K, Naumann E, Beirne OR. The relationship of denosumab pharmacology and osteonecrosis of the jaws. *Oral Surg Oral Med Oral Pathol Oral Radiol* 2012;114:671-6. <https://doi.org/10.1016/j.oooo.2012.08.439>
 158. Coleman R, Hadji P, Body JJ, Santini D, Chow E, Terpos E, et al. Bone health in cancer: ESMO clinical practice guidelines. *Ann Oncol* 2020;31:1650-63. <https://doi.org/10.1016/j.annonc.2020.07.019>
 159. Wong CH, Tsoi KH, Pu JJ, Jiang NS, Chan SSS, Loong CHN, et al. Osteoporosis management after the occurrence of medication-related osteonecrosis of the jaw: a 13-year experience at a tertiary center. *Endocrinol Metab (Seoul)* 2025. <https://doi.org/10.3803/enm.2024.2262> [Epub ahead of print]
 160. Zirk M, Kreppel M, Buller J, Pristup J, Peters F, Dreiseidler T, et al. The impact of surgical intervention and antibiotics on MRONJ stage II and III - retrospective study. *J Craniomaxillofac Surg* 2017;45:1183-9. <https://doi.org/10.1016/j.jcms.2017.05.027>
 161. Jung S, Kim J, Park JH, Kim KY, Kim HJ, Park W. A 5-year retrospective cohort study of denosumab-induced medication-related osteonecrosis of the jaw in osteoporosis patients. *Sci Rep* 2022;12:8641. <https://doi.org/10.1038/s41598-022-11615-9>
 162. El-Rabbany M, Blanas N, Sutherland S, Lam DK, Shah PS, Azarpazhooh A. Surgical therapy in patients with medication-related osteonecrosis of the jaw is associated with disease resolution and improved quality of life: a prospective cohort study. *J Oral Maxillofac Surg* 2022;80:1084-93. <https://doi.org/10.1016/j.joms.2022.01.012>
 163. Chen S, Ren H, He Y, An J, Zhang Y. Recurrence-related factors of medication-related osteonecrosis of the jaw: a five-year experience. *J Oral Maxillofac Surg* 2021;79:2472-81. <https://doi.org/10.1016/j.joms.2021.07.029>
 164. Park KS, Jung SM, Park YJ, Kim KJ. Denosumab-related osteonecrosis of the jaw may not be a subject of teriparatide treatment. *J Bone Miner Res* 2022;37:2044-5. <https://doi.org/10.1002/jbmr.4625>
 165. van de Laarschot DM, McKenna MJ, Abrahamsen B, Langdahl B, Cohen-Solal M, Guañabens N, et al. Medical management of patients after atypical femur fractures: a systematic review and recommendations from the European Calcified Tissue Society. *J Clin Endocrinol Metab* 2020;105:1682-99. <https://doi.org/10.1210/clinem/dgz295>
 166. Ramchand SK, Tsai JN, Lee H, Sassana-Khadka G, Jordan M, Ryan S, et al. The comparison of alendronate and raloxifene after denosumab (CARD) study: a comparative efficacy trial. *Osteoporos Int* 2024;35:255-63. <https://doi.org/10.1007/s00198-023-06932-2>

How to cite this article: Kim JW, Kong SH, Kim JY, Kwak MK, Kim JY, Oh JH, et al. Medication-related osteonecrosis of the jaw: an evidence-based 2025 position statement from a Korean multidisciplinary task force. *J Korean Assoc Oral Maxillofac Surg* 2025;51:333-353. <https://doi.org/10.5125/jkaoms.2025.51.6.333>