

1

치성 낭종 및 종양의 치료를 위한 조대술의 사용 : 증례 보고(3례) 및 문헌 고찰

¹⁾가톨릭대학교 서울성모병원 구강악안면외과, ²⁾가톨릭대학교 부천성모병원 구강악안면외과
³⁾가톨릭대학교 성바오로병원 구강악안면외과

이재일¹⁾, 윤현중²⁾, 이상화³⁾

ABSTRACT

Marsupialization for management of odontogenic cysts and tumors : Report of three cases with literature review

¹⁾Department of Oral and Maxillofacial Surgery, Seoul St. Mary's Hospital, The Catholic University

²⁾Department of Oral and Maxillofacial Surgery, Bucheon St. Mary's Hospital, The Catholic University

³⁾Department of Oral and Maxillofacial Surgery, St. Paul's Hospital, The Catholic University

Jae-Il Lee¹⁾, Hyun-Joong Yoon²⁾, Sang-Hwa Lee³⁾

Cyst is a closed sac, having a distinct membrane and division compared to the nearby tissue. Most cysts in the oro-maxillofacial area are odontogenic origin and found most commonly by oral and maxillofacial surgeons.

Enucleation is considered as a definitive therapy in the management of these cysts. However, to select the treatment method for large cyst, consideration of position of the cyst, size and accessibility to main structure are needed. Marsupialization is a minimal invasive technique to treat large odontogenic cyst and tumor without damage to adjacent important structures.

This study was undertaken to describe three cases of odontogenic cysts and tumors of jaws that were successfully treated with enucleation after marsupialization.

Key words : Marsupialization, Enucleation, Odontogenic cyst, Odontogenic tumor

Corresponding Author

Hyun-Joong Yoon, DDS, PhD.

Department of Oral and Maxillofacial Surgery, Bucheon St. Mary's Hospital, College of Medicine, The Catholic University of Korea, Sosa-ro 327, Wonmi-gu, Bucheon-si, Gyeonggi-do 420-717, Republic of Korea.

Tel : +82-10-6667-1828, Fax : +82-2-769-1689, E-mail : omfshj@catholic.ac.kr

I. Introduction

Cyst is the pathologic tissue containing liquid or semi-solid material and the cavity that surrounded by connective tissue lining with inner epithelium membrane in the soft or hard tissue. Most cysts in the jaws are odontogenic origin and found most commonly by oral and maxillofacial surgeons¹⁾. Dentigerous cyst, radicular cyst and keratocystic odontogenic tumor are the representative odontogenic cysts and tumors.

Dentigerous cyst is the most common of all developmental odontogenic cysts. This cyst is always associated with an unerupted tooth or a developing tooth bud and found most frequently around the crown of the mandibular 3rd molars followed, in order of frequency, by the maxillary canines, maxillary 3rd molars and, rarely, the maxillary central incisors²⁾. The cyst may cause swelling, tooth displacement, tooth mobility and sensitivity if it reaches a size larger than 2 cm in diameter³⁾. In the radiograph, it usually shows well-defined unilocular radiolucency, often with a sclerotic border, surrounding the crown of an unerupted tooth. Histologically, it consists of a fibrous wall lined by non-keratinized stratified squamous epithelium of myxoid tissue, odontogenic remnants and rarely sebaceous cells.

Radicular cyst is the most common inflammatory odontogenic cyst of tooth bearing areas of the jaws. It is most commonly found at the apices of the involved teeth with infected or necrotic pulps; however, it may also be found at the lateral aspects of the roots related by accessory root canals⁴⁾. Clinically, the lesion is

usually small and asymptomatic, but may sometimes express mild pain and sensitivity to percussion. The affected tooth is usually non-vital and the surrounding mucosa may exhibit bluish discoloration. Histopathologically, it is lined either partially or completely by non-keratinized stratified squamous epithelium.

Keratocystic odontogenic tumor(KCOT) is a benign but locally aggressive developmental cystic neoplasm. KCOT occurs in the jaws, especially the posterior portion of the body and ascending ramus of the mandible, approximately twice as much as the maxilla. It has an incidence rate of 2% to 14% with 2 peaks around the ages of 30 and 60 years old and seems to be more frequent in males than females, with a ratio of 2:1^{5, 6)}. Clinically, it is expressed by manifestations such as swelling, pain or both in most patients but there are also cases with no symptoms. The histologic features are characterized by the presence of a thin bandlike parakeratinized or orthokeratinized stratified squamous epithelium^{7, 8)}. A systemic review reported that the marsupialization for KCOT treatment resulted in 40% of tumor recurrence after 5 years of follow-up⁹⁾.

Removal of the associated tooth and enucleation of the lesion are considered as a definitive therapy in the management of these cysts and tumors. However, large cyst may require marsupialization to provide less extensive and safer surgical procedure at later date¹⁰⁾. Marsupialization was first described by Partsch^{11, 12)} for the treatment of cystic lesions. This technique is based on the externalization of

the cyst through the creation of a surgical window in the mucosa and the cystic wall. Their borders are then sutured to create the open cavity to communicate with the oral cavity. This procedure relieves pressure from the cystic fluid, allowing shrinkage of the cystic space and facilitating bone apposition to the cystic walls. When the radiological image showed a decreased size compared to the original lesion without involving important anatomical structures enucleation with peripheral ostectomy was performed¹³⁾. So this technique is conservative and useful treatment method to patients.

This study was undertaken to describe three cases of odontogenic cysts and tumors of jaws that were successfully treated with enucleation without damage to adjacent anatomical structures after decreasing the size of lesion by marsupialization.

II. Cases Report

All three patients were referred to our department from the local clinic. Clinical data of the three patients are summarized at Table 1. All patients underwent panoramic radiograph(PR), computerized tomography(CT) and histological examinations.

Case 1

At PR and CT, 3.9 * 2.1 * 4.3 cm size radiolucent lesion was observed from the distal area of second molar to the ramus in the right mandible horizontally, from alveolar crest to upper 6mm of mandible lower border vertically, bucco-lingual cortical bone expansion and antero-posterior resorption. Right inferior alveolar nerve was subsided into the lesion so the border was not clear. Displacement of right mandibular third

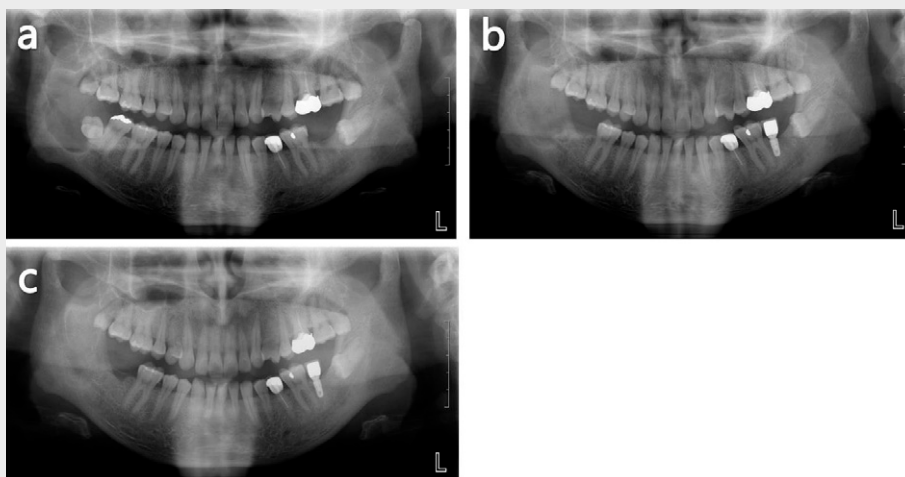


Fig. 1. Panoramic X-rays of case 1.

- Pre-operative PR. Huge cystic lesion was observed in the right body and ramus of mandible.
- At 5 months follow up after marsupialization. The cavity size of cystic lesion was decreased.
- At 16 months follow up after masupialization, enucleation was performed. Almost ossification was observed.

CASE REPORT

molar which was transverse impacted state was observed(Fig. 1a and Fig. 2a, b). Tentative diagnosis was dentigerous cyst of mandible. Due to possibility of nerve injury and risk of pathological fracture by relative large size, right mandibular second and third molars were extracted and marsupialization was performed.

An incisional biopsy was performed under general anesthesia at the same time of marsupialization and the specimen was sent for histo-pathological examination. This case was definitely diagnosed same as tentative diagnosis. Case 1 was dentigerous cyst(Fig. 3).

At 16 months after marsupialization, cyst

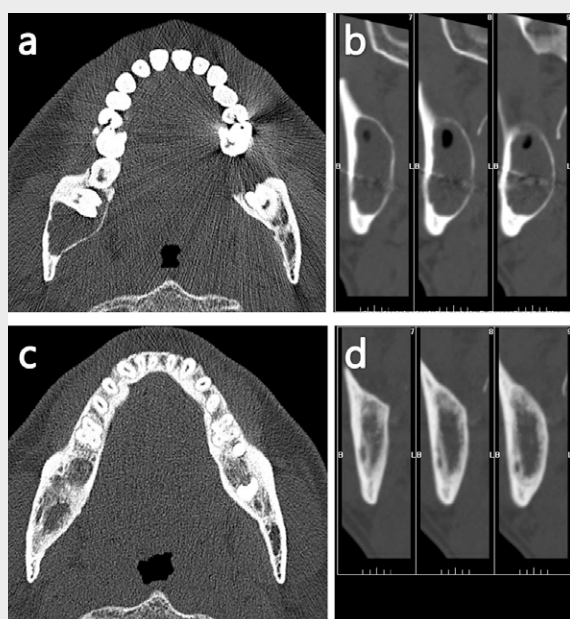


Fig. 2. Computed tomography of case 1.

a, b : Pre-operative CT. Huge radiolucent cystic lesion was observed in the right body and ramus of mandible.
c, d : At 16 months follow up after marsupialization, New bone formation was observed in the right mandibular body and ramus.

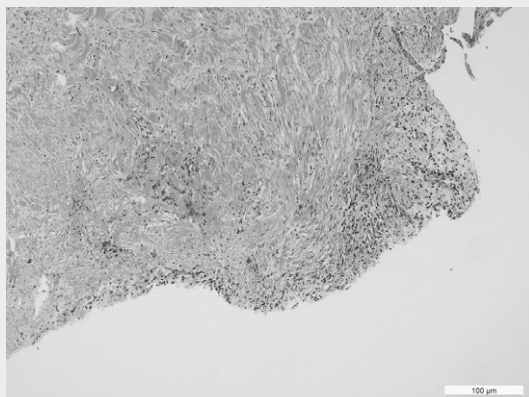


Fig. 3. Histopathologic features of a dentigerous cyst showing fibrous wall lined by non-keratinized stratified squamous epithelium (hematoxylin and eosin stain, original magnification x10)

enucleation and flagyl gauze insertion under general anesthesia were performed(Fig. 1b, c and Fig. 2c, d). There were no symptoms and signs of recurrence at 25 months of follow-up.

Case 2

PR and CT showed a well-defined pear shaped unilocular interradicular radiolucent lesion bordered by a thin rim of cortical bone between the root of left mandibular canine, first premolar and primary first molar. The size was 1.8 * 1.5 * 1.9 cm. This lesion displaced the adjacent teeth and root resorption of left mandibular primary first molar was observed(Fig. 4a and Fig. 5a, b). Tentative diagnosis was radicular cyst (periapical lateral periodontal cyst) of mandible. For

assistance in unerupted permanent teeth, left mandibular primary first and second molars were extracted and marsupialization was performed. An incisional biopsy was performed under general anesthesia at the same time of marsupialization and the specimen was sent for histo-pathological examination. This case was definitely diagnosed same as tentative diagnosis. Case 2 was radicular cyst(Fig. 6).

After 6 months, orthodontic treatment was started. A further follow-up by CT and PR of 27 months after marsupialization revealed a good osseous consolidation in the area of the mandible and no evidence of recurrence(Fig. 4b-d and Fig. 5c, d). There were no paresthesia of lower lip, gingiva and teeth of mandible. And the adjacent permanent teeth were preserved well.

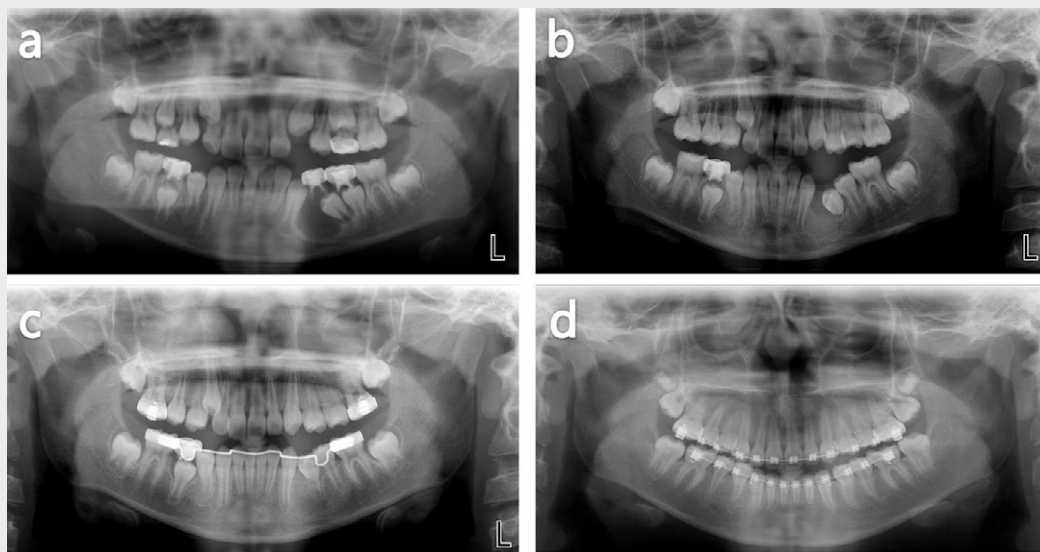


Fig. 4. Panoramic X-rays of case 2.
 a. Pre-operative PR. Cystic lesion was observed in the left body of mandible.
 b. At 4 months follow up after marsupialization. The cavity size of cystic lesion was decreased.
 c. At 9 months follow up after marsupialization. Almost ossification was observed.
 d. At 27 months follow up after marsupialization. Complete ossification was observed.

Case 3

PR and CT revealed the radiolucent lesion with the size of 2.3 * 1.6 * 2.1 cm located between the left impacted mandibular third molar and mandibular lower border. Partial perforation of

lingual cortical bone was observed and the left inferior alveolar nerve was subsided in the lesion. Root resorption of adjacent tooth was not found(Fig. 7a and Fig. 8a, b). Tentative diagnosis was odontogenic keratocyst. Due to possibility of nerve injury and risk of pathological fracture, left

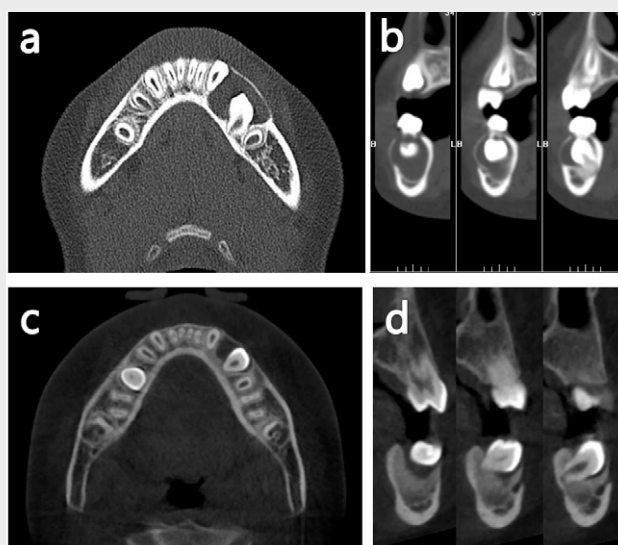


Fig. 5. Computed tomography of case 2.
 a, b : Pre-operative CT. Radiolucent cystic lesion was observed in the left body of mandible.
 c, d : At 4 months follow up after marsupialization, CT showed bone formation was observed in the left body of mandible.

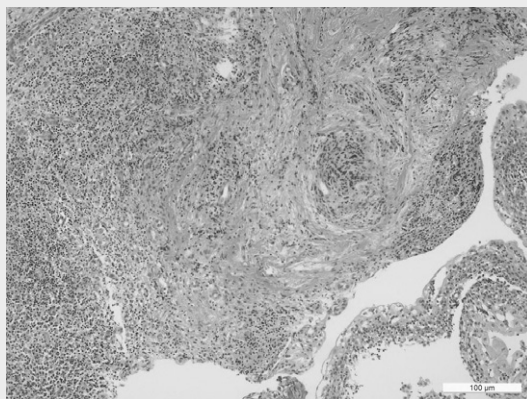


Fig. 6. Histopathologic features of a radicular cyst showing the cystic cavity which was lined by non-keratinized stratified squamous epithelium with mixed inflammatory infiltration (hematoxylin and eosin stain, original magnification x10)

CASE REPORT

mandibular third molar was extracted and rubber tube was applied. An incisional biopsy was performed under general anesthesia at the same time of marsupialization on each patient and the specimen was sent for histo-pathological examination. In this case, histo-pathological examination showed keratocystic odontogenic tumor with high possibility, but could not be definitely diagnosed with this specimen when

marsupialization. After 10 months follow-up for marsupialization(Fig. 7b and Fig. 8c, d), enucleation was performed under general anesthesia. It was definitely diagnosed as keratocystic odontogenic tumor when enucleation procedure (Fig. 9). After operation, no evidence of recurrence was found at 24 months after cyst enucleation.

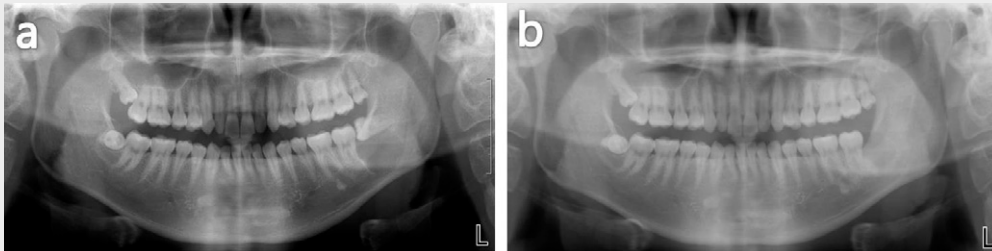


Fig. 7. Panoramic X-rays of case 3.

- a. Pre-operative PR. Huge cystic lesion was observed in the left angle of mandible.
- b. At 12 months follow up after marsupialization. The cavity size of cystic lesion was decreased and ossification was observed.

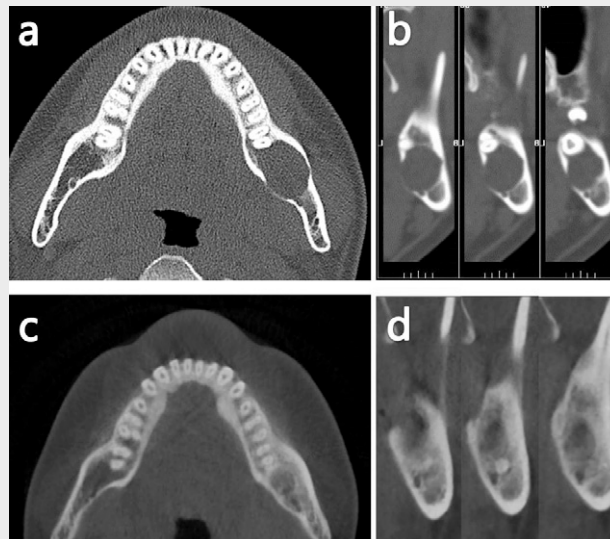


Fig. 8. Computed tomography of case 3.

- a, b : Pre-operative CT. Huge radiolucent cystic lesion and perforation of lingual cortex were observed in the left angle of mandible.
- c, d : At 10 months follow up after marsupialization. CT revealed new bone formation was observed on the left body of mandible.

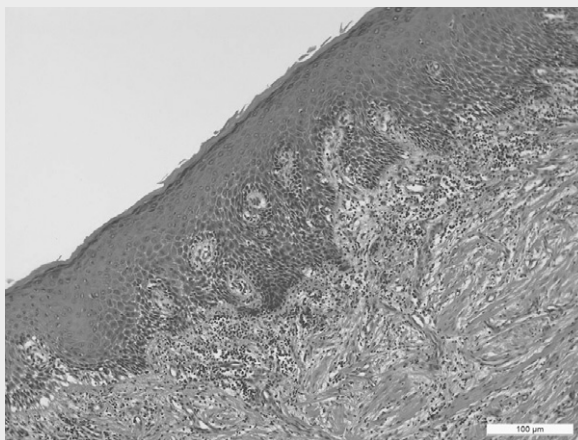


Fig. 9. Histopathologic features of an keratocystic odontogenic tumor showing a characteristic epithelial lining which is 6 to 8 cells thick with a hyperchromatic and palisaded basal cell layer and a corrugated parakeratotic surface (hematoxylin and eosin stain, original magnification x10)

	Case 1	Case 2	Case 3
Age / Sex	44 years/male	9 years/female	22 years/male
PMH	Hypertension	No	Leukemia
Symptoms	No paresthesia of lower lip No pain and swelling	No paresthesia of lower lip No pain and swelling	No paresthesia of lower lip Pain and slight swelling
Location	Right mandibular third molar area	Left mandibular under #74, #75 area	Left impacted mandibular third molar
Original Size	3.9 * 2.1 * 4.3 cm	1.8 * 1.5 * 1.9 cm	2.3 * 1.6 * 2.1 cm
Size when cyst enucleation	2.4 * 1.5 * 2.6 cm (decreased as 74%)	No enucleation. 1.1 * 0.9 * 0.9 cm when finishing (decreased as 78%)	1.6 * 1.0 * 1.5 cm (decreased as 69%)
Tentative Diagnosis	Dentigerous cyst	Radicular cyst	Keratocystic odontogenic tumor
Definitive Diagnosis	Dentigerous cyst	Radicular cyst	Keratocystic odontogenic tumor
Marsupialization period	16 months	6 months	10 months
F/U period	25 months	34 months	34 months

Table 1. Summary of clinical information for three cases

III. Discussion

The term, 'cyst' is derived from the Greek word, 'Kystis', meaning, 'sac or bladder'. Cyst is defined as a pathological cavity that is usually

lined by epithelium and which has a centrifugal, expansive mode of growth¹⁴⁾.

Treatments of cyst at jaw are extraction or endodontic treatment of cause teeth and at the same time enucleation of cyst is the most

common and also marsupialization, decompression or surgical enucleation area are also used. Cysts are usually enucleated, where the cystic lining is separated from its inner bony surface and removed and the cavity is allowed to fill with blood clot. And the cyst may be marsupialized to relieve the internal pressure¹⁵⁾. To select the treatment method, consideration of position of the cyst, cause teeth, size and accessibility to main structure, degree of transition of cause or adjacent teeth, age of patient, and patient cooperation are needed.

As one of them, marsupialization has some absolute indications; (1) tissue injury depending on the proximity of cyst to vital structures, possibility of injury to nerve, (2) difficult surgical access, (3) assistance in eruption of teeth if an unerupted teeth is involved in the cyst and is needed in the mouth, (4) extent of surgery in an unhealthy or feeble individual, (5) very large cyst or risk of pathological fracture of bone. In the present cases, marsupializations were used due to possibility of nerve injury and risk of pathological fracture by relative large size in case 1, assistance in unerupted permanent teeth in case 2, and possibility of nerve injury and risk of pathological fracture in case 3. Gao et al.¹⁶⁾ recommended marsupialization for all patients with large cysts. Furthermore, the speed of shrinkage of larger cystic lesions might be faster than that of smaller lesion after marsupialization; this is consistent with the results of Zhao et al¹⁷⁾, Shudou et al¹⁸⁾, and Kubota et al¹⁹⁾.

According to indications, marsupialization needs no difficult surgical technique and is a

minimal invasive method. It is possible to treat without damage to adjacent important structures and not need additional bone graft. Also, it does not make oronasal or oroantral fistula, especially in case of cyst occur to pediatric, there is advantage that prevents missing of permanent teeth. However, the patient must be cooperative and irrigate the cyst at least twice a day. It needs long healing period so the patient feels discomfort due to long term marsupialization stent installation in the oral cavity. And, it also causes inflammation because of food impaction into the drain or not clean state of drain near the oral tissue. By low frequency, odontogenic epithelium of the cyst changed into ameloblastoma^{20,21)}.

de Molon et al.²²⁾ showed that the first and second mandibular molar was preserved, and the patient did not show any signs of paresthesia related to injury in the mandibular alveolar nerve in their KCOT case. The patient did not show any sign of necrotic pulp in his first mandibular molar even with a small resorption in the root apex, not being necessary additional procedures. In the present cases, cysts and tumors of jaw are treated by marsupialization and enucleation without damage to adjacent structure. Fast bone regeneration at the defect area without infection or recurrence and normal healing of bone expansion area were observed. Successful marsupialization made possible to prevent unnecessary missing of permanent tooth included at cyst and well active eruption. There were no recurrence at 9 months in case 1 and 24 months in case 3 after cyst enucleation, and 28 months in

case 2 after drain removal for marsupialization.

Marker et al.²³⁾ recommended the decompression as possible as long time for successful marsupialization and at least 1 year is needed for decompression, and waiting till the drain fall out due to healing in the cavity. In the present cases, periods of marsupialization were 16 months in case 1, 6 months in case 2, and 10 months in case 3.

Also, Marker et al.²³⁾ recommended marsupialization procedure is regarded as successful when the size of cavity decreased as 50% or 60% in the radiograph. Sanchez-Siles et al.²⁴⁾ showed a clinical case of KCOT treatment using the marsupialization technique prior to enucleation. This approach allowed the lesion reduction of 50 mm x 25 mm to 13 mm x 13 mm in diameter (radiographic aspect), facilitating the complete removal of the lesion with less-invasive approach and without recurrence within the 1-year of follow-up. In the present cases, cyst enucleation was performed when sizes of cavity decreased as 74% in case 1, 78% in case 2, and 69% in case 3. However, the time of operation is better to decide by confidence that there was no damage to

important structures, systemic condition or age of patients, and remaining bone regeneration potential rather than decreased size of cavity. Gao et al.¹⁶⁾ showed that relative shrinking size was affected by the duration of marsupialization and the primary radiolucent area, but not by patient age when marsupialization using customized thermoplastic resin stents decreased the size of radicular cyst and KCOT.

During marsupialization, patients have to wear appliance for long time. Therefore, it must be easy to keep clean, minimize the discomfort and not to be a factor of infection itself. In the present cases, rubber tube with acrylic resin plate was used(Fig. 10). All the patients were instructed to irrigate the inside of the cavity through the appliance with normal saline. Regular follow-up visits are necessary to see that the cavity is filling up in a uniform fashion and to adjust the size of the acrylic plug²⁵⁾.

In conclusion, marsupialization had a high success rate as minimal invasive method to treat odontogenic cysts and tumors in the present cases.




Fig. 10. Rubber tube with acrylic resin plate was used for marsupialization.

참고 문헌

- Jang CS, Kim JW, Yang SB, Yim JH, Kim JY, Yang BE. Treatment of large sized cystic lesion of the jaws with specific appliance for decompression: cases report. *J Korean Assoc Oral Maxillofac Surg* 2011; 37: 133-6
- Ikeshima A, Tamura Y. Differential diagnosis between dentigerous cyst and benign tumour with an embedded tooth. *J Oral Sci* 2002; 44: 13-7
- Bodner L, Woldenberg Y, Bar-Ziv J. Radiographic features of large cysts lesions of the jaws in children. *Pediatr Radiol* 2003; 33: 3-6
- Pekiner FZ, Borahan O, Ugurlu F. Clinical and radiological features of a large radicular cyst involving the entire maxillary sinus. *MUSBED* 2012; 2: 31-6
- Zhao YF, Wei JX, Wang SP. Treatment of odontogenic keratocysts: a follow-up of 255 chinese patients. *Oral Surg Oral Med Oral Pathol Oral Radiol Endod* 2002; 94: 151-6
- Giuliani M, Grossi GB, Lajolo C. Conservative management of a large odontogenic keratocyst: report of a case and review of the literature. *J Oral Maxillofac Surg* 2006; 64: 308-16
- Brannon RB. The odontogenic keratocyst. A clinicopathologic study of 312 cases. Part II. Histologic features. *Oral Surg Oral Med Oral Pathol* 1977; 43(2): 233-55
- Crowley TE, Kaugars GE, Gunsolley JC. Odontogenic keratocysts: a clinical and histologic comparison of the parakeratin and orthokeratin variants. *J Oral Maxillofac Surg* 1992; 50(1): 22-6
- Kaczmarzyk T, Mojsa I, Stypulkowska J. A systematic review of the recurrence rate for keratocystic odontogenic tumour in relation to treatment modalities. *Int J Oral Maxillofac Surg* 2012; 41(6): 756-67
- Karamanis S, Kitharas T, Tsoukalas D. Implant placement after marsupialization of a dentigerous cyst. *J Oral Implantol* 2006; 32: 313-6
- Partsch C. Uber Kiefercysten. *Deutsche Monatsschrift Fur Zahnheilkunde* 1892; 10: 271-304
- Partsch C. Zur behandlung der kieferzysten. *Deutsche Monatsschrift Fur Zahnheilkunde*. 1910; 28: 252-60
- Borgonovo AE, Di Laschia S, Grossi G, Maiorana C. Two-stage treatment protocol of keratocystic odontogenic tumour in young patients with Gorlin-Goltz syndrome: Marsupialization and later enucleation with peripheral ostectomy. A 5-year-follow-up experience. *Int J Pediatr Otorhinolaryng* 2011; 75: 1565-71
- Sailer HF, Pajarola GF. *Oral Surgery for the General Dentist*, Thieme, New York, 1999.
- Riachi F, Tabarani C. Effective management of large radicular cysts using surgical enucleation vs. marsupialization two cases report. *Int Arab J Dent* 2010; 1: 45-51
- Gao L, Wang XL, Li SM, Chen C, Li JW, Yan XJ, Zhang J, Ren WH, Zhi KQ. Decompression as a treatment for odontogenic cystic lesions of the jaw. *J Oral Maxillofac Surg* 2014; 72(2): 327-33
- Zhao Y, Liu B, Han QB, Wang SP, Wang YN. Changes in bone density and cyst volume after marsupialization of mandibular odontogenic keratocysts (keratocystic odontogenic tumors). *J Oral Maxillofac Surg* 2011; 69(5): 1361-6
- Shudou H, Sasaki M, Yamashiro T, Tsunomachi S, Takenoshita Y, Kubota Y, Ninomiya T, Kawazu T, Mori Y. Marsupialisation for keratocystic odontogenic tumours in the mandible: longitudinal image analysis of tumour size using 3D visualized CT scans. *Int J Oral Maxillofac Surg* 2012; 41(3): 290-6
- Kubota Y, Imajo I, Itonaga R, Takenoshita Y. Effects of the patient's age and the size of the primary lesion on the speed of shrinkage after marsupialisation of keratocystic odontogenic tumours, dentigerous cysts, and radicular cysts. *Br J Oral Maxillofac Surg* 2013; 51(4): 358-62
- Pogrel MA. Treatment of keratocysts: the case for decompression and marsupialization. *J Oral Maxillofac Surg* 2005; 63: 1667-73
- Lapeer GL. The use of marsupialization in resolving

• 참고 문헌 •

- a dentigerous cystic lesion: a case presentation. *J Can Dent Assoc* 1985; 51: 569-70
22. de Molon RS, Verzola MH, Pires LC, Mascarenhas VI, da Silva RB, Cirelli JA, Barbeiro RH. Five years follow-up of a keratocyst odontogenic tumor treated by marsupialization and enucleation: a case report and literature review. *Contemp Clin Dent* 2015; 6: S106-10
23. Marker P, Brondum N, Clausen PP, Bastian HL. Treatment of large odontogenic keratocysts by decompression and later cystectomy: a long-term follow-up and a histologic study of 23 cases. *Oral Surg Oral Med Oral Pathol Oral Radiol Endod* 1996; 82: 122-31
24. Sanchez-Siles M, Camacho-Alonso F, Lopez-Jornet P, Salazar-Sanchez N. Keratocystic odontogenic tumor. Case report and review of the literature. 2013; 79(2): 44-7
25. Kirtaniya BC, Sachder V, Singla A, Sharma AK. Marsupialization: a conservative approach for treating dentigerous cyst in children in the mixed dentition. *J Indian Soc Pedod Prev Dent* 2010; 28: 203-8