

## 1

# Clinical effect of calcium chelating and deproteinizing agent containing dental conditioning gel on alleviation of peri-implant mucosa inflammation

<sup>1</sup>Department of Periodontology, Dankook University of Dentistry, Cheonan, Republic of Korea

<sup>2</sup>Central Research Institute, Nano Intelligent Biomedical Engineering Corporation(NIBEC), Seoul, Republic of Korea

Kwang-Heon Yang<sup>1</sup>, Jue-Yeon Lee<sup>2</sup>, Jin-Hyung Jung<sup>1</sup>, Hyun-Seung Shin<sup>1</sup>, In-Woo Cho<sup>1</sup>\*

## ABSTRACT

### Clinical effect of calcium chelating and deproteinizing agent containing dental conditioning gel on alleviation of peri-implant mucosa inflammation

<sup>1</sup>Department of Periodontology, Dankook University of Dentistry, Cheonan, Republic of Korea

<sup>2</sup>Central Research Institute, Nano Intelligent Biomedical Engineering Corporation(NIBEC), Seoul, Republic of Korea

Kwang-Heon Yang<sup>1</sup>, Jue-Yeon Lee<sup>2</sup>, Jin-Hyung Jung<sup>1</sup>, Hyun-Seung Shin<sup>1</sup>, In-Woo Cho<sup>1</sup>\*

**Purpose :** The purpose of this clinical study was to evaluate the effect of chelating and deproteinizing agent containing dental conditioning gel on alleviation of peri-implant mucosa inflammation.

**Methods:** 36 patients with functionally loaded implants for at least 1 year and have clinical signs of peri-implant mucositis were recruited. At baseline, all implants received subgingival prophylaxis with ultrasonic scaler. In the test group, patients were provided a chelating and deproteinizing agent dental conditioning gel (Clinplant<sup>®</sup>) and were given instructions to apply it around the implants using an interdental brush for 2 weeks. Chlorhexidine and saline were provided to the positive control group and negative control group, respectively. The modified sulcus bleeding index (mSBI), modified plaque index (mPI), and probing pocket depth (PPD) were evaluated at baseline, 1 week, and 2 weeks.

**Results:** In the Clinplant<sup>®</sup> and chlorhexidine group, mSBI (-0.81, -0.85 respectively;  $p < 0.01$ ), mPI (-0.46, -0.5 respectively;  $p < 0.01$ ), and PPD (-0.58, -0.48 respectively;  $p < 0.01$ ) at 2 weeks were significantly reduced from baseline. In the saline group, all the clinical parameters were reduced but there was no statistical significance. The saline may be attributed to the influence of prophylaxis at baseline.

**Conclusions:** The present study demonstrated the beneficial clinical effects of chelating and deproteinizing agent containing dental conditioning gel to decrease peri-implant mucosa inflammation equivalent to chlorhexidine. This dental conditioning gel might be useful for alleviation of peri-implant mucosa inflammation.

**Key words :** Dental implants, peri-implantitis, chelating agent, chlorhexidine

Corresponding Author

In-Woo Cho

Department of Periodontology, Dankook University School of Dentistry, 119 Dandae-ro, Dongnam-gu, Cheonan 330-714, Korea

E-mail : sinuslift@dankook.ac.kr, Tel : +82-41-550-0261, Fax : +82-303-3442-7364

## I . INTRODUCTION

Replacement of tooth with dental implants is one of the most frequently used and successful surgical procedures. Dental implants based on the Branemark's researches were introduced in 1971, which characterization of interfacial bone formation at titanium implant surfaces and demonstration of excellent osseointegration. After decades of subsequent research in industry and academia, implants have evolved with a high percentage of survival rate and longevity. While dental implants have been reported to achieve long-term success in many cases, they are not immune from the biologic complications inflammatory reaction in the peri-implant. Peri-implant diseases present in two forms - peri-implant mucositis and peri-implantitis. Peri-implant mucositis has been described as a disease in which the presence of inflammation is confined to the soft tissues surrounding a dental implant with no signs of loss of supporting bone following initial bone remodeling during healing. The key parameter for its diagnosis is bleeding upon gentle probing(BOP). Peri-implantitis has been characterized by an inflammatory process around an implant, which includes both soft tissue inflammation and progressive loss of supporting bone beyond biological bone remodeling<sup>1)</sup>.

Peri-implant mucositis is common complication of dental implant treatment. Roos-Jansåker. et al. reported that 79.2% of the patients would have been experienced peri-implant mucositis<sup>2)</sup>. According to a cause-related concept, the

disruption of bacteria and endotoxin was defined as primary objective for the treatment of peri-implant diseases. Several studies have been reported that using distilled water, hydrogen peroxide solution, chlorhexidine, and saline for treatment of peri-implant mucositis<sup>3, 4)</sup>. Among them, chlorhexidine suppress the pathogenic bacteria often associated with peri-implant inflammation and saline can be effective in managing implant surface decontamination<sup>5, 6)</sup>. But saline doesn't have anti-bacterial effects, and chlorhexidine has bad taste. And the effect of chlorhexidine and saline on the implant surface for long term period was not fully investigated.

Chelating and deproteinizing agent containing dental conditioning gel (Clinplant<sup>®</sup>) was developed to remove smear layer and inhibit bacterial activity<sup>7)</sup>. The purpose of this study is to investigate Clinplant<sup>®</sup> can give beneficial effect on the peri-implant mucositis treatment. The clinical effect of Clinplant<sup>®</sup>, chlorhexidine, and saline on peri-implant mucosa inflammation was examined at 1 and 2 week intervals by the modified sulcus bleeding index (mSI), the modified plaque index (mPI), and probing depth (PD). In addition, the scanning electron microscopy observation was performed to verify the removal of smear layer on the enamel surface of tooth.

## II . MATERIALS AND METHODS

### Materials

3% (w/w) carboxymethyl cellulose was

dissolved in isotonic sodium chloride solution (saline) was used as a negative control. The same CMC gel containing 0.5% Chlorhexidine digluconate was used as a positive control. Both of gels were filled in a same syringe with Clinplant<sup>®</sup>. Clinplant<sup>®</sup> was provided from NIBEC (Jincheon, Korea). These products and proximal brush were provided to patients.

### Clinical study

Among patients who visited Dankook university dental hospital, the patients who got implants and had functional loading for over than 1 year were included in the study. The experimental protocol was reviewed and approved by Institutional Review Board of Dankook university dental hospital in 2012 (IRB No. H-1111/010/005). Inclusion criteria are subjects between 20 to 65 years of age and agreed to sign an informed consent, participate, and return for follow up visits. Subject has an implant that is in function with peri-implant mucositis. Exclusion criteria are patient who has history of taking antibiotics in recent 3 months and is wearing an appliance that can affect the oral hygiene such as orthodontic appliance, partial denture, and full denture. Women who are nursing or pregnant were excluded.

All the patients who met the inclusion and exclusion criteria went through a screening before treatment as in the following order. The present study conformed to Helsinki Declaration. A written consent was obtained from the subjects. The subjects were allowed to

participate in the experimental program after they were informed about the test and signing an informed consent. We informed the subjects about the security of personal information and that it is going to be used only for the present study.

This study was a single blinded, parallel, randomized clinical trial which included 36 subjects, both male and females between the ages of 20 to 65. Patients received an oral soft and hard tissue assessment as well as a baseline examination prior to their prophylaxis which included the mSBI, mPI, and PD. After the baseline examination, subjects received implant cleaning with a titanium implant scaler (Atria, USA) and were instructed and motivated in oral hygiene. Subjects were randomly assigned to the three groups: 1) test group is Clinplant<sup>®</sup> treatment; 2) positive control group is Chlorhexidine treatment; 3) negative control group is saline treatment. The subjects were indicated to apply the material two times in a day for two weeks with proximal brush. The subjects were allowed to use it only at the affected area after teeth brushing. Measurements were performed at 1 and 2 weeks after treatment.

The following clinical parameters were evaluated in the three treatment groups: 1) modified sulcus bleeding index (mSBI)<sup>8)</sup>, Score 0 : No bleeding on probing. Score 1 : Speckled bleeding on probing. Score 2 : Linear bleeding at gingival margin on probing. Score 3 : Abundant bleeding on probing; 2) modified plaque index (mPI), Score 0 : Absence of plaque deposit, Score 1 : Plaque disclosed after running the periodontal

probe along the gingival margin, Score 2 : Visible plaque, Score 3 : Abundant plaque; 3) Probing depth at four sites (PD). PD was assessed at 4 sites per implant: facial, mesial, lingual, and distal. One standardized examiner blinded to the subjects' assignment of treatment performed all the clinical measurements.

### Preparation of human enamel slices and SEM

Teeth had been extracted as a part of routine treatment at the Department of Periodontology, Seoul National University. Patients' consents had been obtained according to the guidelines of the School of dentistry for the use of human samples in research. Teeth were immediately extracted, root were removed, crown were vertically cut (approximately 4X4X1 mm in size) using a low speed diamond saw under water irrigation. The enamel was sliced and stored in phosphate-buffered saline (PBS), pH 7.4 at 4°C until use. The enamel slices were applied the Clinplant® for 2 min followed by washes in distilled water at three times. The controls were untreated enamel slices. Immediately after rinsing, the enamel slices were fixed in 2% glutaraldehyde in PBS for 15 min. After three 5-min PBS washes, the blocks were post-fixed with 1% OsO<sub>4</sub> in 0.1 M PBS buffer for 30 min at room temperature and then rinsed in 0.1 M PBS buffer for 10 min and twice with distilled water for 10 min. Samples were then dehydrated twice for 10 min in a sequence of 70%, 80%, 90%, and 95% ethanol solutions and twice for 10 min in 100%

ethanol. The samples were freeze-dried and mounted on aluminum plates. The dried samples were coated with gold and observed by field emission scanning electron microscope (FE-SEM, Jeol, S-4700, Japan) at voltage of 15kV.

### Statistical analysis

The value measured at each time was statistically analyzed by using SPSS ver. 13.0 for Windows. The change in clinical score over time in each group was analyzed by Wilcoxon signed ranks test. P values of < 0.05 were considered to be statistically significant.

## III. RESULTS

### Decrease of peri-implant mucosa inflammation in clinical study

36 patients among 51 participants finished the clinical test. Thirteen patients were included in test (Clinplant®) group and positive control (Chlorhexidine) group, respectively. Ten patients were included in negative control (saline) group. Side effects were not reported during the clinical test period.

*The change in modified SBI (mSBI)* The change in mSBI showed statistical significance between baseline and 1 week, baseline and 2 weeks in all three groups (Table 1). The amount of reduced score during 0-1 week period was 0.66 in Clinplant® group, 0.54 in chlorhexidine group, and 0.66 in saline group. However, during 1-2weeks, Clinplant® group and Chlorhexidine

group showed 0.16 and 0.31 reduction respectively, and saline group showed 0.16 increase. The improvement in bleeding tendency was decreased during 1-2 week period. Comparing the change of clinical score during baseline to 2 weeks, Clinplant<sup>®</sup> group (0.82, 65%) and chlorhexidine group (0.85, 51%) showed more improvement than saline group (0.5, 38%) (Fig. 1). The change of mSBI from 2 weeks to baseline in Clinplant<sup>®</sup> and chlorhexidine group was significant different from saline group.

**The change in modified plaque index (mPI)**

Clinplant<sup>®</sup> group showed significant reduction in mPI from baseline ( $1.08 \pm 0.33$ ) to 1 week ( $0.69 \pm 0.57$ ,  $p < 0.05$ ) and baseline to 2 weeks ( $0.62 \pm 0.40$ ,  $p < 0.01$ ) (Table 2). Chlorhexidine group also showed significant reduction in mPI from baseline ( $1.00 \pm 0.34$ ) to 1 week ( $0.65 \pm 0.41$ ,  $p < 0.05$ ) and baseline to 2 weeks ( $0.50 \pm 0.44$ ,  $p < 0.01$ ). On the other hand, saline group showed 0.59 reduction at 1week ( $0.58 \pm 0.53$ ) compared with baseline ( $1.17 \pm 0.62$ ) and 0.17 increase at 2 weeks ( $0.75 \pm 0.48$ ) compared with 1 week with no statistical significance. The change of mPI from 2 weeks to baseline in Clinplant<sup>®</sup> and

Table 1. mSBI index at baseline, 1, and 2 weeks. \* $p < 0.05$  vs. at baseline for each groups and \*\* $p < 0.01$  vs. at baseline for each groups.

	baseline	1week	2weeks	0-1 weeks	Change 1-2weeks	0-2weeks
Clinplant <sup>®</sup>	$1.62 \pm 0.49$	$0.96 \pm 0.69$	$0.80 \pm 0.54$	-0.66**	-0.16	-0.82**
Chlorhexidine	$1.31 \pm 0.50$	$0.77 \pm 0.54$	$0.46 \pm 0.66$	-0.54*	-0.31	-0.85**
Saline	$1.33 \pm 0.37$	$0.67 \pm 0.37$	$0.83 \pm 0.37$	-0.66*	+0.16	-0.5*

- : reduction

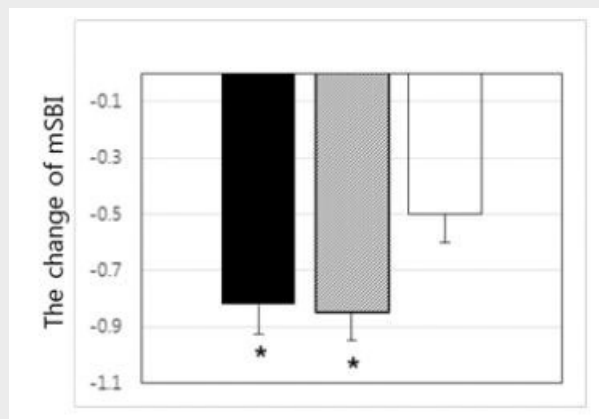


Fig 1. The change of mSBI index between 2 week and baseline. The data are expressed as the mean  $\pm$  SD from in each group. Clinplant<sup>®</sup> (■), Chlorhexidine (□), saline treated group (▨). \* $p < 0.05$  vs. at saline group.

chlorhexidine group was not significant different from saline group (Fig. 2).

**The change in probing depth** Clinplant® group showed significant reduction in probing depth between baseline ( $4.13 \pm 0.89$ ) to 2 weeks ( $3.56 \pm 0.88$ ,  $p < 0.05$ ) (Table 3). Chlorhexidine group also showed significant reduction in mPI during baseline ( $3.44 \pm 1.11$ ) to 1 week ( $3.12 \pm 1.23$ ,  $p < 0.05$ ), and baseline to 2 weeks ( $2.96 \pm 1.05$ ,  $p < 0.05$ ). On the other hand, saline group showed 0.54 mm reduction at 2 week ( $2.92 \pm 1.17$ ) compared with baseline ( $3.46 \pm 1.28$ ) with no

statistical significance.

The change of PD from 2 weeks to baseline in Clinplant® and chlorhexidine group was not significant different from saline group (Fig. 3)

### Removal of smear layer on enamel slices

Fig. 4 shows the surface of enamel slice treated with Clinplant®, chlorhexidine, and saline. The surfaces of samples treated with Clinplant® for 2 min showed removal of the smear layer and

Table 2. mPI index at baseline, 1, and 2 weeks. \* $p < 0.05$  vs. at baseline for each groups and \*\* $p < 0.01$  vs. at baseline for each groups.

	baseline	1 week	2 weeks	0-1 weeks	Change 1-2 weeks	0-2 weeks
Clinplant®	$1.08 \pm 0.33$	$0.69 \pm 0.57$	$0.62 \pm 0.40$	-0.39*	-0.07	-0.46**
Chlorhexidine	$1.00 \pm 0.34$	$0.65 \pm 0.41$	$0.50 \pm 0.44$	-0.35*	-0.15	-0.50**
Saline	$1.17 \pm 0.62$	$0.58 \pm 0.53$	$0.75 \pm 0.48$	-0.59	+0.17	-0.42

- : reduction

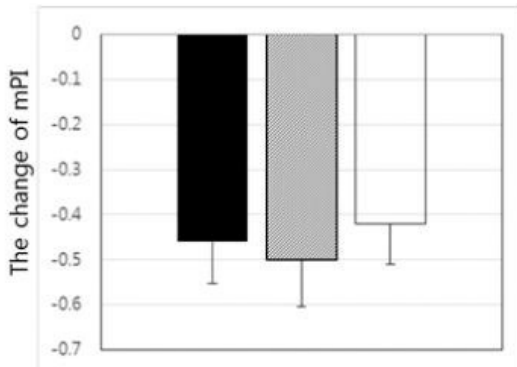


Fig. 2. The change of mPI index between 2 week and baseline. The data are expressed as the mean  $\pm$  SD from in each group. Clinplant® (■), Chlorhexidine (□), saline treated group (▨). \* $p < 0.05$  vs. at saline group.

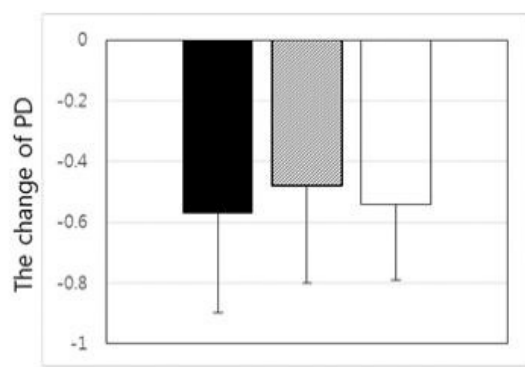


Fig. 3. The change of PD between 2 week and baseline. The data are expressed as the mean  $\pm$  SD from in each group. Clinplant® (■), Chlorhexidine (□), saline treated group (▨). \* $p < 0.05$  vs. at saline group.

displayed widened enamel pore (Fig. 4A). The surface of tooth was free of debris and the dentinal tubule entrances were visible. Chlorhexidine and saline treated specimens showed residual calculus and amorphous debris on the surface (Fig. 4B and C). It was revealed a thick and mineralized smear layer and enamel pores were not observed.

#### IV. DISCUSSION

The effect of chelating and deproteinizing agent containing dental conditioning gel on the

treatment of peri-implant mucositis was investigated in this study. The results of the current study indicate that Clinplant<sup>®</sup> treated group and chlorhexidine treated group were effective in reducing peri-implant mucositis during 2 week experimental period. Chlorhexidine is used to prevent the formation of dental plaque and the reduction of gingivitis<sup>9)</sup>. Chlorhexidine can interact with anionic glycoproteins and phosphoproteins of teeth by binding to anionic groups (sulfate, phosphate and carboxyl groups). These properties enable chlorhexidine to bind to the bacterial wall and affect its adherence to teeth, thus initiating

Table 3. Probing depth index at baseline, 1, and 2 weeks (mm). \*p < 0.05 vs. at baseline for each groups and \*\*p < 0.01 vs. at baseline for each groups.

	baseline	1week	2weeks	0-1weeks	Change 1-2weeks	0-2weeks
Clinplant <sup>®</sup>	4.13±0.89	3.73±1.02	3.56±0.88	-0.40	-0.17	-0.57*
Chlorhexidine	3.44±1.11	3.12±1.23	2.96±1.05	-0.32	-0.16	-0.48*
Saline	3.46±1.28	3.04±1.42	2.92±1.17	-0.42	-0.12	-0.54

- : reduction

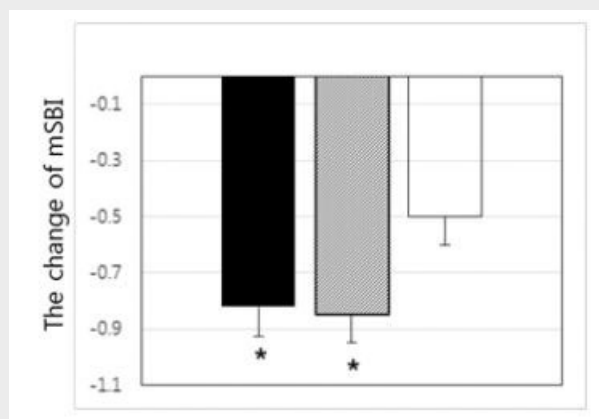


Fig. 4. Surface morphology of human enamel slices after treatment with (A) Clinplant<sup>®</sup>, (B) chlorhexidine, and (C) saline. The enamel pores (→) were observed on the surface of treated with Clinplant<sup>®</sup>. Amorphous smear layer and debris (△) were observed on the surface of treated with chlorhexidine and saline.

bacterial destruction<sup>10</sup>). Several animal and human experiments have been reported that mechanical debridement supplemented with chlorhexidine resulted in the suppression of the pathogenic bacteria often associated with peri-implant inflammation<sup>3</sup>). Brex et al. reported that fewer bacterial count in the chlorhexidine rinse specimens as compared to the water specimens after 24 hours when plastic film applied to buccal surface of maxillary first premolar<sup>9</sup>).

Our results agreement with previous studies, showed reduced mSBI, mPI, and PD in chlorhexidine group. Clinplant<sup>®</sup> group also showed decreased mSBI, mPI, and PD after 2 weeks treatment and had significant differences with baseline. In present study, the bleeding tendency of the marginal peri-implant tissues was evaluated using a mSBI<sup>8</sup>). Similar decrease of mSBI between chlorhexidine group (-0.82, 65%) and Clinplant<sup>®</sup> group (-0.85, 51%), while saline group appeared less decrease of mSBI during baseline to 2 weeks (-0.5, 38%), rather increase during 1-2weeks. Bleeding on probing (BOP) is a useful clinical parameter for predicting peri-implant and periodontal attachment loss<sup>11, 12</sup>). During baseline to 2 weeks, mPI significantly decrease in both chlorhexidine group (0.50) and Clinplant<sup>®</sup> group (0.46). Although saline group showed decrease of mPI (0.42), it has no statistical significance from baseline. Decrease of PI indicates reduce of bacterial adhesion, thus Clinplant<sup>®</sup> and chlorhexidine have the effect of antimicrobial activity.

Clinplant<sup>®</sup> has been demonstrated demineralization of smear layer and antimicrobial activity

for aerobic and anaerobic bacterial. In addition, it can remove the E.coli-derived lipopolysaccharide<sup>7</sup>). Yoshida et al. reported anti-bacterial effect of EDTA in clinical study<sup>13</sup>). When 15% EDTA solution with ultrasonic scaler was used, more anti-bacterial effect was obtained than saline solution with ultrasonic scaler. Bacterial lipopolysaccharides (LPS) are chelated with Mg<sup>2+</sup>, subsequently dissociated from bacteria when treated with EDTA. DePamphilis et al. reported that LPS membrane is partially dissociated by treatment with EDTA and fully dissociated upon further treatment with Triton X-100<sup>14</sup>). 0.1~0.5% Triton X-100 has been used as a permeabilizing agent in eukaryotic cell and preparations with concentrations higher than 1% Triton X-100 has the ability to permeabilize the bacterial cell wall<sup>15</sup>). Schnaitman et al. reported that Triton X-100 removed about 50% of LPS from E.coli without affecting the normal morphology of the cell wall<sup>15</sup>). LPS is known as one of inflammatory inducing factor. Therefore, it can be expected that applying Clinplant<sup>®</sup> can relief peri-implant mucositis by eliminate of LPS. Although chlorhexidine is proved to be an effective medicine for peri-implantitis, it has numerous drawbacks for patients like tooth staining, calculus accumulation, and bitter taste sensation<sup>5, 16, 17</sup>). Hence, it is important to find another medicine that is effective as chlorhexidine with less side effects. EDTA containing Clinplant<sup>®</sup> has not the side effect like that of chlorhexidine and can exert its activity at neutral pH without soft tissue damage.

Treatment of enamel with Clinplant<sup>®</sup> resulted

in disappearance of amorphous smear layer. In contrast, treatment of chlorhexidine and saline was not effective for the removal of smear layer. The smear layer has been described as a layer composed of very small particles of mineralized collagen matrix and it may serve as a physical barrier for a connective tissue attachment to the root surface<sup>18, 19)</sup>. It has been shown that EDTA treatment of root dentin by the burnishing action results in removal of the smear layer<sup>20)</sup>. In the current study, enamel surfaces treated with EDTA containing dental conditioning gel was effective for the removal of smear layer. The Clinplant<sup>®</sup> treatment might be helpful to reattach

of connective tissue.

In conclusion, Clinplant<sup>®</sup> showed significant beneficial clinical effects for the treatment of peri-implant mucositis within the scope of present study. Clinplant<sup>®</sup> showed similar therapeutic effect as chlorhexidine for 2 weeks short period observation. The limitation of present study is that it included only a small number of subjects and showed variation of baseline score among groups. Randomized controlled clinical studies with larger subjects and longer period of follow up are required to demonstrate the long term therapy as an alternative to chlorhexidine treatment.

**CONFLICT OF INTEREST**

No potential conflict of interest relevant to this article was reported.

**ACKNOWLEDGEMENTS**

This research was supported by the Bio & Medical Technology Development Program of the National Research Foundation (NRF) funded by the Ministry of Science, ICT & Future Planning (#NRF-2014M3A9E3064431).

## 참고 문헌

1. Sanz M, Chapple IL, Working Group 4 of the VEWoP. Clinical research on peri-implant diseases: consensus report of Working Group 4. *J Clin Periodontol* 2012;39 Suppl 12:202-6.
2. Roos-Jansaker AM, Lindahl C, Renvert H, Renvert S. Nine- to fourteen-year follow-up of implant treatment. Part II: presence of peri-implant lesions. *J Clin Periodontol* 2006;33:290-5.
3. Trejo PM, Bonaventura G, Weng D, Caffesse RG, Bragger U, Lang NP. Effect of mechanical and antiseptic therapy on peri-implant mucositis: an experimental study in monkeys. *Clin Oral Implants Res* 2006;17:294-304.
4. Porras R, Anderson GB, Caffesse R, Narendran S, Trejo PM. Clinical response to 2 different therapeutic regimens to treat peri-implant mucositis. *J Periodontol* 2002;73:1118-25.
5. Addy M, Prayitno S, Taylor L, Cadogan S. In vitro Study of the Role of Dietary Factors in the Etiology of Tooth Staining Associated with the Use of Chlorhexidine. *Journal of Periodontal Research* 1979;14:403-10.
6. Prayitno S, Taylor L, Cadogan S, Addy M. An in vivo study of dietary factors in the aetiology of tooth staining associated with the use of chlorhexidine. *J Periodontal Res* 1979;14:411-7.
7. Lee JY, Seol YJ, Park JR, Park YJ, Chung CP. Biological effects of a root conditioning agent for dentin surface modification in vitro. *J Periodontal Implant Sci* 2010;40:257-64.
8. Mombelli A, van Oosten MA, Schurch E, Jr., Land NP. The microbiota associated with successful or failing osseointegrated titanium implants. *Oral Microbiol Immunol* 1987;2:145-51.
9. Brex M, Theilade J. Effect of Chlorhexidine Rinses on the Morphology of Early Dental Plaque Formed on Plastic Film. *Journal of Clinical Periodontology* 1984;11:553-64.
10. Davies A. The mode of action of chlorhexidine. *J Periodontal Res Suppl* 1973;12:68-75.
11. Lang NP, Joss A, Orsanic T, Guberti FA, Siegrist BE. Bleeding on probing. A predictor for the progression of periodontal disease? *J Clin Periodontol* 1986;13:590-6.
12. Luterbacher S, Mayfield L, Bragger U, Lang NP. Diagnostic characteristics of clinical and microbiological tests for monitoring periodontal and peri-implant mucosal tissue conditions during supportive periodontal therapy (SPT). *Clin Oral Implants Res* 2000;11:521-9.
13. Yoshida T, Shibata T, Shinohara T, Gomyo S, Sekine I. Clinical evaluation of the efficacy of EDTA solution as an endodontic irrigant. *J Endod* 1995;21:592-3.
14. Depamphi MI. Dissociation and Reassembly of Escherichia-Coli Outer Membrane and of Lipopolysaccharide, and Their Reassembly onto Flagellar Basal Bodies. *Journal of Bacteriology* 1971;105:1184-&.
15. Schnaitman CA. Effect of ethylenediaminetetraacetic acid, Triton X-100, and lysozyme on the morphology and chemical composition of isolate cell walls of Escherichia coli. *J Bacteriol* 1971;108:553-63.
16. Hoyos DF, Murray JJ, Shaw L. The effect of chlorhexidine gel on plaque and gingivitis in children. *Br Dent J* 1977;142:366-9.
17. Rushton A. Safety of Hibitane. II. Human experience. *J Clin Periodontol* 1977;4:73-9.
18. Polson AM, Frederick GT, Ladenheim S, Hanes PJ. The production of a root surface smear layer by instrumentation and its removal by citric acid. *J Periodontol* 1984;55:443-6.
19. Pashley DH. Smear layer: physiological considerations. *Oper Dent Suppl* 1984;3:13-29.
20. Blomlof J. Root cementum appearance in healthy monkeys and periodontitis-prone patients after different etching modalities. *J Clin Periodontol* 1996;23:12-8.