

2

재생술식을 이용한 치근단 병소를 동반한 백악질 열리의 치료

¹⁾이화여자대학교 의학전문대학원부속 목동병원 치주과, ²⁾이화여자대학교 의학전문대학원 치주과학교실
강 효 진¹⁾, 정 겨 운¹⁾, 방 은 경^{1,2)}

ABSTRACT

Treatment of cemental tear associated with periapical lesion using regenerative surgery; A case report

¹⁾Department of Periodontology, Mokdong Hospital, Ewha Womans University,
²⁾Department of Periodontology, School of Medicine, Ewha Womans University
Hyo-Jin Kang¹⁾, Gyu-Un Jung¹⁾, Eun-Kyoung Pang^{1,2)}

Purpose: Cemental tear is a specific type of root surface fracture characterized by a complete separation of a cemental fragment along the cementodentinal junction or a partial split within the cementum along an incremental line. It is suggested to be a factor for periodontal or periapical tissue destruction. The aim of this study is to present a diagnosis and treatment of cemental tear associated with periapical lesion with root canal treatment and regenerative periodontal surgery.

Treatments: A 60-year-old male who had a history of sports trauma on the mandibular right central incisor about 10 years ago presented with apical cemental tear. Clinical examination showed a slightly dark yellowish discoloration and sinus tract that was located on the apical labial mucosa. The mobility and percussion were also assessed on the diseased tooth and recorded as Miller-Øs Class II and tenderness to percussion. The probing depth was within the normal limit (<3 mm). Radiographic examination revealed a radiolucent lesion at the apical area and extended to distal aspect of the tooth along the fragment of cemental tear. After root canal treatment, periapical surgery was performed. The bony defect was exposed and then the detached root fragment was removed. Apical root resection and retrograde filling with Mineral Trioxide Aggregate (MTA) were accomplished and the bony defect was filled with deproteinized bovine bone mineral (DBBM) and covered with biodegradable collagen membrane.

Results: After 9-month follow-up, healing of the mandibular right central incisor was uneventful and no swelling, purulence or pain was revealed in the associated area. Probing pocket depth was favorably stable, and the tooth mobility was decreased to the Miller's Class I.

Conclusions: Apical cemental tear associated periapical lesion could be successfully treated with removal of the detached cementum in combination with apical surgery and GTR procedure.

Key words : cemental tear, guided tissue regeneration, periapical disease

Corresponding Author

Eun-Kyoung Pang

Department of Periodontology, School of Medicine, Ewha Womans University, 1071 Anyangcheon-ro, Yangcheon-gu, Seoul 07985, Korea.

Tel : +82-2-2650-2725, Fax : +82-2-2650-5764, E-mail : ekpang@ewha.ac.kr

I. INTRODUCTION

Cemental tear is defined as a complete separation of a cemental fragment along the cementodentinal junction or a partial split within the cementum along an incremental line¹⁾. Cemental tear is suggested to be a factor for periodontal or periapical tissue destruction¹⁻⁵⁾. Cemental tears present as a periodontal defect that is similar to a periodontal-endodontic lesion or a vertical root fracture⁴⁾. Intraoral periapical revealed vertical radiolucent line extending from the apex along the mesial/distal aspect of the root. Careful radiographic analysis frequently didn't detect a vertical radiolucent line in the root structure. Persistent endodontic lesion with sinus tract at the cemental tear site is also reported in previous study⁵⁾. Cemental tears primarily affect single-rooted teeth such as incisors and premolars, and more often observed in men older than 60 years of age^{6, 7)}. The mechanism of cemental tears is currently unknown, but several etiologic factors that lead to the tearing of the cementum are including age, occlusal trauma, traumatic event or attrition^{1, 3, 4, 7-10)}. Previous reports also described that intrinsic structure weakness of cementodentinal junction is possible predisposing factors for cemental tears.¹¹⁾

The removal of fractured root fragment is crucial for the successful treatment of cemental tear. Cemental tears can be removed by scaling and root planing, with or without periodontal surgery^{1, 6)}. Haney et al.²⁾ reported the successful treatment of a deep pocket associated with a cemental tear using a bone graft. Müller¹²⁾ reported

the successful treatment used a membrane to regenerate bone successfully and minimize probing depth. Harrel and Wright³⁾ also reported that removal of the detached cementum in combination with bone grafting using a minimally invasive surgical approach appears to have successfully corrected the periodontal destruction.

The present study describes a diagnosis and treatment of cemental tear associated with periapical lesion using root canal treatment combined with apical surgery and guided tissue regeneration(GTR) procedure.

II. TREATMENT PROCEDURES

1. Case description

A 60-year-old male was referred to the Endodontic Department of Ewha Womans University Medical Center for root canal treatment of the mandibular right central incisor. His chief complaints were mobility and discomfort of the mandibular right central incisor. He had a history of sports trauma about 10 years previously. His medical history was non-contributory.

On clinical examination, mandibular right central incisor had slightly dark yellowish color and did not respond to thermal and electric pulp testing. The tooth demonstrated Miller's Class II mobility and was tender to percussion and bite test. The probing depth of the tooth was within the normal limits(<3 mm) and sinus tract was observed on the apical side of labial mucosa. The

sinus tract was traced with gutta-percha cone and a periapical radiograph was taken (Fig. 1A). Radiographic examination revealed that the sinus tract originated from a radiolucent lesion located at the apical area of the mandibular right central incisor. Severe bone loss was verified by the cone-beam computed tomography (CBCT, Dinnova 3 (Hdxwill, Chungju, Korea)) at the apical, buccal and distal aspect of the mandibular right central incisor (Fig. 1B-D). The periapical lesion was extended to distal aspect of the mandibular right central incisor and the size was approximately 6 mm in diameter.

2. Diagnosis and treatment planning

The tooth was initially diagnosed with pulp necrosis with chronic apical abscess and root canal treatment was planned. During the root canal treatment, a vertical radiolucent line at the distal aspect of the mandibular right central incisor was detected by the periapical radiograph (Fig. 2A). It extended from the apex to the middle portion of the root along the bony defect. Based on the characteristic radiographic findings, a diagnosis of a cemental tear was made. After 3 appointments of nonsurgical endodontic treatment, the sinus tract was still

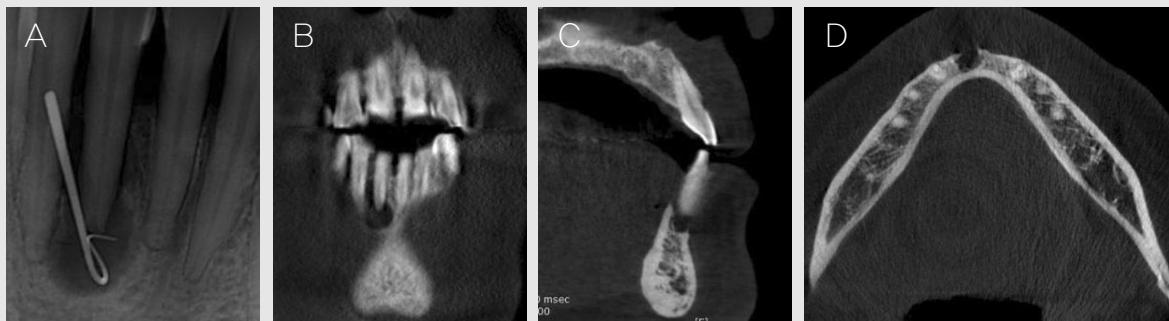


Fig. 1. Initial radiograph images. (A) Periapical radiographic finding of mandibular right central incisor, which is shown a periapical radiolucency with gutta-percha tracing. Radiolucent lesion showed approximately 6 mm in diameter at the apical area and extended to distal aspect of the mandibular right central incisor. CBCT images of mandibular right central incisor in (B) coronal, (C) sagittal and (D) horizontal section. Severe bone loss was observed at the apical, buccal and distal aspect of the mandibular right central incisor.

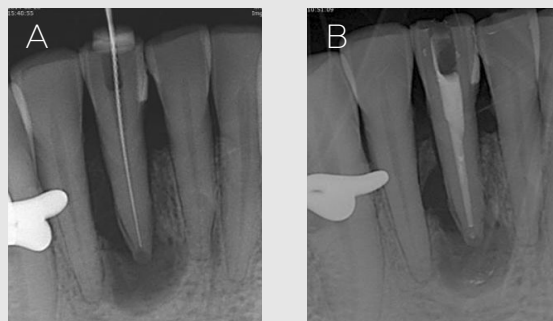


Fig. 2. Periapical radiographs during and after the root canal treatment of the mandibular right central incisor. (A) Periapical radiograph revealing a vertical radiolucent line extending from the apex to the middle portion of the root along the bony defect at the distal aspect of the tooth. (B) Periapical radiograph after filling of root canal with gutta-percha points.

present without a significant improvement. Therefore, the tooth was filled with gutta-percha points(Fig. 2B) and arranged for periapical surgery. As a treatment method to save the tooth, fragment removal, apicoectomy and regenerative procedure with both Periodontics and Endodontics departments were selected. Informed consent was obtained.

3. Surgical procedures

In preoperative view of the mandibular right central incisor, the sinus tract was still observed (Fig. 3). Under local anesthesia, a full thickness mucoperiosteal flap was reflected with intrasulcular incision and two vertical incisions were made on the distal line angle of right canine and left lateral incisor. Flap was elevated beyond the mucogingival junction for maximum exposure of the root surface(Fig. 4A). After removal of granulation tissue, a 2 x 3 x 0.5 mm hard tissue fragment was found separated from the root surface(Fig. 4B). Buccal bony dehiscence was observed and as shown in CBCT

image, severe bone loss was observed at the apical and the distal aspect of the mandibular right central incisor. The root surface was thoroughly scaled and root planed using curettes (Gracey, Hu-Friedy, Chicago, IL, USA) and root planing bur(ISO-No.832EF-204-014, Komet Brasseler, Lemgo, Germany) (Fig. 4C). Root resection was performed at the apex(Fig. 4D) and the root end was prepared for retrograde filling to get a fresh dentin surface at canal wall under microscope examination. Root surface was conditioned using tetracycline and sterile cotton pellet for 5 minutes(Fig. 4E) and followed by sterile saline solution irrigation. Mineral Trioxide Aggregate(MTA) (ProRoot MTA, Dentsply, Tulsa, OK) was placed at apical 2 mm (Fig. 4F). A deproteinized bovine bone mineral (DBBM) (Bio-Oss, Geistlich Pharma, Wolhusen, Switzerland) was placed in the bony defect(Fig. 4G) and covered with a bioabsorbable collagen membrane(Bio-Gide, Geistlich Pharma, Wolhusen, Switzerland) (Fig. 4H). The flap was repositioned to cover the membrane completely and sutured with 5-0 and 6-0 vicryl suture to

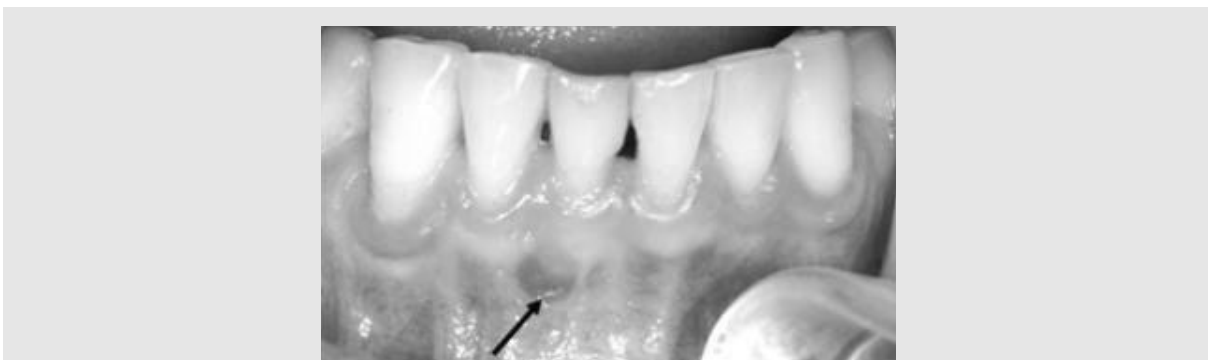


Fig. 3. Preoperative view of the mandibular right central incisor. Sinus tract was observed (arrow).

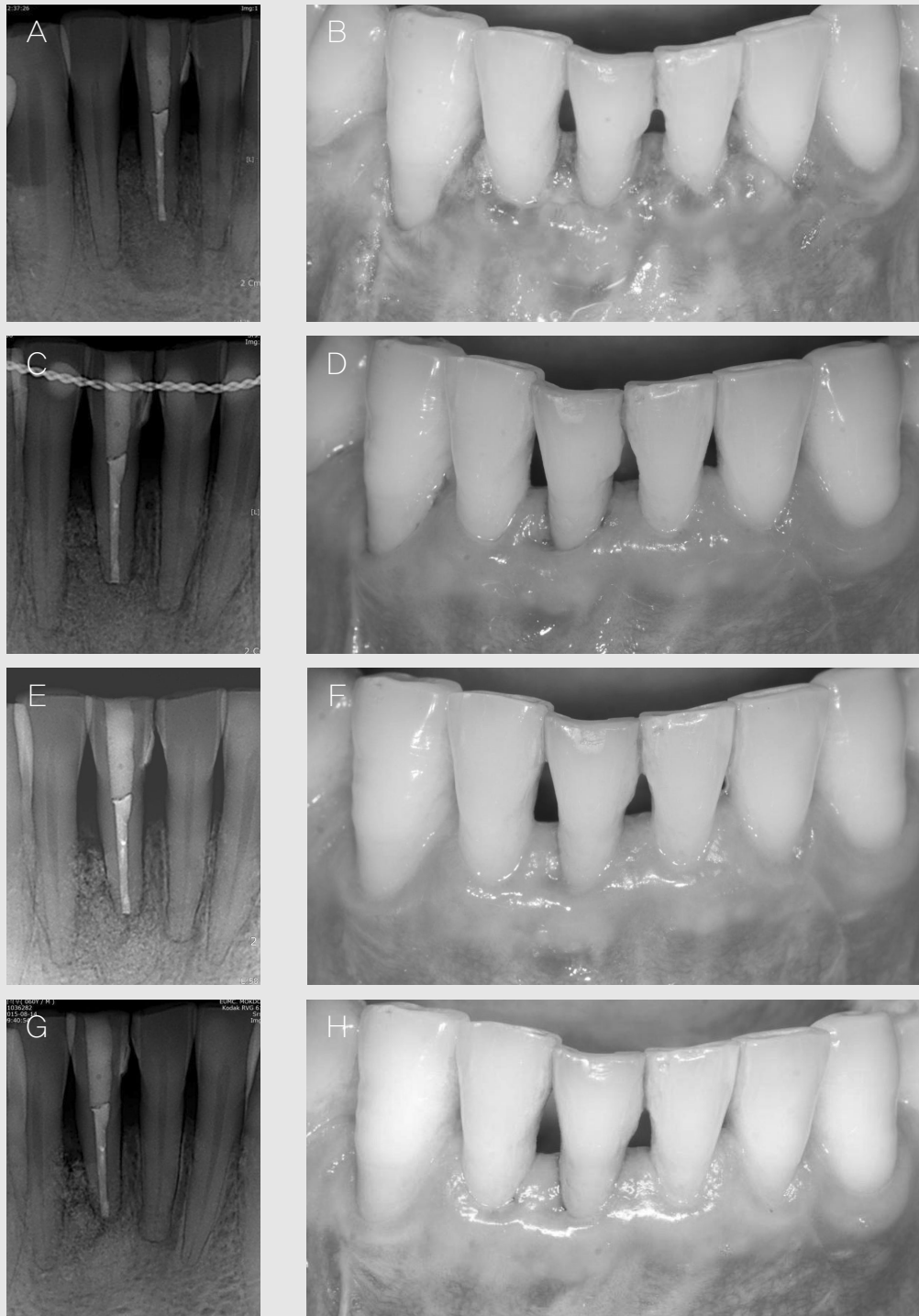


Fig. 5. (A, B) Periapical radiographs and clinical views of the mandibular central incisor after 2 weeks. (C, D) 1 month, (E, F) 3 months and (G, H) 9 months after surgery.

dine solution mouth rinse for 2 weeks.

The sutures were removed 2 weeks after surgery and resin-wire splint was placed from mandibular left canine to mandibular right canine. The patients returned for follow-up visits every 2 weeks thereafter and resin-wire splint was removed after 2 months.

III. RESULTS

During the healing period, the surgical area revealed uneventful healing(Fig 5). Sign of infection or suppuration were not observed during the healing period. Nine months after the surgery, the buccal sinus tract was disappeared and the probing depth around the mandibular central incisor was stably maintained within normal limits. However, 2-3 mm of gingival recession was seen on labial side of the tooth. The tooth mobility was decreased from Miller's Class II to Class I. Radiographic evaluation performed 1, 3, and 9 months after surgery showed stable alveolar bone level.

IV. DISCUSSION

Dental cementum is a hard tissue covering the root of a tooth and one of the periodontium that attaches the teeth to the alveolar bone by anchoring the periodontal ligament. The thickness of cementum increases throughout life¹³. Several different cementum varieties are found on human teeth. Acellular extrinsic fiber

cementum is mainly found on the cervical and middle root portions. On anterior teeth, it may also cover part of the apical root portion. It serves the exclusive function of anchoring the root to periodontal ligament. Cellular mixed stratified cementum covers the apical root portions and the furcations. Cellular intrinsic fiber cementum participates in the repair process of previously resorbed roots.

In an in vitro study, Noma et al¹⁴. showed that repeated loading on premolars can develop cementum crack in the cervix and extended toward the root apex with time. They used freshly extracted five mandible premolars and a compressive load of 5.0 kg was repeatedly applied along the tooth axis. They showed the crack from the cement-enamel junction to the root apex increased with time and suggested that repeated stresses may induce fatigue fracture on the root surface. Watanabe et al¹¹. suggested that intrinsic structural weakness of the cementum was possible predisposing factors for cemental tear and the crack occurred along the lamellar structure in thickened cellular cementum. Lin et al¹⁵. also reported that the thickened cementum in older individuals is prone to fracture relative to younger individuals and the separations were more often noted along the cementodentinal junction(77.6%) compared with separation within cementum(22.4%).

According to the previous report⁷), several etiologic factors including age, trauma, occlusal overloading, thicker cementum, higher fragility of cementum and previous periodontal treatment were reported. Maxillary or mandibular incisors

(76.1%) were most frequently affected by cemental tear and occurred more commonly in men(77.5%) and patients older than 60 years of age(73.2%), which was in accordance with the present case.

Ishikawa et al⁸⁾. reported 5 cases of cervical and 1 apical cemental tears. They explained that apical cemental tear caused by occlusal trauma. Lin et al¹⁵⁾. reported that cemental tears occurred more often in the middle third(45.3%) and apical third(41.5%) of root surface relative to cervical third. They described that for an anterior tooth, continuous excessive stress(such as attrition) could lead to cementum separation on the thicker site(such as the apical third) or on the tensional area(such as the middle third).

Pulpal necrosis occurred more often in traumatized teeth and tooth discoloration and the presence of sinus tract are the sign of necrotic pulp and periapical abscess. In present case, clinical examination of the mandibular right central incisor revealed the presence of sinus tract originating from the apex of the tooth and showed tooth discoloration(Fig 3). It also showed apical cemental tear associated with periapical lesion mimicking an endodontic lesion. Endodontic therapy was considered to be the first option for treatment. Because endodontic treatment alone cannot remove the fractured fragment, the sinus tract was still present without a significant improvement after 3 appointments of nonsurgical endodontic treatment. Clinical

resolution of the lesion was achieved with removal of fractured fragment and a combination of apicoectomy and guided tissue regeneration.

In the present case, the cause of cemental tear and pulp necrosis assumed to be a previous trauma. Because the cemental tear and pulp necrosis occurred at the same tooth, the bacteria might spread along the teared cementum and accelerate the bone resorption.

If the teeth with necrotic pulp are not responsive to conventional endodontic treatment, apical surgery is another option for the retreatment of teeth. Before and during endodontic treatment, radiographs should be carefully evaluated for the presence of cemental tears, especially for having traumatic history.

V. CONCLUSION

In conclusion, trauma may be considered as a potential etiologic factor for apical cemental tears. Apical cemental tear associated periapical lesion can be successfully treated with removal of the detached cementum in combination with regenerative procedure after root canal treatment.

CONFLICT OF INTEREST

No potential conflict of interest relevant to this article was reported.

참고 문헌

1. Leknes KN, Lie T, Selvig KA. Cemental tear: a risk factor in periodontal attachment loss. *J Periodontol* 1996;67:583-8.
2. Haney JM, Leknes KN, Lie T, Selvig KA, Wikesjo UM. Cemental tear related to rapid periodontal breakdown: a case report. *J Periodontol* 1992;63:220-4.
3. Harrel SK, Wright JM. Treatment of periodontal destruction associated with a cemental tear using minimally invasive surgery. *J Periodontol* 2000;71:1761-6.
4. Tulkki MJ, Baisden MK, McClanahan SB. Cemental tear: a case report of a rare root fracture. *J Endod* 2006;32:1005-7.
5. Tai TF, Chiang CP, Lin CP, Lin CC, Jeng JH. Persistent endodontic lesion due to complex cementodentinal tears in a maxillary central incisor--a case report. *Oral Surg Oral Med Oral Pathol Oral Radiol Endod* 2007;103:e55-60.
6. Chou J, Rawal YB, O'Neil JR, Tatakis DN. Cementodentinal tear: a case report with 7-year follow-up. *J Periodontol* 2004;75:1708-13.
7. Lin HJ, Chan CP, Yang CY, et al. Cemental tear: clinical characteristics and its predisposing factors. *J Endod* 2011;37:611-8.
8. Ishikawa I, Oda S, Hayashi J, Arakawa S. Cervical cemental tears in older patients with adult periodontitis. Case reports. *J Periodontol* 1996;67:15-20.
9. Stewart ML, McClanahan SB. Cemental tear: a case report. *Int Endod J* 2006;39:81-6.
10. Artzi Z, Wasersprung N, Weinreb M, Steigmann M, Prasad HS, Tsesis I. Effect of guided tissue regeneration on newly formed bone and cementum in periapical tissue healing after endodontic surgery: an in vivo study in the cat. *J Endod* 2012;38:163-9.
11. Watanabe C, Watanabe Y, Miyauchi M, Fujita M, Watanabe Y. Multiple cemental tears. *Oral Surg Oral Med Oral Pathol Oral Radiol* 2012;114:365-72.
12. Muller HP. Cemental tear treated with guided tissue regeneration: a case report 3 years after initial treatment. *Quintessence Int* 1999;30:111-5.
13. Bosshardt DD, Selvig KA. Dental cementum: the dynamic tissue covering of the root. *Periodontol* 2000 1997;13:41-75.
14. Noma N, Kakigawa H, Kozono Y, Yokota M. Cementum crack formation by repeated loading in vitro. *J Periodontol* 2007;78:764-9.
15. Lin HJ, Chang SH, Chang MC, et al. Clinical fracture site, morphologic and histopathologic characteristics of cemental tear: role in endodontic lesions. *J Endod* 2012;38:1058-62.