

2

A morphometric study on stainless steel crowns of the primary first molar using a three dimensional scanner

Department of Pediatric Dentistry, Dental Research Institute, School of Dentistry,
Seoul National University

Jihyun Lee, Teo Jeon Shin, Young-Jae Kim, Jung-Wook Kim,
Ki-Taeg Jang, Sang-Hoon Lee, Chong-Chul Kim, Hong-Keun Hyun

ABSTRACT

A morphometric study on stainless steel crowns of the primary first molar using a three dimensional scanner

Department of Pediatric Dentistry, Dental Research Institute, School of Dentistry, Seoul National University
Jihyun Lee, Teo Jeon Shin, Young-Jae Kim, Jung-Wook Kim, Ki-Taeg Jang,
Sang-Hoon Lee, Chong-Chul Kim, Hong-Keun Hyun

Objectives: The aim of this study was to assess the morphologic characteristics of two types of stainless steel crowns (SSCs) for the first primary molar using a 3D scanner.

Study design: Two types of SSCs, KIDS CROWN (KC) and 3M ESPE ND-96 (ND), for the first primary molars were scanned using a 3D scanner. The mesiodistal and buccolingual diameters at the height of the contour and the cervical margin, occlusocervical diameters on the mesial, distal, buccal, and lingual aspects were measured, and the crown shape ratio, the smooth surface crown height ratio, and the cervical convergence were calculated.

Results: In the crown shape ratio of the mandibular SSC, KC was larger buccolingually compared with ND. In the smooth surface crown height ratio, ND was larger than KC in all of the maxilla and mesial, distal, and lingual aspects of the mandible. ND was more convergent to the cervical mesiodistally and buccolingually compared with KC.

Conclusion: In the superimposed images of the maxillary SSC, the mesiolingual and distolingual line angles of KC were more prominent compared with ND. In the mandible, ND demonstrated higher cusps and more obvious buccal developmental lobes than KC. ND showed a larger cervical undercut than KC.

Key words : stainless steel crown, primary first molar, three dimensional scanner, crown morphometry

Corresponding Author

Hong-Keun Hyun, DDS, MSD, PhD

Associate Professor

Department of Pediatric Dentistry, School of Dentistry, Seoul National University

101, Daehakno, Jongno-gu, Seoul 03080, Republic of Korea

Telephone : +82-2-2072-0112, FAX : +82-2-744-3599

E-mail : hege1@snu.ac.kr

I . INTRODUCTION

The stainless steel crown(SSC), which consists of a nickel-chrome alloy, was first introduced by Humphrey in 1950¹⁾ and is now widely used for the restoration of grossly decayed primary or early permanent teeth in pediatric dentistry. There are two commonly used types of SSCs: 1) pre-trimmed type, which has non-contoured sides but is festooned to follow a line parallel to the gingival crest; and 2) pre-contoured type, which reproduces a cervical contour similar to that of natural teeth and is also festooned²⁾. Pre-contoured SSCs are widely used because they are easy to manipulate and adapt, e.g., the 3M ESPE Stainless Steel Primary Molar Crown ND-96 (3M ESPE, St. Paul, MN, USA) and the KIDS CROWN (Shinhung, Seoul, Korea).

The maxillary primary first molar is morphologically the average between the primary anterior teeth and the primary second molar and is designed to act as an assistant to the primary second molar. In the occlusal view, the contour of the crown is composed of four cusps and a quadrilateral that narrows towards the lingual and distal sides. Some teeth have a non-obvious small and round distolingual cusp, while the mesiobuccal and mesiolingual cusps are well-developed^{3,4)}. The mandibular primary first molar has two buccal cusps, and the mesial cusp is larger than the distal cusp. The mesiolingual cusp is long, with a sharp cusp tip, and it is separated from the round, well-developed distolingual cusp by a developmental groove. The cervical ridge is well-developed in the mesial side of the buccal

surface, providing retention to the restoration of the SSC by its undercut⁵⁾.

Because the primary first molar has a large range of variation and presents a relatively large difference in the size of the SSC, selecting a proper crown is difficult^{6,7)}.

Therefore, an understanding of the morphologic characteristics of a SSC and the natural teeth of the patient is required to shorten the chair time and fit the margin of the SSC. Studies on the morphology and size of the primary teeth or SSC have not been actively pursued so far, and the existing studies on the morphology of teeth were primarily performed by measurements using a caliper^{8,9)}.

Alternative methods of measurement to the use of a caliper have been suggested. One method is to measure the image after taking a photograph, and another is using three dimensional(3D) computed tomography. The former method is two dimensional, which can lead to differences in the measurements determined by the direction of the photograph, while the latter one requires radiation exposure.

Lately, 3D scanners have been introduced to dentistry, and they are now widely used to determine pre-operative and post-operative changes in orthodontics or oral maxillofacial surgery^{10,11)}. Gradually, the use of 3D scanners is increasing and is now beginning to be used in the morphologic study of teeth^{12,13)}. After scanning the object from every angle, we can measure the distance, angle and volume accurately by reconstructing the 3D image. In comparison with CT, 3D scanners do not require exposure to

harmful radiation. Although 3D scanners have the disadvantage of the requirement for expensive equipment and software, once the operator becomes accustomed to the process of using the 3D scanner, we can expect to shorten the time and achieve much more accurate results upon implementing SSCs.

The aim of this study is to compare the morphologic characteristics of two types of pre-contoured SSCs for the first primary molar using a 3D scanner.

II . MATERIALS AND METHODS

1. Study model

Both KIDS CROWN(KC) and ND-96(ND) for the primary first molar have 6 sizes, ranging from No. 2 to No. 7. Assuming that the left and right SSC are equal in size and morphology, we used the maxillary and mandibular primary first molar on the right side. We measured 3 models with different lot numbers in each size and analyzed 18 models separately.

2. Study method

We characterized each SSC using a 3D scanner (stereoSCAN^{3D} 5M, Breuckmann, Meersburg, Germany). In the case of scanning metal, the scanner did not perceive it well. To improve the 3D scanning measurement, a pre-treatment involving a specialized spray to coat the metal surface was applied. The thickness of the coating

was 15 μm , as suggested by the manufacturer, and thus, we subtracted this thickness from the measurement results of this study. After the scanning process, the image was reconstructed in the scanner.

The measurements on each SSC were performed using a program called Rapid form2004(INUS Technologies Inc., Seoul, Korea). We measured the mesiodistal and buccolingual diameters at the heights of the contour and the cervical margin and the occlusocervical diameters at the mesial, distal, buccal, and lingual surfaces. For accuracy and reproduction, it was important to set the reference plane on the occlusal surface. The plane that is parallel to the imaginary line connecting the most cervical point on the mesial, distal marginal ridge and passing through the mesiobuccal and mesiolingual cusp tips of both the maxillary and mandibular primary first molar was chosen as the reference plane(Fig. 1 (a)).

The mesiodistal diameter at the height of the contour is a distance measured between a plane that passes through the height of the contour on the mesial surface and is perpendicular to the reference plane and a plane that passes through the point height of the contour on the distal surface and that is perpendicular to the reference plane. The buccolingual diameter at the height of the contour is a distance measured between two planes that pass through the buccal and lingual heights of the contour and are perpendicular to the reference plane(Fig. 1 (b)).

The diameter at the cervical margin was measured after marking the most prominent point

on the cervical margin toward the mesial, distal, buccal, and lingual aspects when viewed from underneath the SSC. As was done above, we used the method of measuring the distance between two planes that are perpendicular to the reference plane(Fig. 1 (c)).

The occlusocervical diameter is the distance from the reference plane to the reference point on the cervical margin of each surface. One of three methods can be used to set a reference point. The first method is used when the contour of the gingival margin is convex to the cervical area; in this case, the reference point is set to the farthest point from the reference plane, which includes the maxillary and mandibular buccal surfaces, the lingual surface, and the distal surface of the

mandibular ND. The second method is used when the mesial and distal surface of maxillary SSC is concave, in which case the closet point is set as the reference. Finally, for the mesial surface of the mandibular ND, the mesial and distal surface of the mandibular KC exhibits an oblique curve, making it difficult to set the longest or the shortest point; thus, the middle point of the buccolingual diameter is set as the reference point(Fig. 1 (d)).

Each measurement was repeated by one examiner three times, and the mean value was used to determine the value of the measurement.

To compare the morphology of the SSC, following parameters were calculated.

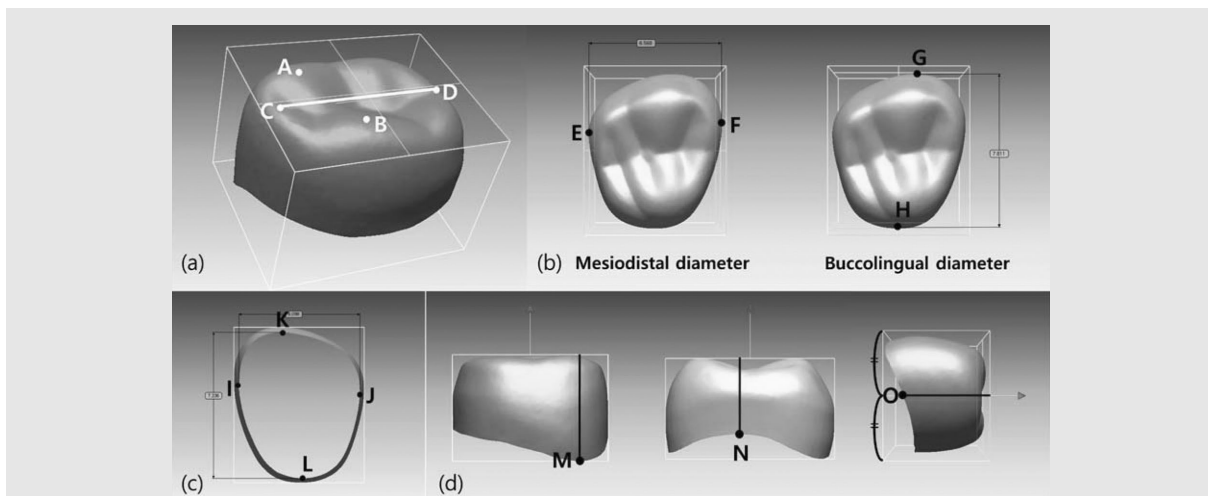


Fig. 1. (a) Setting the reference plane.

A : mesiobuccal cusp tip, B : mesiolingual cusp tip, C : the lowest point on the mesial marginal ridge, and D : the lowest point on the distal marginal ridge.

(b) Measurement of the mesiodistal and buccolingual diameters.

E : distal height of the contour, F : mesial height of the contour, G : buccal height of the contour, and H : lingual height of the contour.

(c) Bottom view for measuring the mesiodistal and buccolingual diameters at the cervical margin.

I-L : the most prominent point on the cervical margin toward the mesial (I), distal (J), buccal (K), and lingual (L) aspects.

(d) Measurement of the occlusocervical diameter.

M : the farthest point from the reference plane, N : the closest point to the reference plane, and O : the middle point of the buccolingual diameter.

1) Crown shape ratio

: buccolingual diameter at the height of the contour ÷ mesiodistal diameter at the height of the contour

2) Smooth surface crown height ratio

Mesial crown height ratio

: occlusocervical diameter at the mesial surface ÷ mesiodistal diameter at the height of the contour

Distal crown height ratio

: occlusocervical diameter at the distal surface ÷ mesiodistal diameter at the height of the contour

Buccal crown height ratio

: occlusocervical diameter at the buccal surface ÷ mesiodistal diameter at the height of the contour

Lingual crown height ratio

: occlusocervical diameter at the lingual surface ÷ mesiodistal diameter at the height of the contour

3) Cervical convergence

Mesiodistal cervical convergence

: mesiodistal diameter at the height of the contour ÷ mesiodistal diameter at the cervical margin

Buccolingual cervical convergence

: buccolingual diameter at the height of the contour ÷ buccolingual diameter at the cervical margin

In addition, we superimposed the SSCs of the same number using the software Rapidform2004 to visualize and analyze the measurements.

PASW® Statistics 18(SPSS Inc., Chicago, IL,

USA) was used for statistical analysis. An independent samples t-test with a 95% confidence interval was used to estimate the significant differences between the two products studied.

III. RESULTS

1. Intraexaminer Reliability

We used the intraclass correlation coefficient (ICC) to verify the reproducibility of the thrice-repeated measurement of each item of the SSC. The ICC value that represents the reliability between examiners was 0.996-1.000($P < .001$), indicating excellent agreement among the study results.

2. Size of the SSC

In Tables 1 and 2, the two products are listed in the order of size.

3. Crown Shape Ratio

The mean Crown Shape Ratio(SD) of the maxillary primary first molar is 1.184(0.004) for ND and 1.178(0.015) for KC, i.e., ND exhibits a higher value, but is not significantly different from KC. However, for the mandibular teeth, KC (0.836(0.007)) exhibits a value significantly greater than that of ND (0.827(0.009)) ($P < .05$) (Fig. 2 (a)-(b)).

Table 1. Arrangements of maxillary stainless steel crowns by the mean measurement values.

M-D (No.)		6.6	6.8	7.0	7.2	7.4	7.6	7.8	8.0	8.2	8.4(mm)			
	KC	2			3	4	5	6			7			
	ND	2		3	4	5	6			7				
B-L (No.)		7.6	7.8	8.0	8.2	8.4	8.6	8.8	9.0	9.2	9.4	9.6	9.8	10.0(mm)
	KC	2		3			4	5	6					7
	ND	2		3	4	5	6			7				
Mesial O-C (No.)		3.4	3.6	3.8	4.0	4.2	4.4	4.6	4.8	5.0(mm)				
	KC	2		4	5	3	6	7						
	ND			2	5	4	3	6	7					
Distal O-C (No.)		3.6	3.8	4.0	4.2	4.4	4.6	4.8	5.0(mm)					
	KC	2		4	3	5	6	7						
	ND			2	3	4	5	6	7					
Buccal O-C (No.)		4.4	4.6	4.8	5.0	5.2	5.4	5.6	5.8(mm)					
	KC	2	3		4	5		6	7					
	ND	2		3	4	5		6	7					
Lingual O-C (No.)		4.2	4.4	4.6	4.8	5.0	5.2	5.4	5.6(mm)					
	KC	2		4			5	6	3	7				
	ND			2	5	3	4		6					7
Cervical M-D (No.)		6.0	6.2	6.4	6.6	6.8	7.0	7.2	7.4	7.6	7.8	8.0(mm)		
	KC	2			3	4	5		6					7
	ND	2		3	4	5		6	7					
Cervical B-L (No.)		7.2	7.4	7.6	7.8	8.0	8.2	8.4	8.6	8.8	9.0	9.2	9.4	9.6(mm)
	KC	2			3			4	5	6				7
	ND	2		3	4	5		6	7					

KC : KIDS CROWN

ND : 3M ESPE Stainless Steel Primary Molar Crown ND-96

M-D : mesiodistal diameter

B-L : buccolingual diameter

O-C : occlusocervical diameter

Table 2. Arrangements of mandibular stainless steel crowns by the mean measurement values.

		7.4	7.6	7.8	8.0	8.2	8.4	8.6	8.8	9.0	9.2	9.4	9.6	9.8(mm)
M-D (No.)	KC	2			3		4		5		6		7	
	ND		2		3		4		5		6		7	
B-L (No.)	KC	2			3		4		5		6		7	
	ND		2	3		4		5		6		7		
Mesial (No.)	KC	42			3				65					7
	ND				3	2			4	5		6		7
Distal (No.)	KC	2	4	3				5		6		7		
	ND		2		3		4		5		6		7	
Buccal (No.)	KC	42		3				5		6			7	
	ND		32			4		5		6			7	
Lingual (No.)	KC	2	4	3			5	6					7	
	ND		2	3		4			5		6		7	
Cervical (No.)	KC	2			3		4		5		6		7	
	ND		2		3		4		5		6		7	
Cervical (No.)	KC	2			3		4		5		6		7	
	ND		2		3		4		5		6		7	

KC : KIDS CROWN
 ND : 3M ESPE Stainless Steel Primary Molar Crown ND-96
 M-D : mesiodistal diameter
 B-L : buccolingual diameter
 O-C : occlusocervical diameter

4. Smooth Surface Crown Height Ratio

In maxillary samples, ND exhibited a higher value than that of KC on four surfaces(mesial,

distal, buccal, and lingual surface) and significant differences were exhibited(P < .05) (Fig. 3 (a)-(d)). Meanwhile, in mandibular samples, the mesial, distal, and lingual surfaces

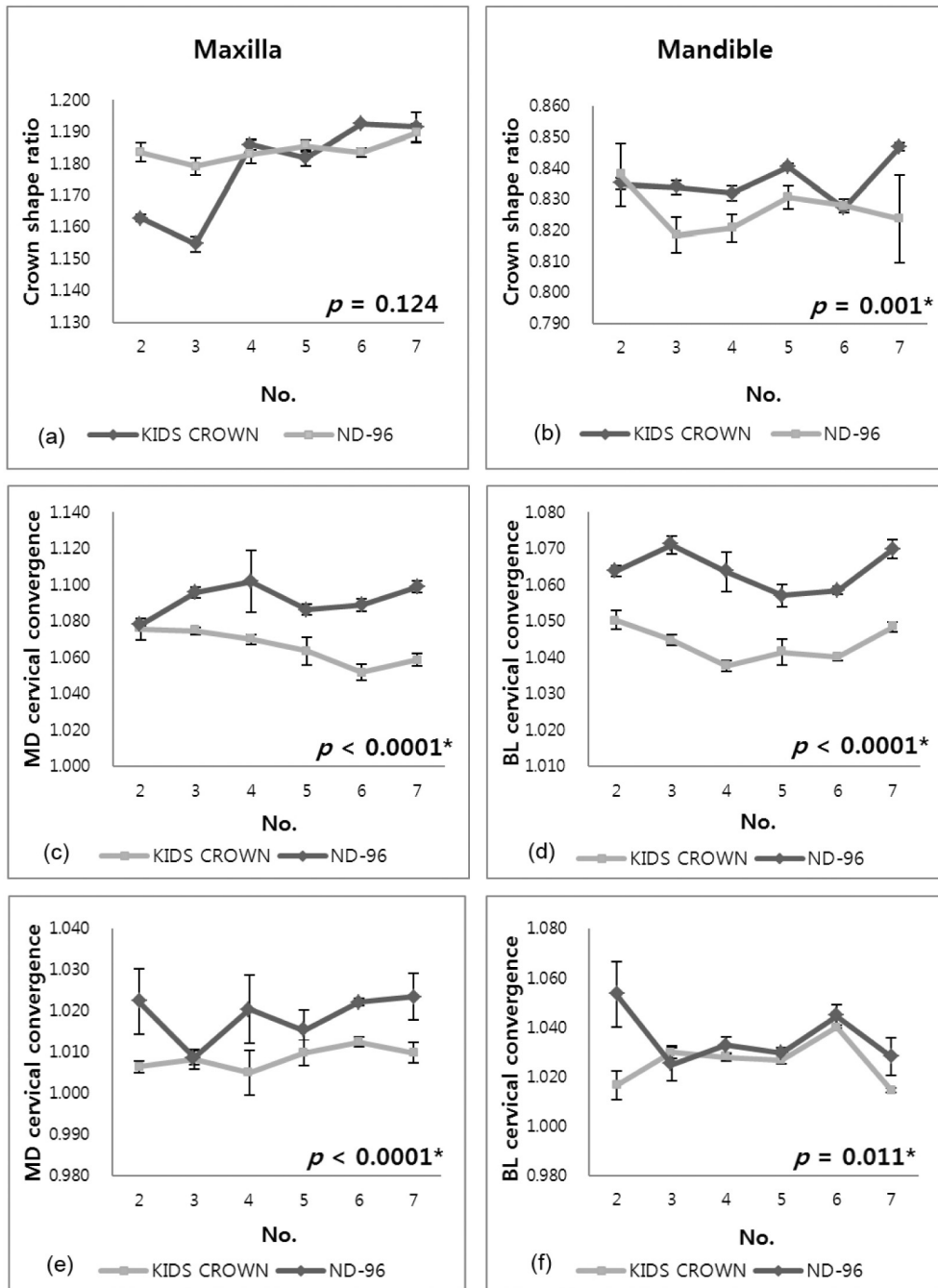


Fig. 2. Crown shape ratios of the stainless steel crowns for the maxillary (a) and mandibular (b) primary first molar. Cervical convergences of the maxillary (c)-(d) and mandibular (e)-(f) stainless steel crowns.

* statistically significant ($P < .05$)

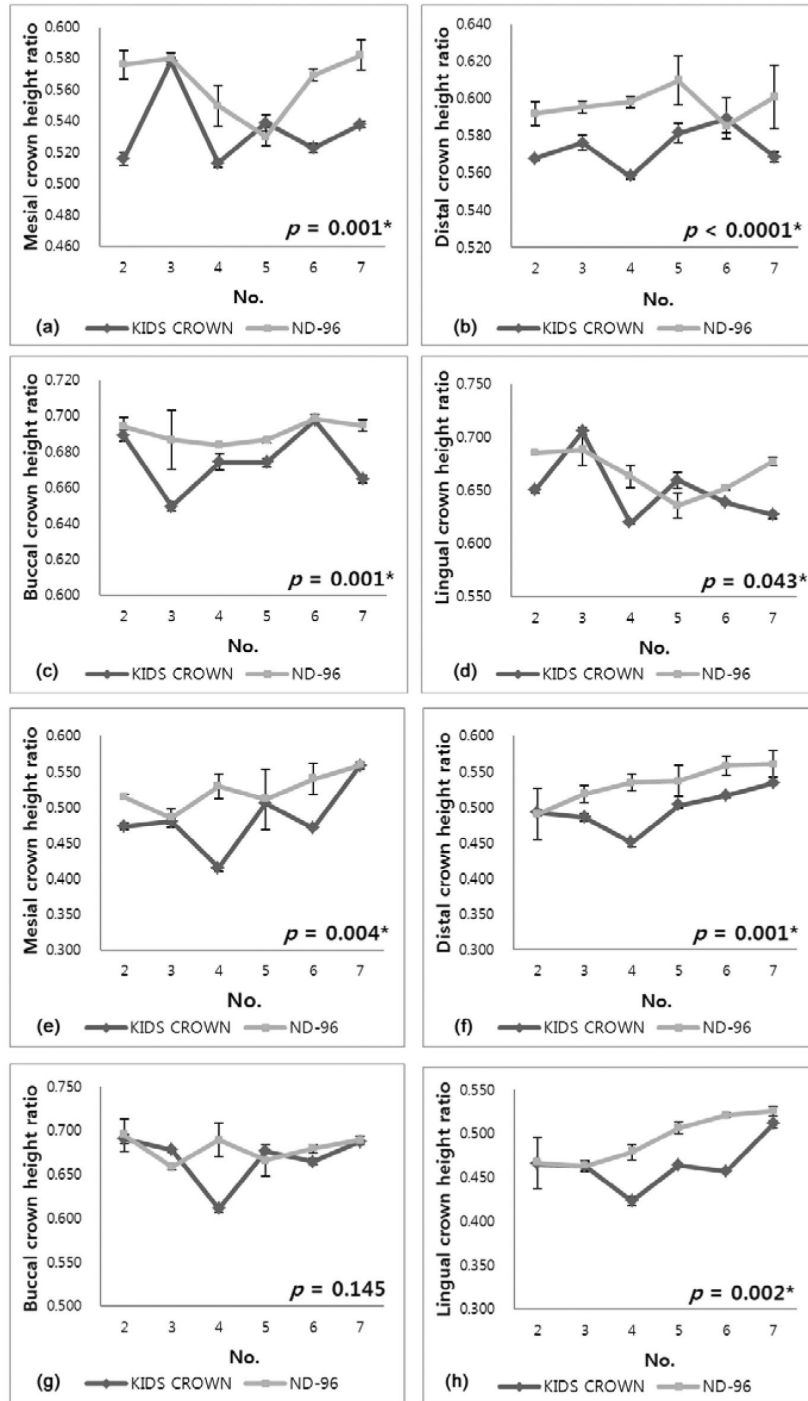


Fig. 3. Smooth surface crown height ratios of the maxillary (a)-(d) and mandibular (e)-(h) stainless steel crowns.
* statistically significant (P < .05)

of ND were significantly larger than those of KC. ND exhibited a larger crown height ratio on the buccal surface, but it was not statistically significant ($P > .05$) (Fig. 3 (e)-(h)).

5. Cervical Convergences

The cervical convergences of the mesiodistal and buccolingual were significantly larger in ND than in KC for both maxilla and mandible samples ($P < .05$), i.e., the morphology of ND is narrower on the cervical side compared to KC (Fig. 2 (c)-(f)).

6. Three Dimensional Comparison of SSCs

We compared the images of SSCs with the same number by 3D superimposition when viewed from the occlusal surface, underneath the SSC, and from the mesial, distal, buccal, and lingual aspects. (Figs. 4 and 5). When overlapping two SSCs completely, the significantly protruded side is shown in the same color as that of the SSC. From four smooth surface images, the black color of ND is elongated to the cervical because ND exhibited a larger smooth surface crown height ratio than KC, with the intensity of

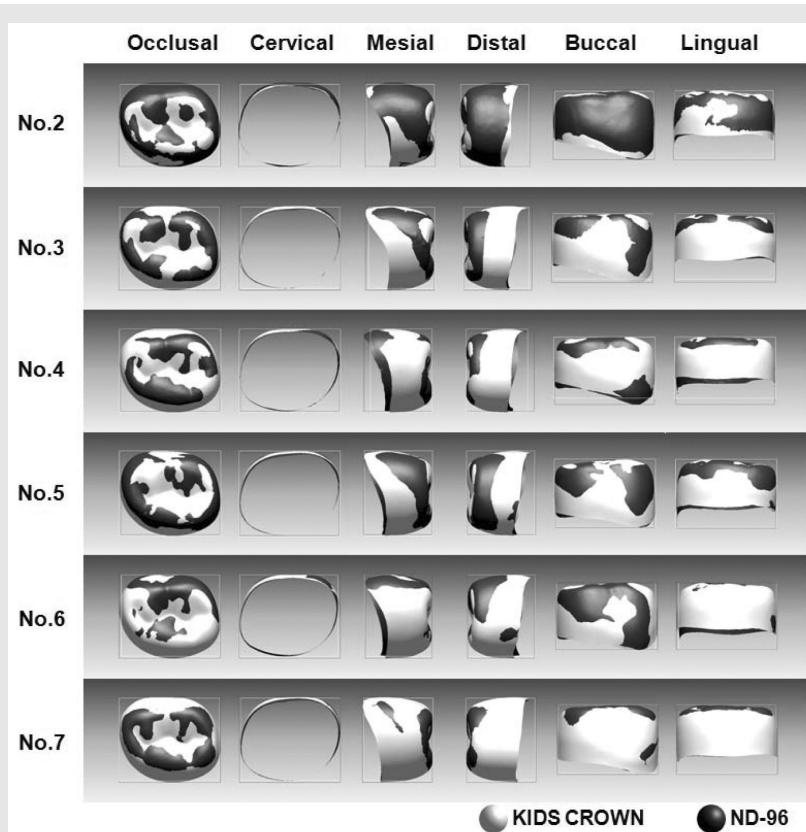


Fig. 4. Three dimensional superimposition of the maxillary stainless steel crowns with the same number.

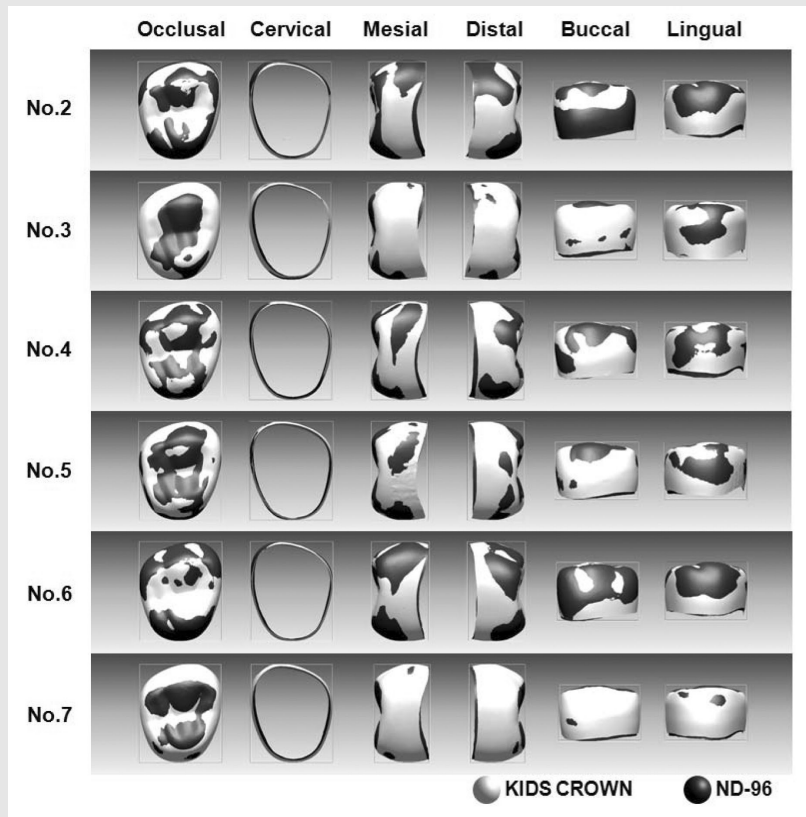


Fig. 5. Three dimensional superimposition of the mandibular stainless steel crowns with the same number.

the white color of KC increasing for regions closer to the cervical area because KC has a lower cervical convergence than ND. Additionally, from the maxillary proximal and lingual image, the color white is seen on the mesiolingual and distolingual line angles of KC; therefore, we can confirm that it is more prominent than ND. From the mandibular occlusal planar image, the mesiobuccal, distobuccal, and mesiolingual cusp tips are shown in black color for ND, and the central groove is shown in white color for KC, and thus, we could determine that the cusp of ND is higher

than that of KC(Fig. 5). In addition, from the buccal image, ND exhibited more obvious mesiobuccal and distobuccal developmental lobes than those of KC.

IV. DISCUSSION

Using a 3D scanner with a computer has the advantage of measuring not only the distance between two points after setting the imaginary line of plane but also the distance or angle between the points, lines, or planes; in addition,

the length of a curve can be determined, and all the distances are easily calculated. This capability enables the magnification of small objects on the screen, so that any irregular and small subjects can be examined well in 3D images.

In particular, we used a stereoSCAN^{3D} 5M system in this study, which has a 0.98-sec shooting speed with 7- μ m accuracy. The shooting speed of the system is over twice as fast as the ones performed previously^{12, 13}. In addition, without the requirement of additional hardware or software, the system integrates and recomposes the scanned image immediately and exhibits it on the Rapidform2004 platform.

The mandibular primary first molar has been reported to exhibit various morphologies: rhomboid, ovoid, or rectangular types^{14, 15}. Tsai studied the mandibular primary first molar from 144 Taiwanese children and classified 12 types¹⁶; Type I and Type II according to the tangent lines of the buccal and lingual surfaces, and A to F according to the alignment of the cusps. As a result, Type I-C, which has four cusps, with distobuccal convergence of the mesiolingual cusp and contour without the prominence of the distolingual surface, exhibited a high ratio of 60% of the total. In a study, Type I-C exhibited a similar result(58%), and KC and ND, both used in this study, were Type I-C, so that we can determine that these two products represent the shape of a typical tooth well¹³. Type II exhibits prominence of the distolingual surface, which has a relatively long buccolingual diameter as compared to the mesiodistal diameter. Therefore,

the opposite maxillary primary first molar SSC can be well adapted.

To objectively evaluate the size and shape of the crown, Axelsson and Kirveskari¹⁷) and Baek et al.¹⁸) used the crown index(a value that is determined by multiplying by 100 the quotient of the buccolingual diameter and the mesiodistal diameter), the crown module(half of the sum of the mesiodistal and buccolingual diameters) and the crown area(the mesiodistal diameter multiplied by the buccolingual diameter).

However, even when the crown module and crown area have the same value, the problem that objects with the same value have very different shapes in many cases still remains. Therefore, in this study, we chose Tsai's method⁶), using the crown index, to compare the occlusal morphology of the two products and calculated the crown shape ratio. As a result, in the mandible, KC exhibited a longer buccolingual diameter as compared to the mesiodistal diameter than did ND. According to Axelsson and Kirveskari¹⁷), who studied Icelandic children, the maxillary primary first molar crown shape ratio was 1.238 and the mandibular crown shape ratio was 0.923, indicating that both maxillary and mandibular teeth have long shapes compared to the conventional SSC. In Baek et al.'s study¹⁸), a similar result of 1.22 was observed for the maxillary crown shape ratio, and the mandibular crown shape ratio was observed to be 0.97. The difference between natural teeth and the SSC was noticeable in the mandibular primary first molar. This behavior can be explained by recognizing that it is the mean value(including Type II from

Tsai's study¹⁶⁾ that has a long buccolingual diameter. However, SSCs having the same crown shape ratio do not imply that they have exactly the same morphology; this is especially true for the natural maxillary primary first molar, which has a more prominent mesiolingual and distolingual line angle area than the SSC, which indicates the inadequacy of the crown shape ratio in explaining these differences. In this study, from the superimposed 3D image, we could visually compare that the lingual angle area of KC is somewhat more convex than that of ND.

In both the maxilla and mandible, ND exhibited a higher smooth surface crown height ratio than KC. It would be effective to use KC for teeth with short crown heights because we can omit cutting out the margin of the SSC. When the clinical crown is long, or if there are cervical cavities, with deep cavities on the area proximal to the cervical area, selecting ND for restoration is advantageous.

In particular, the proximal side of the primary teeth is susceptible to cavities. According to Ferro et al.¹⁹⁾ proximal cavities are the second most common, next to pit and fissure cavities, and among them, the distal surface of the primary first molar is where cavities appear most frequently. Vanobbergen et al.²⁰⁾ reported that the rate of proximal cavities increases with the age and that the distal surface of the primary first molar becomes much more susceptible to cavities than the occlusal surface. A proximal cavity is a common indication for the use of a SSC. When the SSC does not fully cover the gingival wall of the proximal cavity, marginal microleakage can

occur, leading to failure²¹⁾. Comparing the distal crown height ratio of the two products used in this study, ND exhibited a significantly higher ratio than KC, and in the mandible, ND exhibited a distal margin convex to the cervical area, while KC was rather close to the straight line. This type of morphologic difference can be seen in the distal image on Fig. 4. The optimization of the shape or length of the SSC to successful treatment still requires further study.

Cervical convergence is the value used to assess the amount of undercut below the height of the contour, and in both the mesiodistal and buccolingual sides, ND exhibited a larger value for cervical convergence than KC. An undercut in the buccolingual side is crucial for the retention of the SSC; if the undercut is large in the mesial or distal area, it could reduce the marginal leakage of the teeth with a proximal carious lesion. In addition, when a canine or second premolar erupts, the risk that the primary first molar is impacted under the SSC will be reduced. However, when the cervical convergence is large, a large amount of preparation is required for the teeth to adapt to the SSC.

The mesiodistal diameter and the buccolingual diameter exhibited a large difference between No. 2 and No. 3 and between No. 6 and No. 7. However, for ND, as the tooth number increases, the rate of increase in the difference in diameters is relatively constant. The entire range of the mesiodistal and buccolingual diameters from tooth No. 2 to No. 7 was generally larger in KC. Assuming there is no difference in the physical

properties of the two products, using the two products together for clinical use will be effective by enabling selection among a wider range of choices to ensure the proper choice of SSC.

The mesiodistal and buccolingual diameters of the two products increase as the tooth number increases, while the occlusocervical diameter exhibits a low value in large teeth numbered SSC in some cases. Remarkably, these characteristics were observed on the maxillary mesial and lingual and the mandibular mesial side; in KC No. 4, the values of the mandibular mesial, distal, buccal, and lingual surfaces, as well as in every side except for the buccal side on maxilla, were lower than No. 3. No. 4 is often used in clinical practice, and thus, we should consider this characteristic when reducing the occlusal surface or adapting the SSC.

In this study, the difference between the two SSC sizes and shapes was studied, but the information obtained on comparing the SSCs to natural teeth was limited. Axelsson and Kirveskari¹⁷⁾, who studied Icelandic children, showed that the mean mesiodistal diameter(SD) of the primary maxillary and mandibular first molar was 7.11(0.45) and 7.90(0.46) mm, which may correspond to KC No. 3, ND No. 3 for both the maxillary and mandibular SSC selections based on our study. Further work is underway to clarify the statistical differences between the SSC and the primary first molar based on the

same standards. Also, we must still analyze the size and shape of the second primary molar and those of the SSC. Moreover, a study on the elasticity or strength of the SSC should be performed.

This study is expected to provide a guideline for the selection of the various sizes and shapes of SSCs for addressing the remaining crown or teeth variation and for reducing the abutment tooth to decrease the difference with the SSC.

V. CONCLUSIONS

1. In the superimposed images of the maxillary SSC, the mesiolingual and distolingual line angles of KC were more prominent compared with ND.
2. In the mandible, ND demonstrated higher cusps and more obvious buccal developmental lobes than KC.
3. KC showed a smaller cervical undercut than ND, which may require less reduction of the axial surfaces in tooth preparation.

VI. ACKNOWLEDGEMENTS

This study was supported by the grant #04-2012-0067 from the SNUDH research fund. The authors disclose no conflicts of interest.

참고 문헌

1. Humphrey WP. Use of chrome steel in children's dentistry. *Dental Survey* 1950;26: 945-949.
2. Pinkham JR, Casamassimo PS, Fields HW, McTigue DJ, Nowak A. *Pediatric dentistry: Infancy through adolescence*. 4th ed. WB Saunders Co., Philadelphia; 357, 2005.
3. Cha MH, Kim JT, Son DS. *Dental anatomy of deciduous teeth*. Iwoo Moonhwasa, Seoul, Korea; 56-70, 1999.
4. Dean JA, Avery DR, McDonald RE. *Dentistry for the child and adolescent*. 9th ed. Mosby, St. Louis; 44, 2011.
5. Korean Academy of Pediatric Dentistry. *Pediatric Dentistry*. 4th ed. Shinhung International, Seoul, Korea; 68-70, 2007.
6. Tsai HH. Morphological characteristics of the deciduous teeth. *J Clin Pediatr Dent* 2001;25:95-101.
7. Choi JE, Cheong TS, Kim S. A morphometric study on the primary molars and preformed stainless steel crown. *J Korean Acad Pediatr Dent* 2001;28:355-362.
8. Moorrees CF, Thomsen SO, Jensen E, Kai-Jen Yen P. Mesiodistal crown diameters of the deciduous and permanent teeth in individuals. *J Dent Res* 1957;36:39-47.
9. Vela E, Taylor RW, Campbell PM, Buschang PH. Differences in craniofacial and dental characteristics of adolescent Mexican Americans and European Americans. *Am J Orthod Dentofacial Orthop* 2011;140:839-847.
10. Kook YA, Bayome M, Park SB, Cha BK, Lee YW, Baek SH. Overjet at the anterior and posterior segments: Three-dimensional analysis of arch coordination. *Angle Orthod* 2009;79:495-501.
11. Jung YJ, Kim MJ, Baek SH. Hard and soft tissue changes after correction of mandibular prognathism and facial asymmetry by mandibular setback surgery: Three-dimensional analysis using computerized tomography. *Oral Surg Oral Med Oral Pathol Oral Radiol Endod* 2009;107:763-771.
12. Lee JB, Kim CC, Han SH, Lee SH. A morphometric study of the maxillary primary first molars using three-dimensional scanner. *J Korean Acad Pediatr Dent* 2006;33:643-652.
13. Shin YK. A morphometric study of the mandibular primary first molars using three-dimensional scanner. Dissertation, Seoul National University, 2008.
14. Fuller JL, Denehy GE. *Concise dental anatomy and morphology*. 2nd ed. Mosby Year Book, Chicago; 241-244, 1984.
15. Brand RW, Isselhard DE. *Anatomy of orofacial structures*. 6th ed. Mosby, St. Louis; 481-483, 1998.
16. Tsai HH. Descriptive classification of variations in primary mandibular first molars. *ASDC J Dent Child* 2001;68:23-26.
17. Axelsson G, Kirveskari P. Crown size of deciduous teeth in Icelanders. *Acta Odontol Scand* 1984;42:339-343.
18. Baek BJ, Jeon SH, Kim JG, Kim YS. A study on the size of the deciduous teeth. *J Korean Acad Pediatr Dent* 2002;29:382-387.
19. Ferro R, Besostri A, Olivieri A. Caries prevalence and tooth surface distribution in a group of 5-year-old Italian children. *Eur Arch Paediatr Dent* 2009;10:33-37.
20. Vanobbergen J, Lesaffre E, Garcia-Zattera MJ, Jara A, Martens L, Declerck D. Caries patterns in primary dentition in 3-, 5- and 7-year-old children: spatial correlation and preventive consequences. *Caries Res* 2007;41:16-25.
21. Guelmann M, Bookmyer KL, Villalta P, Garcia-Godoy F. Microleakage of restorative techniques for pulpotomized primary molars. *J Dent Child (Chic)* 2004;71:209-211.