

## Improvement of fibrosed scar tissue elongation using self-inflatable expander

<sup>1</sup>Department of Periodontology, Korea University Anam Hospital

<sup>2</sup>Department of Oral and Maxillofacial Surgery, Ewha Womans University Medical Center

<sup>3</sup>Department of Periodontology, Ewha Womans University Medical Center

Gyu-Un Jung<sup>1</sup>), Jin-Woo Kim<sup>2</sup>), Eun-Kyoung Pang<sup>3</sup>), Sun-Jong Kim<sup>2</sup>)\*

### ABSTRACT

#### Improvement of fibrosed scar tissue elongation using self-inflatable expander

<sup>1</sup>Department of Periodontology, Korea University Anam Hospital, Seoul, Korea

<sup>2</sup>Department of Oral and Maxillofacial Surgery, Ewha Womans University Medical Center, Seoul, Korea

<sup>3</sup>Department of Periodontology, Ewha Womans University Medical Center, Seoul, Korea

Gyu-Un Jung<sup>1</sup>), Jin-Woo Kim<sup>2</sup>), Eun-Kyoung Pang<sup>3</sup>), Sun-Jong Kim<sup>2</sup>)\*

We evaluated a self-inflatable osmotic tissue expander for its utility in creating sufficient soft tissue elongation for primary closure after bone grafting. Six patients with alveolar defects who required vertical augmentation of >6 mm before implant placement were enrolled. All had more than three prior surgeries, and flap advancement for primary coverage was restricted by severely fibrosed scars. Expanders were inserted beneath the flap and fixed with a screw. After 4 weeks, expander removal and bone grafting were performed simultaneously. A vertical block autograft and guided bone regeneration and distraction osteogenesis were performed. Expansion was sufficient to cover the grafted area without additional periosteal incision. Complications included mucosal perforation and displacement of the expander. All augmentation procedures healed uneventfully and the osseous implants were successfully placed. The tissue expander may facilitate primary closure by increasing soft tissue volume. In our experience, this device is effective, rapid, and minimally invasive, especially in fibrous scar tissue.

Key words : Alveolar bone regeneration, primary coverage, tissue expander

Corresponding Author

Prof. Sun-Jong Kim

Department of Oral and Maxillofacial Surgery,

Ewha Womans University Medical Center, 1071, Anyangcheon-ro, Yangcheon-Gu, Seoul, 07985, Korea

Tel : +82-2-2650-5631, Fax : +82-2-2650-5764, E-mail : oralsurgeonsj@gmail.com

## I . Introduction

Severe alveolar defects may occur as a result of extractions, trauma, cysts, and congenital abnormalities. Occasionally, dental surgeons encounter a situation where a significantly atrophic ridge must be reconstructed before placement of endosseous implants. To overcome this limitation, various bone reconstruction techniques such as block grafts, particulate grafts, ridge expansion techniques, guided bone regeneration(GBR), and distraction osteogenesis have been reported<sup>1-4</sup>. Successful outcomes depend on the osteogenic potential of the graft material, graft stabilization, and primary soft tissue closure<sup>5</sup>. In particular, primary soft tissue coverage during the healing phase is essential to achieve a successful bone graft; however, as the volume of graft materials increases, so does the difficulty of the primary coverage.

The first step in achieving primary closure is adequate flap release, which is necessary to undermine and coronally displace the mucoperiosteal flap. The periosteal releasing incision is a prerequisite in sites of massive bone grafts because of inadequate tissue length for tension-free coverage. The periosteum is inelastic and composed of dense and fibrous connective tissue; thus, the amount of flap displacement is restricted in the absence of a releasing incision. If an excessive amount of material is grafted in a severely atrophic alveolar ridge, it is difficult to achieve sufficient flap advancement length from a shallow periosteal incision. However, excessive flap advancement

from a deep periosteal releasing incision impairs healing of the periosteum and leads to insufficient vascularity and bone formation capacity in the periosteum. In addition, excessive flap advancement can lead to a loss in vestibular height and displacement of the mucogingival junction. In larger deficiencies, it is difficult to achieve bone grafting and soft tissue coverage simultaneously; thus, soft tissue must be managed prior to bone grafting to increase the success rate of ridge augmentation procedures. However, soft tissue management at previous surgical sites is difficult because the scar tissue becomes extremely stiff and inelastic. The traumatized periosteum also has a diminished bone formation capacity. In this situation, additional surgical procedures should be avoided, because as the vitality of the periosteum and mucoperiosteal flap further reduces, the risk of failure increases.

In an effort to overcome these limitations, self-inflatable tissue expanders have been developed to increase tissue volume<sup>6,7</sup> and have been widely applied in extraoral surgery<sup>8,9</sup>. The expander is self-inflatable silicone elastomer which varies in shape and size to match diverse range of clinical situations. Its main purpose is to increase the amount of soft tissue by inflating the expander underneath the soft tissue at the recipient site. The round or elliptical expander were implanted in the sub-cutaneous or sub-muscular area and maintained for a period of expansion, then removed after desired expansion. This devices expedite additional tissue expansion or elongation adjacent tissue in the recipient site

before ridge augmentation surgery and the obtained tissue showed harmonious color and texture with original tissue. Increasing soft tissue volume facilitates primary soft tissue closure even in large bone grafting sites such as vertical bone augmentation. It may also reduce the need for periosteal incision and displacement of a mucoperiosteal flap from its original position. A self-inflating tissue expander increases in size through the absorption of body fluids. It consists of an osmotic active hydrogel, a methyl methacrylate core, and a perforated N-vinyl pyrrolidone shell<sup>10</sup>. The ability of tissues to respond to progressive stretching has been widely studied in plastic surgery<sup>9,11</sup>. However, studies of osmotic soft tissue expanders in intraoral defects are relatively rare and few human studies have been performed; thus, we have a limited understanding of the intraoral application of tissue expanders, especially in the case of previously traumatized scar tissue.

This case series describes the use of a self-inflatable osmotic tissue expander to increase soft tissue volume and achieve primary soft tissue coverage after vertical ridge augmentation in cases with severely fibrosed scar tissue or previously traumatized tissue. The effectiveness of this expander with bone grafting in severely atrophic alveolar ridges was clinically assessed.

## II. Materials and Methods

### Patient selection

This study was performed at the Ewha Womans University Medical Center, Korea between September 2010 and January 2014. All patients were informed of the study's goals and risks, and provided written informed consent in advance. The inclusion criteria were severely atrophic alveolar ridges classified as Seibert Class III requiring vertical bone grafts of >6 mm before implant placement and scarred soft tissue in which extension was unattainable with conventional mucoperiosteal flap because of repeated surgical trauma including GBR failure, benign tumor excision, and implant removal<sup>12</sup>(Figs. 1, 2). The exclusion criteria were uncontrolled diabetes mellitus, use of bisphosphonate medications, smoker, and prior radiation therapy in the head and neck region.

### Expander insertion

The expander type and size were chosen by using a surgical template identical to the final volume(Fig. 3). We used self-inflatable hydrogel tissue expanders(Osmed GmbH, Illmenau, Germany), which were round-ended cylinders with final volumes of 0.24 mL and 2.1 mL. Following a mouth rinse, local anesthetics were applied to the area intended for surgery. An incision was made with a scalpel and the full-thickness mucoperiosteal flap was carefully reflected. This excision was performed 5-10 mm from the expander margin to avoid tissue perforation during the expansion period. Then, the tissue expander was inserted into the subperiosteal pouch and fixed to the bone with a

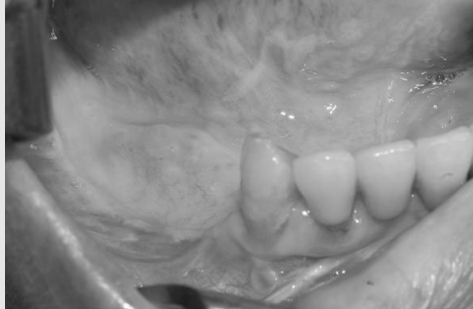

Fig 1. Edentulous mandible with advanced resorption of the alveolar process.

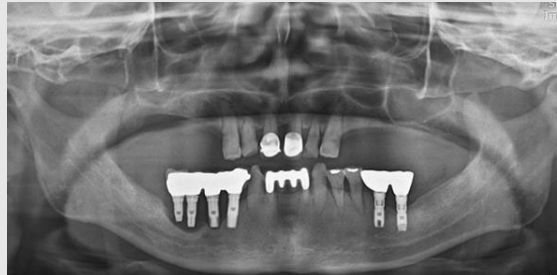

Fig 2. Radiographic evaluation of failing implants placed at the site of right posterior mandible.

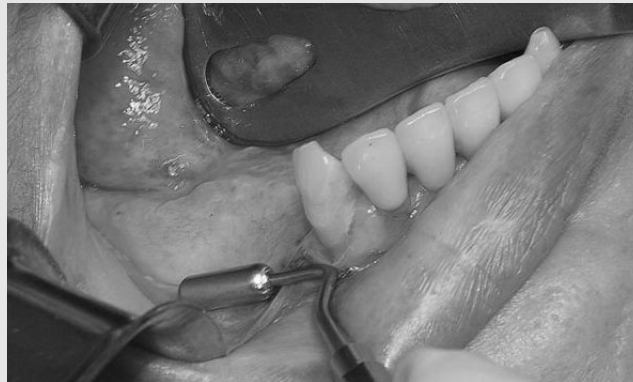

Fig 3. Measurement of the expander size using the surgical template.

titanium screw(Micro Auto Screw, Jeil Medical Corporation, Seoul, Korea)(Figs. 4, 5). Primary flap closure was performed without tension. The patients were administered antibiotics and analgesics three times a day for 7 days, with a 0.12% chlorhexidine mouth rinse.

### Expander removal and bone grafting

After 4 weeks, the patients visited the clinic for simultaneous removal of the tissue expander and the bone grafting procedure(Fig. 6). The surgical sites were anesthetized and an incision was performed through the crestal line; a

mucoperiosteal flap was raised with a lateral vertical incision. The inflated expander and titanium screw were removed(Fig. 7, 8), and the alveolar defects were exposed. To correct these hard tissue deficiencies, grafting with either an autogenous block onlay or a particulate graft with a membrane was planned before implant placement. A cortico-cancellous bone graft block of sufficient dimensions was harvested intraorally from four patients(ipsilateral ramus of the mandible) and from an extraoral site(ilic crest) in one patient with larger deficiencies. The sharp edges of the harvested bone were trimmed with a round burr to fit the recipient site and

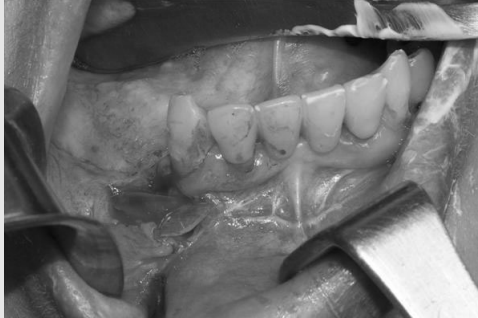

Fig 4. The subperiosteal pouch was prepared and the expander was inserted. The fibrous scar caused by previous surgical treatment was observed.

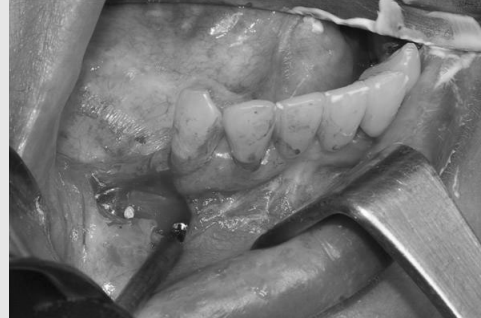

Fig 5. The expander was fixed with titanium screw.

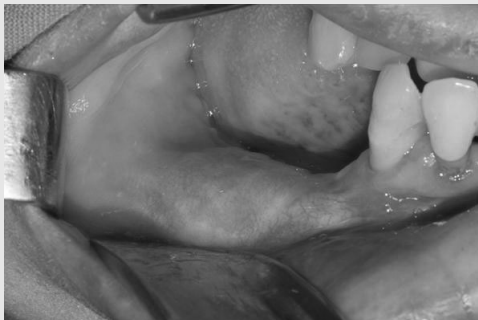

Fig 6. After 4 weeks of tissue expansion (0.7 mL expander).

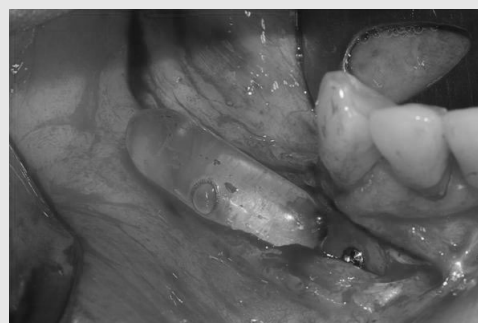

Fig 7. The tissue expander was fully expanded and removed.

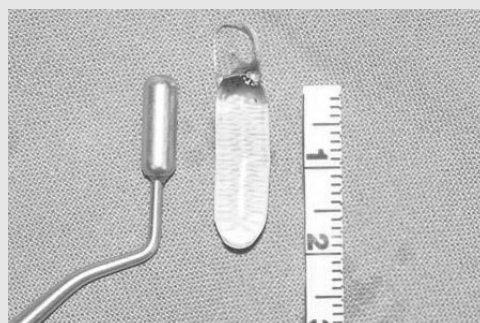


Fig 8. Removed osmotic expander after expansion (0.7 ml) compare to surgical template of initial size (0.15 ml).

avoid damage to the soft tissue of the flap. The bone blocks were fixed to the recipient sites with a titanium screw(Fig. 9, 10) and concavities around the bone block margins were filled with particulate bone chips or deproteinized bovine bone mineral(Bio-Oss®, Geistlich Biomaterials,

Wolhusen, Switzerland). A resorbable collagenous membrane(Bio-Gide®, Geistlich Pharma AG, Wolhusen, Switzerland) was trimmed to the required size and 1 mm from the adjacent teeth, and subsequently applied to cover the bone graft materials. Tension-free primary

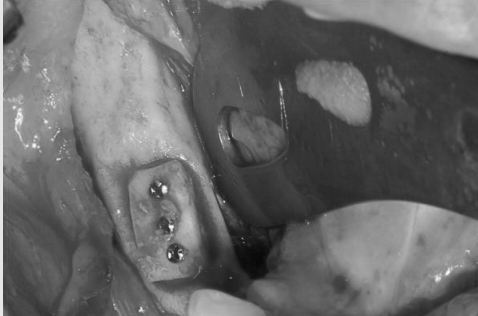

Fig 9. The atrophic ridge was reconstructed by chin bone graft.

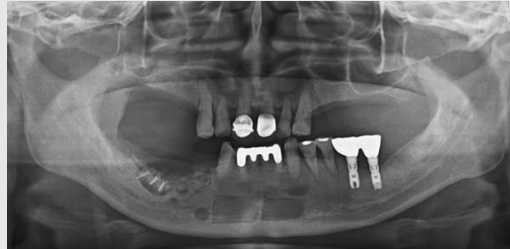

Fig 10. Radiographic evaluation after ridge augmentation by block bone graft and GBR simultaneously with removal of expander.

closure was accomplished with horizontal mattress sutures and interrupted sutures. Distraction osteogenesis was performed in one patient. Antibiotics and analgesics were prescribed as above, with a 0.12% chlorhexidine mouth wash. The sutures were removed 2 weeks after surgery, and the patients returned for follow-up visits every 2 weeks thereafter. Approximately 6 months later, re-entry surgery was performed to insert the implant(Fig. 11); the osseointegration was investigated clinically and radiographically(Fig. 12).

### III. Results

Six patients(3 men and 3 women, aged 47-63 years) underwent self-inflating osmotic tissue expander treatment in advance of vertical ridge augmentation. All patients were partially edentulous with severely atrophic deficiencies, which were classified as Seibert Class III(*i.e.*, vertical and horizontal defects)<sup>12)</sup>. Four defects were located in the posterior mandible and the alveolar ridge was resorbed to the level of the basal bone of the mandible. Two defects were located in the anterior and posterior maxillary

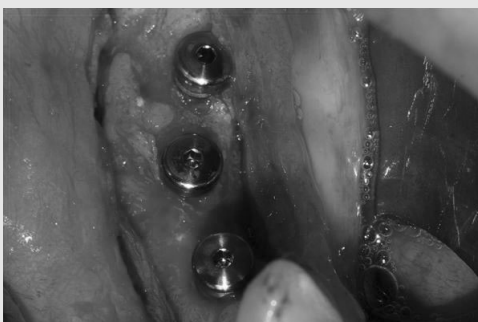

Fig 11. Three implants were placed 6 months after ridge augmentation.

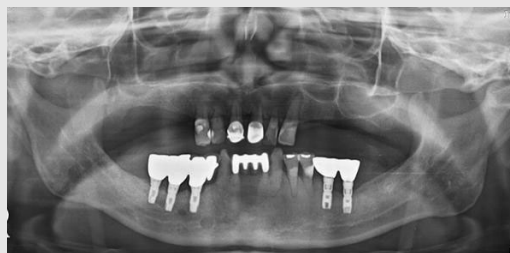

Fig 12. Radiographic evaluation after 2 years implant loading. The implant do not show any crestal bone loss.

regions. Most patients had more than three prior surgical treatments with a full-thickness flap elevation and/or periosteal releasing incision. In three patients, periimplant bone loss had progressed to the level of 1/3 of their fixture; thus, these implants were removed. In two patients, bone grafts had failed due to a benign tumor and a prior GBR failure (Table 1). All patients demonstrated loss of the alveolar process.

The self-inflating osmotic soft tissue expander allowed expansion of the alveolar mucosa and underlying periosteum in all patients. Wound healing was generally uneventful, with no signs of infection or other problematic symptoms in four patients. Complications were observed in two cases, including perforation of the mucosa and displacement of the expander. The soft tissue perforation occurred in a maxillary defect 4 weeks after the expansion. Nevertheless, no signs of infection were observed in the soft tissue. The expander was immediately removed and the wound was closed by suturing. After sufficient

healing, the defect was reconstructed by GBR, bone block grafting, and subsequent distraction osteogenesis. In another patient, a lingual displacement of the tissue expander was observed. There is a fixation screw hole on one side of the expander, but the unfixed distal part of the expander crossed the alveolar ridge; however, no perforation or inflammation was observed.

The expansion was allowed to proceed for 4 weeks in all cases, and the bone grafting procedure was performed simultaneously with the removal of the expander. In patients who healed uneventfully, the graft materials were covered without an additional periosteal releasing incision. All six patients revealed sufficient bone available to support implants after vertical ridge augmentation. Implant placement was performed at the regenerated bone. All patients were followed up for at least 3 years, and have maintained implant integrity and the health of the periimplant tissue.

Table 1. Patients characteristics and surgical records.

Age/ Sex	Recipient Site	Expansion periods	Final size (mL)	Ridge augmentation	Complications
M/52	Ant.maxilla	4 weeks	0.7	Distraction osteogenesis + GBR	Palatal tissue perforation
F/47	Rt. posterior mandible	4 weeks	0.7	Block bone graft (chin) + GBR	
F/53	Rt. posterior mandible	4 weeks	1.3	Block bone graft (ramus) + GBR	
M/56	Lt. posterior mandible	4 weeks	2.1	Block bone graft (ileum) + GBR	Expander displacement
M/63	Lt. posterior maxilla	4 weeks	1.3	Block bone graft (ramus) + GBR	
F/53	Rt. posterior mandible	4 weeks	0.24	Block bone graft (ramus) + GBR	

## IV. Discussion

Severe alveolar deficiency has long been an obstacle to implant-supported prostheses. The reconstruction of a severely atrophic ridge using techniques, such as vertical bone augmentation with block onlay bone grafting and/or GBR, produce frequent complications and low success rates due to difficulties in tension-free soft tissue closure<sup>13, 14</sup>. Primary coverage of larger augmented sites cannot be achieved with a conventional trapezoidal mucoperiosteal flap. In order to achieve a tension-free closure, the undermining of flaps and periosteal incisions at their base is necessary; the flap should be displaced and should lie passively 3-5mm beyond the original incision line<sup>15</sup>. An insufficiently released periosteum frequently cannot cover the bone graft materials and leads to bone graft failures.

However, the recipient bed was undesirable for a bone grafting procedure because of previous surgery, including scar tissue that lacked the flexibility required for tissue advancement. The increased rigidity of previously traumatized scar tissue raises the risk of exposure at the augmented site. The amount of large bone augmentation that can be simultaneously performed with implant installation is limited because of the requirement for flap closure and the compromised blood supply. Furthermore, it is unpredictable and has a much lower chance of survival over poorly vascularized areas such as a bone graft or barrier membrane. Healing of the periosteum seemed slower after blunt dissections

resulting from elevation of the mucoperiosteal flaps than it did in incisional wounds.

The application of self-inflatable osmotic tissue expanders before bone grafting procedures has been suggested to expand soft tissue and periosteum<sup>16, 17</sup>. The ability of tissue to adapt to progressive expansion has been described in breast and forearm surgery<sup>8, 9</sup>. If the expansion is rapid, it may cause mechanical tissue damage to the periosteum because the high strain and force results in aggravation to the blood supply. Therefore, they should be increased in size continuously and slowly, leading to the safe and effective growth of soft tissue<sup>18</sup>. In a previous study of a hydrogel expander in rats, tensile strength applied to the periosteum reduced vessel diameter, vessel density increased, and bone graft healing improved<sup>19</sup>. After controlled expansion of the periosteum and soft tissue, it is more likely that live periosteal progenitor cells will be in direct contact with the bone graft<sup>20</sup>. In a rabbit study, slow expansion of the periosteum with an osmotic expander resulted in new bone formation<sup>20</sup>. However, these results have not been confirmed in a clinical human study because it is not possible to analyze histologic features without collecting the expanded soft tissue and bone.

In our experience, most patients treated with a tissue expander revealed enhanced soft tissue volume sufficient to achieve primary coverage after 4 weeks. If the expanders were located in submucosal tissue without a full-thickness flap elevation, expansion of the periosteum was impossible, while creating a capsule of fibrous

connective tissue around the expander<sup>21</sup>). In another study, seroma formation was briefly observed but without negative effects on the bone grafting procedure<sup>11</sup>). In our study, we placed the tissue expander subperiosteally, expecting soft tissue and periosteum elongation. However, compression of alveolar bone by inflation of the tissue expander may lead to excessive resorption of underlying alveolar bone<sup>17, 22</sup>) or even loss of bone density<sup>23</sup>). In our experiment, resorption of underlying bone was not observed, because the final size of the expander did not exceed the soft tissue capacity and the extension power was kept under control by continuous forces. Rapid expansion triggers high compression, thereby causing hypoxia in the tissue and injury to the expanded tissue<sup>10, 24</sup>). The silicone envelope can affect the maximum amount of inflation and control the critical pressure of expansion. Therefore, the amount of increase might be limited by covering the hydrogel with a silicone envelope. After removing the fixation screw and expander, we observed capsule formation in the periosteum. While this did not cause significant problems in the augmentation procedures in our study, capsule formation following subcutaneous expansion reportedly progresses less well than that after subperiosteal expansion<sup>25</sup>). Additionally, a subcutaneous pouch is recommended, as it is easier for the clinician to create and is better tolerated than subperiosteal placement<sup>16</sup>).

Other factors to be assessed are the quantity and quality of the increased tissue. After expansion, the quantity of tissue was sufficient, permitting primary closure without periosteal

incision or flap advancement. Therefore, we observed no postoperative exposure of the bone grafts. These findings are consistent with previous case studies, which have described a favorable tissue response and adequate tissue gain<sup>16, 17</sup>). Although we did not attain new bone formation, in our experience, this device creates an optimal recipient bed in previously scarred mucoperiosteum following surgical trauma and failed bone grafting procedures. The deteriorated periosteum was not damaged by an additional periosteal incision, and we hoped that new bone regeneration would be enhanced by slowly expanding the periosteum. However, the tissue quality was not improved. Most patients had severely atrophic alveolar bone, reaching the basal bone of the maxilla and mandible, thus, causing loss of the alveolar process. An atrophic ridge is usually accompanied by decreased keratinized mucosa, and the bone is surrounded by movable alveolar mucosa without dense, keratinized gingiva. After insertion of the tissue expander in the atrophic ridge, the increased tissue was movable because it was derived from the original tissue. Therefore, the quality of the increased tissue was not a satisfactory as barrier against inflammation around the implants. Especially in mandibular defects, additional soft tissue grafting or vestibuloplasty might be necessary to ensure the longevity of dental implants. Further research and evaluations of the expansion ability of keratinized gingiva are required.

The major initial drawback of this device is tissue perforation, mostly caused by

inappropriate location(*i.e.*, too close to an incision line). Late-arising perforation results from inadequate expander volume or over-estimated soft tissue compatibility. Appropriate choice of expander size to match the existing anatomical structure is essential for the success of the tissue expansion procedure. In 2 patients in our study, complications were observed: tissue perforation in a maxillary defect and lingual displacement of the expander in a mandibular defect. Perforation was caused by failure of the soft tissue to attain the final expansion size, and fixation was obtained on one side of the expander. As alveolar resorption reached the basal bone, causing loss of the vestibule, the buccal mucosa was closely attached to the palatal mucosa, which is firm and keratinized; therefore, the expander perforated the mucosa. In other patients with mandibular defects, a lingual displacement of the tissue expander was observed. The lack of an attached gingival barrier and flattened alveolar ridge could allow for lingual displacement of the expander without soft tissue perforation. There is a fixation screw hole on one side of the expander; thus, the unfixed distal part of the expander crossed the alveolar ridge. However, the lingual mucosa was not keratinized, and the expander could be placed under the mucosa. The currently available tissue expander for oral and maxillofacial areas is fixed on one side by a screw; therefore, the unfixed part could shift in unintended directions during the expansion. Therefore, we suggest the tissue expander should have a screw hole at both ends to prevent unintended shifts.

Further studies will be needed to assess of the efficacy of this device. A standardized measurement of soft tissue change is necessary to predict the amount of soft tissue elongation. The expanded volume is not proportional to the elongated length. Various methods such as conventional radiography, computed tomography, and study casts could be used for analysis, but do not reproduce an accurate soft tissue profile. The direct measurement of increased tissue is difficult because soft tissue is mobile and the reference points change with mouth opening and buccal cheek pulling. Moreover, there is little data on histologic changes after expansion in humans; this is needed to assess inflammation, abnormal healing, or micro-bone injury during expansion. Further studies are needed to evaluate self-inflatable tissue expanders through volumetric and histologic investigation to assess the effectiveness of expanded soft tissue.

## V. Conclusions

The self-inflatable, osmotic tissue expander yielded successful soft tissue elongation for tension-free primary closure at large grafted sites. Especially in the presence of fibrous scar tissue, it could provide sufficient tissue expansion for primary coverage, significantly reduce morbidity, and may be particularly useful in severely fibrosed scar tissue or previously damaged tissue.

## 참 고 문 헌

1. Misch CM. Comparison of intraoral donor sites for onlay grafting prior to implant placement. *Int J Oral Maxillofac Implants* 1997;12:767-776.
2. Simion M, Baldoni M, Zaffe D. Jawbone enlargement using immediate implant placement associated with a split-crest technique and guided tissue regeneration. *Int J Periodontics Restorative Dent* 1992;12:462-473.
3. Hammerle CH, Karring T. Guided bone regeneration at oral implant sites. *Periodontol 2000* 1998;17:151-175.
4. Oda T, Sawaki Y, Ueda M. Experimental alveolar ridge augmentation by distraction osteogenesis using a simple device that permits secondary implant placement. *Int J Oral Maxillofac Implants* 2000;15:95-102.
5. Wang HL, Boyapati L. "PASS" principles for predictable bone regeneration. *Implant Dent* 2006;15:8-17.
6. Neumann CG. The expansion of an area of skin by progressive distention of a subcutaneous balloon; use of the method for securing skin for subtotal reconstruction of the ear. *Plast Reconstr Surg* (1946) 1957;19:124-130.
7. Lew D, Clark R, Shahbazian T. Use of a soft tissue expander in alveolar ridge augmentation: a preliminary report. *J Oral Maxillofac Surg* 1986;44:516-519.
8. Radovan C. Breast reconstruction after mastectomy using the temporary expander. *Plast Reconstr Surg* 1982;69:195-208.
9. Berge SJ, Wiese KG, von Lindern JJ, Niederhagen B, Appel T, Reich RH. Tissue expansion using osmotically active hydrogel systems for direct closure of the donor defect of the radial forearm flap. *Plast Reconstr Surg* 2001;108:1-5, discussion 6-7.
10. Uijenbroek HJ, Liu Y, He JF, Visscher C, van Waas MA, Wismeyer D. Expanding soft tissue with Osmed tissue expanders in the goat maxilla. *Clin Oral Implants Res* 2011;22:121-128.
11. Ronert MA, Hofheinz H, Manassa E, Asgarouladi H, Olbrisch RR. The beginning of a new era in tissue expansion: self-filling osmotic tissue expander--four-year clinical experience. *Plast Reconstr Surg* 2004;114:1025-1031.
12. Seibert JS. Reconstruction of deformed, partially edentulous ridges, using full thickness onlay grafts. Part II. Prosthetic/periodontal interrelationships. *Compend Contin Educ Dent* 1983;4:549-562.
13. Proussaefs P, Lozada J. The use of intraorally harvested autogenous block grafts for vertical alveolar ridge augmentation: a human study. *Int J Periodontics Restorative Dent* 2005;25:351-363.
14. Rocuzzo M, Ramieri G, Bunino M, Berrone S. Autogenous bone graft alone or associated with titanium mesh for vertical alveolar ridge augmentation: a controlled clinical trial. *Clin Oral Implants Res* 2007;18:286-294.
15. Greenstein G, Greenstein B, Cavallaro J, Elian N, Tarnow D. Flap advancement: practical techniques to attain tension-free primary closure. *J Periodontol* 2009;80:4-15.
16. Kaner D, Friedmann A. Soft tissue expansion with self-filling osmotic tissue expanders before vertical ridge augmentation: a proof of principle study. *J Clin Periodontol* 2011;38:95-101.
17. Mertens C, Thiele O, Engel M, Seeberger R, Hoffmann J, Freier K. The Use of Self-Inflating Soft Tissue Expanders Prior to Bone Augmentation of Atrophied Alveolar Ridges. *Clin Implant Dent Relat Res* 2013.
18. Anwander T, Schneider M, Gloger W, Reich RH, Appel T, Martini M, et al. Investigation of the expansion properties of osmotic expanders with and without silicone shell in animals. *Plast Reconstr Surg* 2007;120:590-595.
19. von See C, Rucker M, Bormann KH, Gellrich NC. Using a novel self-inflating hydrogel expander for intraoral gingival tissue expansion prior to bone augmentation. *Br J Oral Maxillofac Surg* 2010;48:e5-6.
20. Abrahamsson P, Isaksson S, Gordh M, Andersson G. Periosteal expansion of rabbit mandible with an

## 참 고 문 헌

- osmotic self-inflatable expander. *Scand J Plast Reconstr Surg Hand Surg* 2009;43:121-125.
21. Schwartz HC, Relle RJ. Extraoral placement of a subperiosteal tissue expander for reconstruction with hydroxylapatite of the severely atrophic mandibular alveolar ridge. *J Oral Maxillofac Surg* 1990;48:157-161.
22. van Damme PA, Freihofer HP, van't Hof MA, Kuijpers-Jagtman AM, Maltha JC, Spijkers JM. Radiologic analysis of the effects of subperiosteal palatal soft-tissue expansion in growing cats. *Int J Oral Maxillofac Surg* 1994;23:393-394.
23. Stuehmer C, Rucker M, Schumann P, Bormann KH, Harder Y, Sinikovic B, et al. Osseous alterations at the interface of hydrogel expanders and underlying bone. *J Craniomaxillofac Surg* 2009;37:258-262.
24. Wiese KG. Osmotically induced tissue expansion with hydrogels: a new dimension in tissue expansion? A preliminary report. *J Craniomaxillofac Surg* 1993;21:309-313.
25. Tominaga K, Matsuo T, Kuga Y, Mizuno A. An animal model for subperiosteal tissue expansion. *J Oral Maxillofac Surg* 1993;51:1244-1249.