

1

Squamous cell carcinoma of the maxillary sinus mimicking periodontitis

¹Department of Oral and Maxillofacial Radiology, Yonsei University, College of Dentistry,

²Department of Periodontology, Yonsei University, College of Dentistry

Ji Yeon Na¹), Joo Hyun Kang²), Seong-Ho Choi²), Ho-Gul Jeong¹), Sang-Sun Han^{1)*}

ABSTRACT

Squamous cell carcinoma of the maxillary sinus mimicking periodontitis

¹Department of Oral and Maxillofacial Radiology, Yonsei University, College of Dentistry,

²Department of Periodontology, Yonsei University, College of Dentistry

Ji Yeon Na¹), Joo Hyun Kang²), Seong-Ho Choi²), Ho-Gul Jeong¹), Sang-Sun Han^{1)*}

Maxillary sinus squamous cell carcinoma is a relatively rare disease, comprising only 3% of malignant diseases of head and neck. As the growth rate is high and its prognosis is poor compared to others, the 5-year survival rate of maxillary sinus squamous cell carcinoma(MSSCC) is 23.4-49%.

We introduce two rare clinical cases of squamous cell carcinoma originated from maxillary sinus of which symptoms include toothache and gingival swelling. On clinical examinations of both patients, deep periodontal pockets on upper right posterior teeth were detected. On panoramic images, the bony destruction of the maxillary sinus and its surrounding structures were not obvious and only alveolar bone loss was noted. It is difficult to diagnose MSSCC at an early stage due to symptoms of tooth pain and gingival swelling that are similar to that of periodontal diseases. However, if the symptoms do not improve after routine treatment of upper teeth, dentists should bear in mind of underlying malignant mass as differential diagnosis, thus early detection of the lethal disease.

The aim of this study is to caution dental practitioners that malignancies have a potential to mimic periodontal diseases by introducing two cases of maxillary sinus squamous cell carcinoma presented as periodontitis.

Key words : Delayed diagnosis; Maxillary sinus; Periodontitis; Squamous cell carcinoma; Prognosis

Corresponding Author

Prof. Sang-Sun Han

Department of Oral and Maxillofacial Radiology, Yonsei University, College of Dentistry

50-1 Yonsei-ro Seodaemun-gu, Seoul, Korea, 03722

E-mail: sshan@yuhs.ac, Phone : 82-2-2228-8843, Fax : 82-2-363-5232

Ji Yeon Na and Joo Hyun Kang were equally contributed as the first authors.

I . INTRODUCTION

The maxillary sinus is a pyramid-shaped cavity lined by ciliated epithelium and bound by bony structures¹⁾. The most prevalent malignant disease in the maxillary sinus is squamous cell carcinoma(MSSCC), although it is a relatively rare disease, comprising only 3% of malignant diseases of head and neck^{2, 3)}. However, the growth rate is high and its prognosis is poor compared to others⁴⁾. Despite the advances in diagnosis and treatment skills, the 5-year survival rate of maxillary sinus squamous cell carcinoma is 23.4-49%⁵⁻¹⁰⁾.

The signs and symptoms of MSSCC include nasal fullness, stuffiness, obstruction, epistaxis, rhinorrhea, pain, tooth mobility, tooth loss, gingival swelling, and lacrimation^{2, 4, 6, 11)}. These symptoms are a reflection that tumor has invaded structures such as nasal and oral cavities, palate, orbit, skull, and other paranasal sinuses. These symptoms are non-specific and are easily mistaken for those of inflammatory reactions associated with benign diseases^{10, 12)}.

Especially, the symptoms of MSSCC patients who have gingival swelling and periodontal pockets mimic the condition of chronic periodontitis, so the patient may visit dental clinic. On routine radiographic examination in dental clinic such as periapical and panoramic radiographs, the bony destruction of the maxillary sinus and its surrounding structures may not be obvious in most of the cases and absent of any indications of malignant bony destruction in the adjacent structures¹³⁾. This

often leads to its misdiagnosis as either pulpal or periodontal diseases. The resultant endodontic or periodontal treatment delays the diagnosis of MSSCC. Its delayed diagnosis at the advanced stage of the malignancy may largely attribute to poor prognosis of MSSCC. Thus, early detecting the initial symptoms of MSSCC may be crucial for a more favorable prognosis.

Here, we introduce two rare clinical cases of MSSCC in which symptoms of toothache and gingival swelling were initially diagnosed and treated as periodontic and endodontic diseases but were later correctly diagnosed as MSSCC. The aim of this study is to inform dental practitioners that the malignancies have a potential to mimic periodontal diseases and to caution them to consider the possibility of underlying aggressive neoplasm by introducing two cases of MSSCC presented as periodontitis.

II . CASE DESCRIPTION

1. Case 1

A 66-year-old male patient visited the Department of Conservative Dentistry in Yonsei University Dental Hospital for severe pain of the upper right first and second premolars after receiving endodontic treatments at his local dental clinic. The first symptoms of the teeth pain occurred 15 days before. On clinical examination, deep periodontal pocket of more than 6mm on distal area of the upper right second premolar was detected, with gingival redness and

swelling on buccal side. On electric pulpal testing, the upper right first molar showed normal tooth vitality. All teeth showed negative response on percussion and grade I mobility. On panoramic image, alveolar bone resorption was noted on upper right molars and premolars, and the walls of the right maxillary sinus were examined to be intact(Fig. 1a). Intraoral radiographic image showed alveolar bone loss and periodontal ligament space widening of the upper right second premolar(Fig. 1b).

The upper right premolars were diagnosed as previously treated symptomatic apical periodontitis. In order to control the pain and swelling, medication was prescribed and endodontic treatment of the upper right second premolar was commenced after 1 week, however, no pus was discharged.

The dental pain did not subside despite the treatment, and the subsequent clinical examination of the patient revealed a 12mm of periodontal pocket on buccal gingival area of the upper right second premolar and facial swelling. A differential diagnosis was made as periodontal

abscess and the patient was referred to Department of Periodontology. After one week, periodontal flap operation on upper right first and second premolars was performed. During the operation, a fenestration on anterior and posterior walls of the right maxillary sinus was noted. A biopsy of granulation tissue of the involved area and computed tomography(CT) examination were requested.

On axial CT images, a tumor filling the entire maxillary sinus cavity was noted, hence the aggressive destruction of the anterior and postero-lateral walls of the right maxillary sinus was seen(Fig. 2a). On reformatted panoramic CT images, the destruction of medial and inferior walls of the sinus and the involvement of apical areas of the upper right molars and premolars were also noted(Fig. 2b). On biopsy, the pathologic finding of the mass led to diagnosis as MSSCC(Fig. 3).

Because of the extent of the carcinoma, a maxillectomy including all of the right upper teeth was carried out. Two months after the surgery, he started chemoradiotherapy.

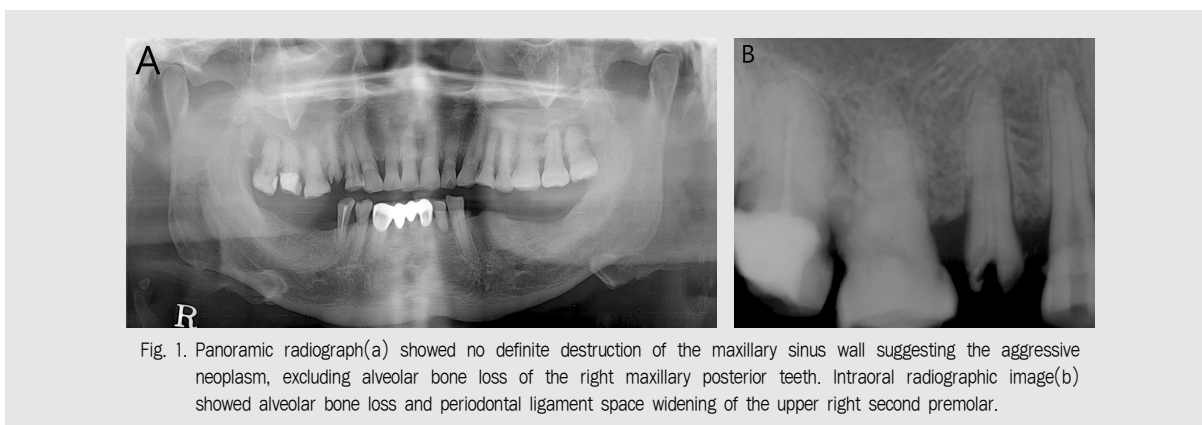


Fig. 1. Panoramic radiograph(a) showed no definite destruction of the maxillary sinus wall suggesting the aggressive neoplasm, excluding alveolar bone loss of the right maxillary posterior teeth. Intraoral radiographic image(b) showed alveolar bone loss and periodontal ligament space widening of the upper right second premolar.

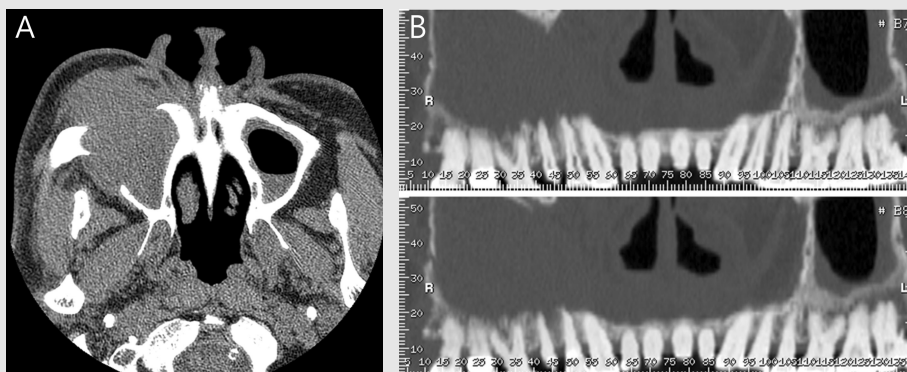


Fig. 2. Axial CT (a) image showed expansile mass destroying the anterior and postero-lateral wall of the right maxillary sinus. Reformatted panoramic image of CT (b) showed that the destruction of medial and inferior walls of the right maxillary sinus and the mass involved the right maxillary posterior teeth.

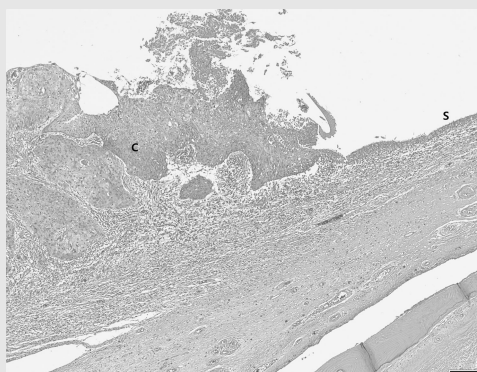


Fig. 3. Squamous cell carcinoma transforming from the sinus epithelium filling the right maxillary sinus cavity was noted (C: carcinoma, S: sinus epithelium, x40, hematoxylin-eosin).

Following a post-operative check-up of one month, there was no evidence of recurrence.

2. Case 2

A 56-year-old male patient visited the Department of Periodontology, Yonsei University Dental Hospital for gingival swelling of the upper right first molar and facial swelling of the right infraorbital region. Previously, the patient had received 5 months of medication and periodontal treatment of the right posterior

maxillary teeth at a local dental clinic, however, the pain did not subside. The patient reported spontaneous throbbing tooth pain and persistent gingival bleeding upon tooth brushing that had begun a month before the visit.

On oral examination, gingival swelling around upper right first molar was noted with a 9 mm of periodontal pocket on lingual side. A negative response of percussion and mobility test was shown, and the tooth was vital on electric pulpal test. Panoramic images showed a periapical radiolucency on right upper canine, and a

relatively unclear margined lateral wall of the right maxillary sinus compared to that of the opposite side(Fig. 4a), and intraoral radiographic image showed alveolar bone loss and periodontal ligament space widening of the upper right first molar(Fig. 4b). Periodontal flap operation was planned under the diagnosis of chronic periodontitis on upper right first molar in order to reduce periodontal pocket depth, which was performed after 10 days. However, the pain only lessened to a small degree, and the facial swelling worsened. To determine the origin of

the pain-that it was indeed from the right maxillary origin disease-CT scans were obtained.

The axial CT images showed a soft-tissue tumor that occupied the entire space of the right maxillary sinus. The tumor intruded into not only the postero-lateral and the anterior walls of the right maxillary sinus, but also partially into the medial wall, leaving areas of distinct bone destruction(Fig. 5a). On coronal CT images, the lesion has destroyed the most of the bony walls, including the inferior wall of the right orbit(Fig. 5b). The biopsy confirmed invasive squamous

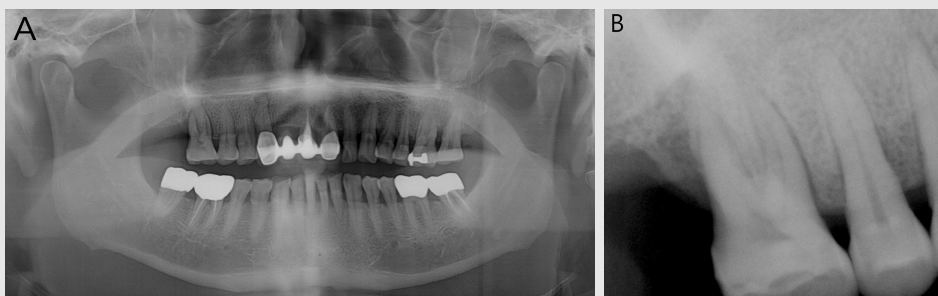


Fig. 4. Panoramic radiograph (a) showed a periapical radiolucency on right upper canine, and a relatively unclear margined lateral wall of the right maxillary sinus compared to that of the opposite side. Intraoral radiographic image (b) showed alveolar bone loss and periodontal ligament space widening on the right first upper molar.

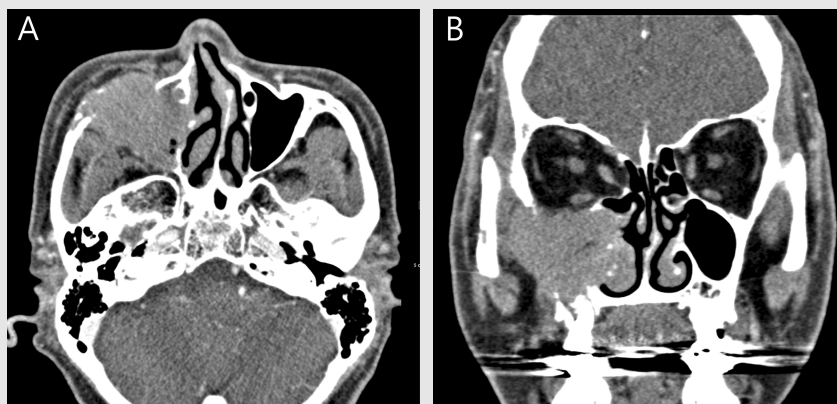


Fig. 5. Axial CT image (a) showed a soft tissue mass that occupied the entire space of the right maxillary sinus. The mass intruded into not only the postero-lateral and the anterior walls of the right maxillary sinus, but also partially into the medial wall. On coronal CT image (b), the lesion has destroyed the most of the bony walls, including the inferior wall of the right orbit.

cell carcinoma in the maxillary sinus. Thus, within 6 months of the patient's first visit of local dental clinic, the maxillary sinus malignancy which was initially mistaken for an odontogenic infection was correctly diagnosed. Further, a CT of the neck revealed metastasis of this tumor to lymph nodes of the L1, L5 vertebra and a T6 cord, which meant surgery was no longer a viable option. Thus, it was decided that adjuvant chemoradiotherapy should be performed. Despite the treatments, the pain exacerbated and the patient altogether refused to continue with the treatments. After a while, he sought emergency medical care due to extreme pain and dizziness. The patient passed away 17 months after the confirmed diagnosis of MSSCC.

III. DISCUSSION

According to previous reports, at the time of diagnosis, over 80% of patients with MSSCC have stage T3 or more advanced stage cancers, and over 50% of patients are diagnosed with stage T4 MSSCC^{2, 10}. A long interval from first presentation of symptoms to final diagnosis is reported to have a significant effect on a prognostic factor for survival¹⁸. The delayed diagnosis of the oral squamous cell carcinoma may be either patient-derived or professionally-derived¹⁴. Patient diagnostic delays may arise because the patient is slow to piece together their early symptoms, slowing their hospital consultation, while professional diagnostic delays may result because of an erroneous initial

diagnosis of the patient condition, leading to no or inappropriate treatment.

Due to the structural characteristics of the maxillary sinus being an empty cavity filled with air, no specific symptoms will be experienced until the cavity is filled with mass and destruction of the adjacent structures occurs^{2, 9}. In addition, direct inspection of the mass or palpation is often entirely impossible, and the patient's first perception of the initial symptoms is much delayed compared to patients with SCC of oral cavity⁹. Accordingly, previous reports show that around 12% of MSSCC patients are asymptomatic^{8, 15}.

A professional diagnostic delay of MSSCC is because symptoms suggestive of tumor invasion such as pain, edema, obstruction, epistaxis, and dental symptoms are mostly non-specific and are easily mistaken for symptoms of inflammatory reactions associated with benign diseases¹⁶. Kreppel et al.⁸ reported that there was an average time lapse of 6-8 months from the onset of the symptoms before a diagnosis of MSSCC was made.

The study of Santos et al.² showed that 56.7% of MSSCC patients have initial symptoms related to mouth. In 38.4% of the patients, symptoms similar to those of periodontitis, such as pain or mobility of maxillary teeth and gingival swelling are found. In general, patients who have initial symptoms related to teeth receive an oral examination and a primary radiographic examination (panoramic or intraoral imaging). However, bony destructive changes suggestive of maxillary sinus cancer are hard to be

distinguished through these 2 dimensional approaches of imaging. Maxillary sinus is a pyramidal structure with borders consisted of anterior, posterior, medial, upper and inferior bony walls, and panoramic views have limitation to present this 3-dimensional cavity into 2-dimensional plane. Also, the overlapping of the anatomical structures and low resolution of the images cause the failure in diagnosing disease at an earlier stage, and its bone destruction patterns^{17, 18)}.

In the first case, the destruction of the anterior and the posterior-lateral walls was significantly noted on CT images, however, it was not detected on the panoramic radiograph. Although the panoramic image of the second case revealed an “unclear” region on the lateral wall of the right maxillary sinus in relation to the contralateral side, it could be seen from the axial CT images that there was an extensive bone destruction not only of the anterior and the postero-lateral walls of the right maxillary sinus, but also partially of the medial wall of the right maxillary sinus and

the inferior wall of orbit.

The durations from the initial onset of symptoms until the diagnoses were 1 month and 6 months in the first case and the second case, respectively. Although the metastatic potential of MSSCC has known to be low²⁾, the second patient in this paper unfortunately could not prevent it, and passed away eventually.

As can be concluded from both cases, it is difficult to diagnose MSSCC at an early stage due to symptoms of dental pain and gingival swelling that are similar to those of periodontal diseases. However, if the symptoms do not improve after routine treatment of upper teeth, dentists should bear in mind of malignant mass as differential diagnosis, thus early detection of the lethal disease. Also, since overlapping and low resolution of plain radiographs do not provide sufficient diagnostic sensitivity to diagnose subtle bony changes that originate from malignant tumors, it is strongly advised to evaluate the disease by further radiographic examinations such as CT.

참 고 문 헌

1. Al-Jhani AS, Al-Rajhi NM, El-Sebaie MM, et al. Maxillary sinus carcinoma - Natural history and outcome. *Saudi Med J* 2004;25(7):929-933 Saudi Med J.
2. Santos MR, Servato JP, Cardoso SV, et al. Squamous cell carcinoma at maxillary sinus: clinicopathologic data in a single Brazilian institution with review of literature. *Int J Clin Exp Pathol* 2014;7(12):8823-8832.
3. Wang JH, Lee JH, Han JH, et al. Contralateral maxillary sinus lesions in patients with nasal cavity and/or paranasal sinus carcinoma: analysis of computed tomography findings. *Ann Otol Rhinol Laryngol* 2008;117(12):909-913.
4. Turner JH, Reh DD. Incidence and survival in patients with sinonasal cancer: a historical analysis of population-based data. *Head Neck* 2012;34(6):877-885.
5. Tiwari R, Hardillo JA, Mehta D, et al. Squamous cell carcinoma of maxillary sinus. *Head Neck* 2000;22(2):164-169.
6. Paulino AC, Marks JE, Bricker P, et al. Results of treatment of patients with maxillary sinus carcinoma. *Cancer* 1998;83(3):457-465.
7. Bhattacharyya N. Factors affecting survival in maxillary sinus cancer. *J Oral Maxillofac Surg* 2003;61(9):1016-1021.
8. Kreppel M, Safi AF, Scheer M, et al. The importance of early diagnosis in patients with maxillary sinus carcinoma. *Eur Arch Otorhinolaryngol* 2016;273(9):2629-2635.
9. Bobinskas AM, Wiesenfeld D, Chandu A. Influence of the site of origin on the outcome of squamous cell carcinoma of the maxilla-oral versus sinus. *Int J Oral Maxillofac Surg* 2014;43(2):137-141.
10. Dubal PM, Bhojwani A, Patel TD, et al. Squamous cell carcinoma of the maxillary sinus: A population-based analysis. *Laryngoscope* 2016;126(2):399-404.
11. Stern SJ, Goepfert H, Clayman G, et al. Squamous-cell carcinoma of the maxillary sinus. *Archives of Otolaryngology-Head & Neck Surgery* 1993;119(9):964-969.
12. Kaneko T, Tada Y, Maruya S, et al. Intra-arterial chemoradiation therapy with weekly low-dose cisplatin for squamous cell carcinoma of the maxillary sinus. *Int J Oral Maxillofac Surg* 2015;44(6):697-704.
13. Linz C, Muller-Richter UD, Buck AK, et al. Performance of cone beam computed tomography in comparison to conventional imaging techniques for the detection of bone invasion in oral cancer. *Int J Oral Maxillofac Surg* 2015;44(1):8-15.
14. Gao W, Guo CB. Factors Related to Delay in Diagnosis of Oral Squamous Cell Carcinoma. *J Oral Maxillofac Surg*. 2009;67(5):1015-1020.
15. Carrau RL, Myers EM, Johnson JT. Paranasal sinus carcinoma--diagnosis, treatment, and prognosis. *Oncology (Williston Park)* 1992;6(1):43-50; discussion 55-46.
16. Edwards PC, Hess SJ, Saini T. Sinonasal undifferentiated carcinoma of the maxillary sinus. *J Can Dent Assoc* 2006;72(2):163-167.
17. White SC, Pharoah MJ. The evolution and application of dental maxillofacial imaging modalities. *Dent Clin North Am* 2008;52(4):689-705, v.
18. Shahbazian M, Vandewoude C, Wyatt J, Jacobs R. Comparative assessment of panoramic radiography and CBCT imaging for radiodiagnostics in the posterior maxilla. *Clin Oral Investig* 2014;18(1):293-300.