

1

Subcutaneous emphysema during removal of suture after intraoral surgery

Dept. of Oral and maxillofacial surgery, School of dentistry,
College of Dentistry, Wonkwang University

Jong-Chan Park, Hyeon-Seo Shin, Jeong-Wan Son, Jun Lee, Bong-Chul Kim, Hun-Jun Lim

ABSTRACT

Subcutaneous emphysema during removal of suture after intraoral surgery

Dept. of Oral and maxillofacial surgery, School of dentistry, College of Dentistry, Wonkwang University
Jong-Chan Park, Hyeon-Seo Shin, Jeong-Wan Son, Jun Lee, Bong-Chul Kim, Hun-Jun Lim

Subcutaneous emphysema is relatively rare postoperative complication in the oral and maxillofacial region. Most cases reported in maxillofacial area relate to the use of high-speed handpiece. However, in this case, subcutaneous emphysema was caused by compressed air blow performed during suture removal. Cone-Beam Computed Tomography was conducted to evaluate the extent of diffusion bubbles. In this report, we describe etiology, diagnosis, prevention and management of subcutaneous emphysema in the maxillofacial area.

Key words : Compressed air, Subcutaneous emphysema, Cone-Beam Computed Tomography

Corresponding Author

Hun-Jun Lim

Department of Oral and Maxillofacial Surgery

Daejeon Dental Hospital, Wonkwang University School of Dentistry

77 Dunsan-ro, Seo-gu, Daejeon, 35233, Republic of Korea

Tel : +82-42-366-1129, Email : hun216@gmail.com, Mobile : +82-10-3243-6861, Fax : +82-42-366-1115

This work was supported by Wonkwang University in 2017.

I . Introduction

Subcutaneous emphysema in maxillofacial region during surgery, first reported in 1900¹⁾, was caused by a series of processes. First, barrier in the oral cavity is broken, and the compressed air enters the subcutaneous tissue in this broken oral cavity which makes the surrounding connective tissue is separated. And then, these dispersed tissues enter the fascia space and spread to other areas²⁾. Subcutaneous emphysema in maxillofacial region is one of the rare complications in dentistry. It can be triggered by using high-speed handpiece or by using air syringe³⁾. It has also been reported that subcutaneous emphysema could be caused by various oral surgeries such as extraction⁴⁾, root canal treatment⁵⁾, resin restoration treatment⁶⁾, crown restoration⁷⁾, orthognathic surgery, and trauma such as facial fracture or laceration⁸⁾. The subcutaneous emphysema that occurs during dental treatments is characterized by sudden swelling and crepitus at the skin palpation. In most cases, it recede naturally with a good prognosis, but clinicians should be careful because it can lead to life-threatening complications if it invade to orbital, mediastinal, parapharyngeal, pericardial or thoracic space^{9, 10)}. Since most dentists believe that subcutaneous emphysema is developed during surgery, it is difficult to cope with the subcutaneous emphysema occurring at the time of simple check-up. Therefore, we report the orbital and periorbital subcutaneous emphysema, caused by air blow performed during the removal of suture

after left maxillary sinus lifting with implant placement.

II . Case report

A 52-year-old woman without any history of systemic disease performed dental implant placement with a left maxillary sinus lifting and with lateral approach in a local dental clinic. After surgery, she was well cured without any abnormal findings. Two weeks after the surgery, she re-visited to remove suture. Air was blown to the surgical site in order to check the wound using a 3-way air syringe attached to the unit chair. Then, the patient complained that left facial area and periorbital area were swollen, and she was referred to our hospital. At the time of visit, swelling was observed on left periorbital, temporal, buccal, submandibular, anterolateral neck area of the patient, and she complained slight dyspnea or dysphagia and expressed mild tenderness and crepitus on palpation on swelling area.

The overall haziness was observed on the left side of the panoramic radiograph. Cone beam computed tomography images showed air bubbles on the left orbital, periorbital, infratemporal, buccal, peri-masseteric, submandibular, parapharyngeal, and retropharyngeal space(Fig. 1, 2).

The patient was psychologically unstable due to the symptom, complaining to dentist and being anxious about her symptoms and prognosis. Therefore, we had to treat her carefully with explaining the cause of the symptom and

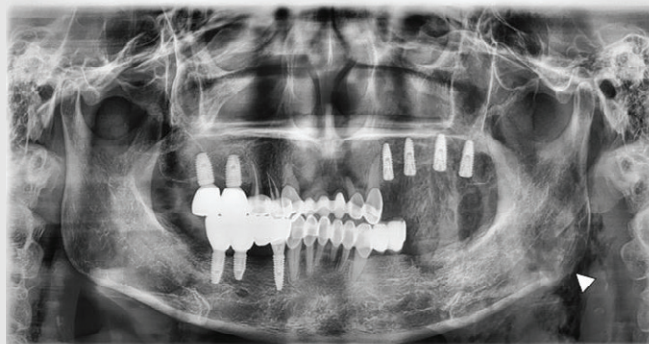


Fig. 1. Overall haziness was observed on the left side of the Panoramic radiograph(White Arrow : Air bubble)

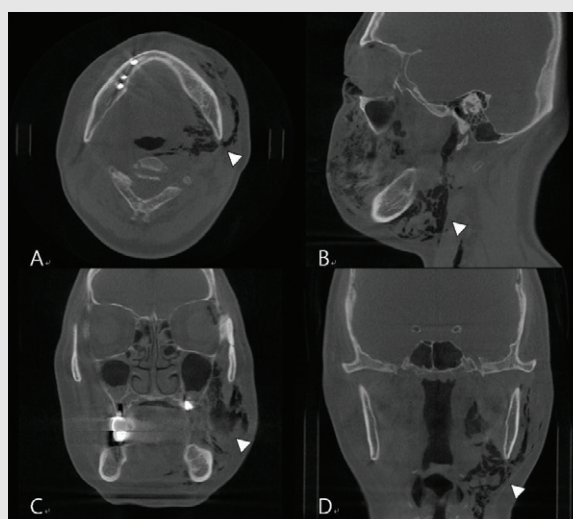


Fig. 2. Cone Beam Computed Tomography(CBCT) shows extensive air bubbles on the left orbital, periorbital, infratemporal, buccal, peri-masseteric, submandibular, parapharyngeal and retropharyngeal space in axial(A), sagittal(B), coronal(C,D) view. (White Arrow : Air bubble)

following treatments and giving her emotional support under admission for close checkup. Intravenous antibiotics as a side injection (Unizedone[®], 1g, Unimed Pharmaceutical Inc., Asan, Korea) t.i.d. and intramuscular analgesics injection (DicknoI[®], 2ml, Myungmoon Pharm. Co. Ltd., Daejeon, Korea) p.r.n. were administered to prevent secondary infection causing cellulitis or necrotizing fasciitis and pain control. Until the day after admission she

complained swelling and mild pain, however, complaints of dyspnea and dysphagia was ceased. On the second day, she was discharged because swelling, tenderness and crepitus began to decrease and she expressed relief about her situation. One week later, the swelling completely subsided without any other complications.

III. Discussion

Subcutaneous emphysema in maxillofacial region is characterized by the symptom that facial swelling occurs at the same time while the air enters. Crepitus at palpation appears in the facial area. When mediastinal pneumothorax is suspected, dyspnea, chest pain, back pain, and “Hamman sign”, which is a crunchy sound at the same time with heart beats⁵⁾. When entering the pericardial space, changes in the electrocardiogram may occur¹¹⁾. Subcutaneous emphysema should be distinguished from edema, such as hematoma, maxillofacial infection, allergic reaction, or angioneurotic edema¹²⁾. If subcutaneous emphysema is suspected, it is a priority to identify the range of the subcutaneous emphysema first using panoramic radiography and head and neck computed tomography.

In most cases, it is not accompanied by severe complications, but when the air spread into periorbital area, visual impairment due to compression neuropathy could occur. If the air enters the parapharyngeal or retropharyngeal space, air can accumulate and this causes airway obstruction¹³⁾, embolism, amnesia¹¹⁾, pneumothorax and pneumopericardium¹⁰⁾.

If the patient doesn't have dyspnea or if subcutaneous emphysema doesn't spread to chest, it is possible to treat with antibiotics at the outpatient clinic. In case of dyspnea or spreading of subcutaneous emphysema into the chest, hospitalization and intensive observation are necessary. The reason for prescribing antibiotics is that air can promote the activity of bacteria in

oral cavity, causing cellulitis or necrotizing fasciitis. In addition, if there is a mild pain, analgesics can be prescribed to relieve the patient's anxiety. In some cases, a low dose of steroid(dexamethasone) was used. However, there is no consensus in which treatment is more effective between antibiotics and steroid in treating subcutaneous emphysema¹¹⁾. Administration of 100% oxygen through a nonrebreather mask is effective because it replaces subcutaneous air with oxygen accelerating the uptake of air in the tissue¹⁴⁾. If the patient shows signs of airway obstruction and respiratory distress due to subcutaneous emphysema in parapharyngeal space at the time of admission, tracheostomy is necessary¹⁴⁾. In most cases, it is considered safe if there are no complications for 3 to 5 days, and a complete recovery takes about 7 to 10 days.

To prevent subcutaneous emphysema, surgeons should pull the flap so as not to damage soft tissues from the high-speed handpiece after elevation of mucoperiosteal flap during third molar extraction. Use of the high-speed handpiece should be minimized, and using low-speed handpiece is recommended³⁾. Air through three-way syringe, which is often used in dentistry, is also a major cause of subcutaneous emphysema. Therefore, for root canal treatment, a rubber dam should be applied and the use of compressed air during root canal irrigation should be avoided⁵⁾. It should also avoid to directly blow compressed air into the oral wound or lesion.

In this case, the clinician was unsuccessful to attempt to aspirate the air through the needle

after the symptom developed. The patient was mentally unstable at the time of referral to our hospital. Because subcutaneous emphysema is rare, most dentists do not often experience subcutaneous emphysema, so proper care may be difficult when complications occur. Also, we

should be aware of appropriate knowledge and coping strategies because it can occur not only in surgery but also by air blowing even in simple procedures such as conservation dental treatment and removal of suture.

참 고 문 헌

1. Fleischman D, Davis RM, Lee LB. Subcutaneous and periorbital emphysema following dental procedure. *Ophthal Plast Reconstr Surg*. 2014;30:e43-e45.
2. Tomasetti P, Kuttenger J, Bassetti R. Distinct subcutaneous emphysema following surgical wisdom tooth extraction in a patient suffering from 'Gilles de la Tourette syndrome'. *Journal of surgical case reports*. 2015;2015:rjv068.
3. Cha YH, Kim BJ, Kim C, Narm KS, Lee DY, Haam SJ. Pneumomediastinum and Subcutaneous Emphysema after Dental Treatment. *The Korean Journal of Thoracic and Cardiovascular Surgery*. 2010;43:797-799.
4. Romeo U, Galanakis A, Lerario F, Daniele GM, Tenore G, Palaia G. Subcutaneous emphysema during third molar surgery: a case report. *Brazilian dental journal*. 2011;22:83-86.
5. Kim Y, Kim M-R, Kim S-J. Iatrogenic pneumomediastinum with extensive subcutaneous emphysema after endodontic treatment: report of 2 cases. *Oral Surg Oral Med Oral Pathol Oral Radiol*. 2010;109:e114-e119.
6. Steelman RJ, Johannes PW. Subcutaneous emphysema during restorative dentistry. *Int J Paediatr Dent*. 2007;17:228-229.
7. Zemann W, Feichtinger M, K?rcher H. Cervicofacial and mediastinal emphysema after crown preparation: a rare complication. *Int J Prosthodont*. 2007;20:143.
8. Vargo R, Potluri A, Yeung A, Aldojain A, Bilodeau E. Cervicofacial subcutaneous emphysema: a clinical case and review of the literature. *General dentistry*. 2016;64:68-71.
9. Bilecenoglu B, Onul M, Altay OT, Sakul BU. Cervicofacial emphysema after dental treatment with emphasis on the anatomy of the cervical fascia. *Journal of Craniofacial Surgery*. 2012;23:e544-e548.
10. Arai I, Aoki T, Yamazaki H, Ota Y, Kaneko A. Pneumomediastinum and subcutaneous emphysema after dental extraction detected incidentally by regular medical checkup: a case report. *Oral Surg Oral Med Oral Pathol Oral Radiol*. 2009;107:e33-e38.
11. McKenzie WS, Rosenberg M. Iatrogenic subcutaneous emphysema of dental and surgical origin: a literature review. *J Oral Maxillofac Surg*. 2009;67:1265-1268.
12. Fruhauf J, Weinke R, Pilger U, Kerl H, Mullegger RR. Soft tissue cervicofacial emphysema after dental treatment: report of 2 cases with emphasis on the differential diagnosis of angioedema. *Arch Dermatol*. 2005;141:1437-1440.
13. Yoshimoto A, Mitamura Y, Nakamura H, Fujimura M. Acute dyspnea during dental extraction. *Respiration*. 2002;69:369-371.
14. Reznick JB, Ardary WC. Cervicofacial subcutaneous air emphysema after dental extraction. *J Am Dent Assoc*. 1990;120:417-419.