

1

소아에서의 낭종성 병소로 인해 변위된 영구치의 공간유지 감압술을 통한 자발적 맹출 유도

이가형¹, 강재현¹, 김시운¹, 김봉철¹, 임헌준¹

¹원광대학교 치과대학 대전치과병원 구강악안면외과

ORCID ID

Ga-Hyung Lee,  <https://orcid.org/0000-0002-1768-7510>

Jae Hyun Kang,  <https://orcid.org/0000-0002-7359-815X>

See Woon Kim,  <https://orcid.org/0000-0002-7795-860X>

Bong Chul Kim,  <https://orcid.org/0000-0003-2824-0439>

Hun Jun Lim,  <https://orcid.org/0000-0003-2466-0604>

ABSTRACT

Induction of spontaneous eruption of displaced permanent teeth through space maintenance decompression of cystic lesion in pediatric patients

Ga-Hyung Lee, DDS¹, Jae Hyun Kang, DDS¹, See Woon Kim, DDS¹, Bong Chul Kim, DDS, PhD¹,
Hun Jun Lim, DDS, PhD¹

¹Department of Oral and Maxillofacial surgery, Daejeon Dental Hospital, College of Dentistry,
Wonkwang University, Daejeon, Republic of Korea

Cystic lesions in pediatric jaws can cause eruption disorders by displacing the erupting permanent teeth, and in the case of secondary infection, can cause swelling and pain. The treatment modalities for such cysts include cyst enucleation, marsupialization, and decompression. As compared to enucleation, decompression has the advantage of preventing damage to surrounding tissues and inducing spontaneous eruption of permanent teeth.

We report a case where decompression was performed using a stent designed for decompression and as a space maintainer in three patients with eruption disorder due to cystic lesion of the jaw. The eruption of the displaced permanent teeth was successfully induced by maintaining the eruption space and removing the cyst.

Key words : Decompression, Space Maintainers, Displacement of permanent teeth, Spontaneous eruption

Corresponding Author

Hun-Jun Lim, DDS, PhD, Associate Professor

Department of Oral and Maxillofacial Surgery, Daejeon, Dental Hospital, College of Dentistry, Wonkwang University

77 Dunsan-ro, Seo-gu, Daejeon 35233, Republic of Korea, 35233

E-mail : hun216@wku.ac.kr / Tel : +82-42-366-1130 (clinic), +82-10-3243-6861 (mobile) / Fax : +82-42-366-1115

ACKNOWLEDGEMENT This work was supported by Wonkwang University in 2021.

Introduction

Dental cysts are generally asymptomatic and gradually increase in size, often causing displacement of adjacent teeth. Specifically in children with mixed dentition, if a cyst occurs in the jaw, the permanent teeth may not erupt normally, thus it becomes necessary to induce the eruption of displaced permanent teeth.

Cyst enucleation is the surgical removal of a cyst along with the affected tooth. This method can shorten the treatment period and lower the recurrence rate; however, it can damage surrounding tissues (inferior alveolar nerves) and often fails to preserve permanent teeth¹⁾.

Decompression and marsupialization are the preferred treatment alternatives for jaw cysts that protect the surrounding tissues^{1,2)}. Decompression is a method of reducing intra-cystic pressure by opening the cystic cavity and inserting a tube for constant drainage. When applying a decompression device to a young patient, clinicians often experience several problems such as patient discomfort, lack of patient cooperation, and effort to fabricate the decompression device. However, decompression has the advantage of preventing damage to surrounding tissues (particularly the inferior alveolar nerve or permanent teeth) and reducing the size of the cyst, thus leading to spontaneous eruption of the permanent teeth²⁾.

We designed a device for decompression using a silicon tube with an acrylic resin that minimally interfered with the surrounding tissues. Herein, we

report three cases in which the cyst was effectively removed, and the displaced permanent teeth spontaneously erupted.

Cases Report

Case 1

A 7-year-old girl was referred from a local dental clinic for swelling in the left buccal area. Clinical examination revealed swelling of the left buccal mucosa and purulent drainage from the mandibular left primary first molar. A panoramic radiograph revealed a large radiolucent lesion corresponding to the mandibular left primary molars. Owing to this lesion, the permanent teeth (mandibular first and second premolars) were displaced from the normal eruption position to the mesial and distal sides(Fig. 1).

After removing the mandibular left primary first and second molars, a decompression device designed as a space maintainer was placed under local anesthesia through the extraction socket without cyst enucleation(Fig 2). Follow-up was accomplished at 2 months intervals, and the tube length of the device was adjusted according to the size of the lesion and eruption pattern of the permanent teeth. The panoramic radiograph taken 4 months after decompression confirmed that the position of the mandibular left first and second premolars had improved(Fig. 3), and the device was subsequently removed. Four months after device removal, it was confirmed that the permanent teeth erupted

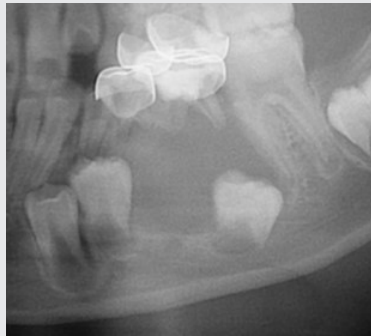


Figure 1. Initial panoramic radiograph depicts the cystic lesion and displaced permanent teeth on the left mandible.

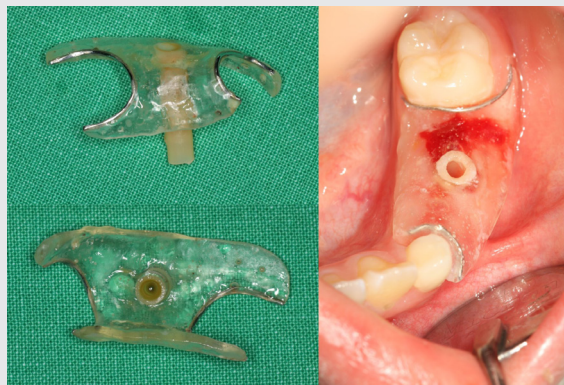


Figure 2. A decompression device designed as a space maintainer(A). The device is installed into the cyst cavity through the extraction socket(B).

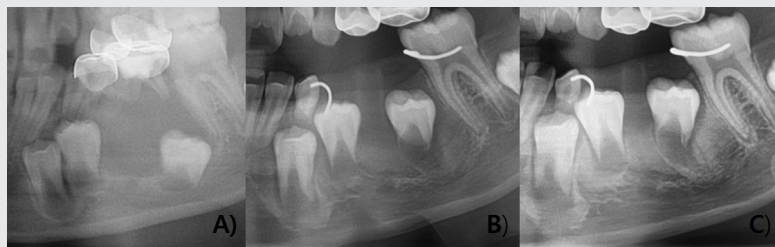


Figure 3. The spontaneous eruption of permanent teeth after decompression. Before the decompression(A), 2 months after decompression(B), 4 months after decompression(C). The permanent teeth erupt to the normal eruption position.

normally(Fig. 4).

Case 2

A 7-year-old boy was referred from a local dental clinic presenting with a cystic lesion in the mandibular right premolar area. A panoramic radiograph revealed a well-defined radiolucent lesion below the mandibular primary first and second molars(Fig. 5).

After removing the mandibular right primary first and second molars, a decompression device designed as a space maintainer was installed under local anesthesia through the extraction socket without cyst enucleation. Follow-up was accomplished at 2 months intervals, and the tube length of the device was adjusted according to the size of the lesion and eruption pattern of the permanent teeth. The panoramic radiograph taken 7 months after decompression confirmed that the position of

the mandibular right first and second premolars had improved(Fig. 6), and the device was subsequently removed. The patient was referred to the local dental clinic for further follow up.

Case 3

A 9-year-old boy was referred from a local dental clinic for a cystic lesion in the mandibular right premolar area. On the panoramic radiograph, we observed a well-defined, unilocular, large radiolucent lesion under the mandibular right primary canine, primary first, and second molars. The lesion displaced the permanent mandibular canine, first and second premolars(Fig. 7).

After extraction of the mandibular right primary first molar, a decompression device was installed through the extraction socket under local anesthesia. Subsequently, regular checkups were performed

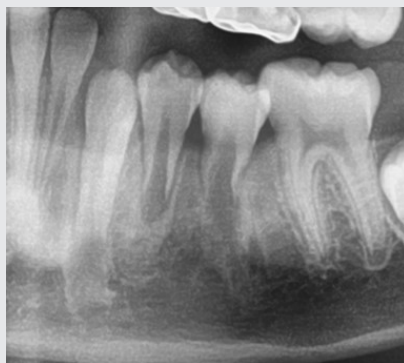

Figure 4. Panoramic radiograph after 4 months. A successful normal eruption of the displaced permanent teeth is seen.

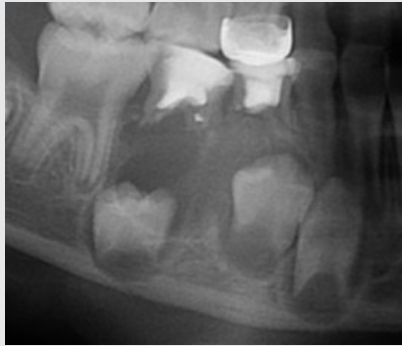

Figure 5. Initial panoramic radiograph shows the cystic lesion and displaced permanent teeth on the right mandible.

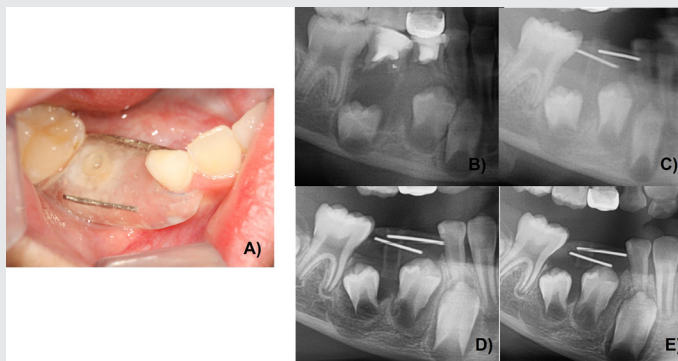


Figure 6. The device is installed into the cyst cavity through the extraction socket(A). Before decompression(B), 2 months after decompression(C), 4 months after decompression(D), 7 months after decompression(E).

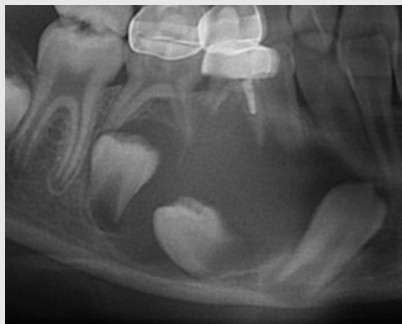

Figure 7. Initial panoramic radiograph shows the cystic lesion and displaced permanent teeth on the right mandible.

every 3 months. Eight months after decompression, it was confirmed that the permanent teeth had erupted to the alveolar ridge on panoramic radiography. Additionally, we extracted the mandibular right primary second molar while removing the device and referred the patient to the pediatric dentist for permanent tooth alignment(Fig. 8). After 2 years, it was confirmed that the permanent teeth erupted

normally(Fig. 9).

Discussion

Owing to certain stimuli, the epithelium associated with tooth development (reduced enamel epithelium, dental lamina remnants, and the rest of

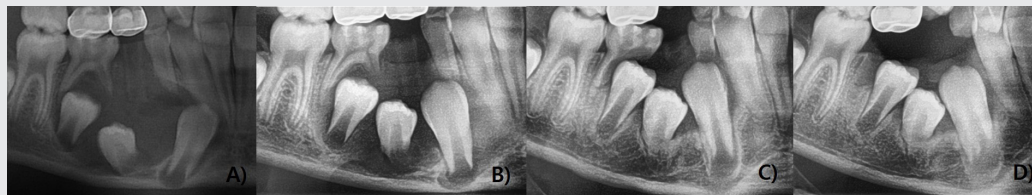


Figure 8. Panoramic radiograph. Before the decompression(A), 2 months after decompression(B), 6 months after decompression(C), 8 months after decompression(D).

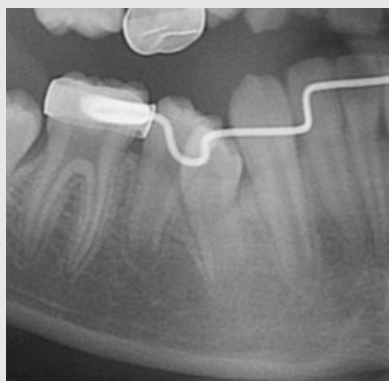


Figure 9. Panoramic radiograph after 2 years of decompression. A successful normal eruption of the displaced permanent teeth is seen.

Malassez) often causes cyst formation. The rest of Malassez are Hertwig epithelial root sheaths, which are natal epithelial structures that remain in the periodontal ligament even after root formation is complete and are primarily present in the apical region. These remnants generate periapical(radicular) cysts in response to inflammation³. This report describes a case of permanent tooth bud displacement due to a cyst that developed below the mandibular primary molars. In each case, the mandibular primary molars were treated for dental caries, and the permanent teeth were displaced downward or laterally because of a cystic lesion that occurred below the root of the primary molar. Based on the clinical and radiological findings, the cyst was diagnosed as a periapical cyst.

Jaw cysts in the mixed dentition can cause permanent tooth displacement and impaired eruption. Since cyst enucleation can cause damage to developing permanent teeth, a conservative approach such as marsupialization or decompression is required in children⁴.

Decompression is a modified form of marsupialization where a decompression device(silicone tube, stent) is placed into the cyst cavity for several months. This technique can also reduce cyst size by reducing the intra-cystic pressure. However, like marsupialization, this procedure has a limitation in that it is not possible to perform a pathological examination of the entire lesion. Moreover, performing this technique requires the cooperation of the patient to allow the irrigation of the cyst cavity daily and requires long-term follow-up⁴.

The most common complications of jaw cysts in pediatric patients are swelling and delayed eruption of the permanent teeth⁵. If the cyst is large, enucleation increases the possibility of damage to the adjacent tissues (particularly permanent teeth)⁶. Therefore, marsupialization or decompression is considered the most effective treatment for jaw cysts in pediatric patients. Several previous studies have shown that there is no significant difference in the rate of recurrence of cysts following enucleation and decompression⁷⁻⁹. In pediatric patients, complete removal of the lesion and reduction in recurrence rate should be considered; however, it is also important to induce the eruption of the permanent teeth to ensure the normal dentition. Therefore, it is preferable to select a procedure that can preserve permanent teeth.

Decompression is the principal method for the treatment of jaw cysts in pediatric patients; however, to be successful, the cooperation of the patient and periodic follow-up are essential. During decompression, the decompression device should be kept in the oral cavity for a period of approximately 6-12 months. If the patient does not keep the device for a long time due to discomfort and a feeling of foreign body in the mouth, the effectiveness of the decompression procedure is bound to decrease. Additionally, as the decompression period is prolonged, the eruption space for the permanent teeth may be reduced owing to the movement of the adjacent teeth. In such cases, additional orthodontic interventions are necessary⁷.

Therefore, we designed a removable decompres-

sion device using a silicone tube with acrylic resin. The silicone tube was inserted into the cyst cavity through the extraction socket after primary molar extraction. This device is designed as a flipper-type denture, and a tube for cleaning the inside of the cyst is attached to the occlusal area so that it can enter the inside of the cyst. Furthermore, a tube was used to cut off the infusion set. This design can also function as a space maintainer to prevent narrowing of the eruption space of permanent teeth owing to the movement of adjacent teeth.

The acrylic resin frame of the device is limited to the occlusal surface, and the retention force is obtained by adjacent teeth and tube, thereby minimizing the patient's discomfort. In addition, because this device is removable, it is convenient for the clinician to modify the tube length during the treatment period, and the patient or his/her guardian can clean the device at home. During regular check-ups, radiographs were taken to check the size of the cyst and the change in the location of the permanent teeth. To induce a normal eruption of the permanent teeth, we adjusted the length of the tube according to the eruption pattern of the permanent teeth. When it was confirmed that the permanent teeth were close to emerging, the decompression device was removed.

Furthermore, a flipper-type decompression device was installed in each case after the primary molar was extracted. We educated the patient's par-

ents on how to attach and detach the device, and irrigate the cyst through the tube using normal saline and a syringe. Subsequently, we followed up on the change in the size of the cyst and eruption of the permanent tooth at 2-month intervals. As the permanent tooth was seen to erupt coronally on the panoramic radiograph, we trim the tube length to maintain the space for eruption. The device was removed when the permanent teeth erupted into the oral cavity, and the total treatment periods were 4, 7, and 8 months. After the device was removed, the permanent eruption was confirmed, and there was no recurrence of the cyst.

Currently, various types of decompression devices are used. Most of the previously reported decompression devices were inserted into the cyst by inserting a silicone or metal tube. Additionally, to prevent the mesial movement of adjacent teeth (particularly the first molar), a space maintenance device such as a band and loop is typically required¹⁰⁾. In the reported cases, we devised a decompression device design that can serve as a space maintainer while minimizing a feeling of foreign body, and we used it in the management of jawbone cysts successfully preventing the permanent teeth eruption disorder. Moreover, the device design is convenient, simple, and effective to use even during long-term treatment periods and are highly recommended for clinicians who are considering decompression.

참 고 문 헌

1. De Azambuja Berti S, Pompermayer AB, Souza PHC, Tanaka OM, Westphalen VPD, Westphalen FH. Spontaneous eruption of a canine after marsupialization of an infected dentigerous cyst. *Am J Orthod Dentofac Orthop.* 2010;137(5):690-3.
2. Gurler G, Yilmaz S, Delilbasi C, Dilaver E, Yuzbasioglu E, Patir-Munewveroglu A. Conservative surgical treatment of the jaw cysts in children: Case study of five patients. *Niger J Clin Pract.* 2017;20(9):1216-20.
3. Bodner L. Cystic lesions of the jaws in children. *Int J Pediatr Otorhinolaryngol.* 2002;62(1):25-9.
4. Hong H, Nam O, Kim M, Choi S, Lee H. Analysis of 269 Cases of Jaw Cysts in Children and Adolescents: A Retrospective Study over a Decade. *J Korean Acad Pediatr Dent.* 2016;43(3):237-45.
5. Padmakumar SK. Cysts of the Jaws in Pediatric Population : A 12-Year Institutional Study. *Oral Maxillofac Pathol Journal.* 2015;6(1):532-6.
6. Kamasaki Y, Sasaki Y, Fujiwara T. Management of an extensive dentigerous cyst in a 12-year-old boy. *Pediatr Dent J [Internet].* 2009;19(2):234-9. Available from: [http://dx.doi.org/10.1016/S0917-2394\(09\)70179-X](http://dx.doi.org/10.1016/S0917-2394(09)70179-X).
7. Tabrizi R, Hosseini Kordkheili MR, Jafarian M, Aghdashi F. Decompression or Marsupialization; Which Conservative Treatment is Associated with Low Recurrence Rate in Keratocystic Odontogenic Tumors? A Systematic Review. *J Dent (Shiraz, Iran).* 2019;20(3):145-51.
8. Ribeiro-Júnior O, Borba AM, Alves CAF, Gouveia MM de, Deboni MCZ, Naclério-Homem M da G. Reclassification and treatment of odontogenic keratocysts: A cohort study. *Braz Oral Res.* 2017;31:e98.
9. Titinchi F. Protocol for management of odontogenic keratocysts considering recurrence according to treatment methods. *J Korean Assoc Oral Maxillofac Surg.* 2020;46(5):358-60.
10. Ryu J, Shin TJ, Hyun H-K, Kim Y, Kim J, Kim C-C, et al. Minimally Invasive Marsupialization for Treating Odontogenic Cysts: Case Reports. *J Korean Acad Pediatr Dent.* 2017;44(2):235-42.