

1

미니 임플란트 지지형 급속 구개 확장이 만족된 비중격 및 하비도에 미치는 영향 : CBCT 연구

심호연, 하누리, 최성권, 강경화

원광대학교 치과대학 치과교정학교실

ORCID ID

Ho-Yeon Sim,  <https://orcid.org/0000-0001-6851-7768>

Nu-Ri Ha,  <https://orcid.org/0000-0001-5234-791X>

Sung-Kwon Choi,  <https://orcid.org/0000-0001-9546-9837>

Kyung-Hwa Kang,  <https://orcid.org/0000-0002-4263-1084>

ABSTRACT

Effects of mini-implant assisted rapid palatal expansion on the deviated nasal septum and inferior nasal meatus: A CBCT study

Ho-Yeon Sim, Nu-Ri Ha, Sung-Kwon Choi, Kyung-Hwa Kang

Department of Orthodontics, School of Dentistry, Wonkwang University, Iksan, Korea

Objective: The purpose of this study was to evaluate the effects of the mini-implant assisted rapid palatal expansion on the nasal septum and the inferior nasal meatus (INM) in the patients with nasal septal deviation. **Methods:** The CBCT images were taken before (T0), after (T1), and more than 5 months after (T2) MARPE in 17 patients who had NSD. According to the direction of the NSD, the concave side was set as group 1 and the convex side was set as group 2 by patient. The volume of the INM, nasal septal tortuosity ratio were calculated. Also, to evaluate 3-dimensional changes of the nasal septum, distance between C point (The junction of perpendicular plate of ethmoid bone and vomer) and three vertical planes were calculated. And distance between C point and lateral wall of nasal cavity was measured. **Results:** The total volume of the INM increased significantly after MARPE ($p < 0.001$). The distance from the C point to the vertical plane increased significantly after MARPE ($p < 0.01$). Also, there was a significant difference between the groups in the distance between the C point and the lateral wall of nasal cavity ($p < 0.001$) before and after treatment. But there was no significant difference in the increase ratio. **Conclusion:** After MARPE, the volume of INM was significantly increased. The nasal septum was more displaced to the deviated side without a significant morphological change. But the increase ratio of both group was similar.

Key words : Nasal septal deviation (NSD), Mini-implant assisted rapid palatal expansion (MARPE), Inferior nasal meatus (INM), Cone-beam computed tomography (CBCT)

Corresponding Author

kyung-Hwa Kang Professor,

Department of Orthodontics, School of Dentistry, Wonkwang University, 895 Muwang-ro, Iksan 54538, Korea.

Tel : +82-63-859-2962 / Fax : +82-303-3440-2962 / e-mail : pigtail@wku.ac.kr

I. Introduction

The nasal septal deviation (NSD) is the most common cause of nasal obstruction¹⁾. Although the prevalence of NSD depends on the race, age, and diagnostic method, a study had found that it ranges from 34% to 89.2%²⁾, and the prevalence of NSD in Korea was reported to be 22.4%³⁾.

The nasal concha is a skeletal structure in nasal cavity. The resistance of nasal airflow during inspiration is affected by the anterior part of the inferior nasal concha (INC) by two third or more⁴⁾. Among the three (superior, middle, inferior) nasal conchas, the inferior nasal concha (INC) is the most easily enlarged⁵⁾. The hypertrophy of the INC on the concave side of the NSD is called 'compensatory hypertrophy'⁶⁾. Hypertrophy of the INC significantly increases nasal airflow resistance and contributes to nasal obstruction⁷⁾. Various conservative treatments had been used to treat the nasal obstruction caused by NSD, but these treatments often failed, which required surgical intervention⁸⁾. Septoplasty is a common surgical procedure to treat NSD and is usually performed together with turbinoplasty³⁾.

Mini-implant assisted rapid palatal expansion (MARPE) was introduced to ensure the expansion of the underlying basal bone to treat the maxillary transverse deficiency^{9,10)}. MARPE is a modification of the conventional rapid palatal expansion (RPE) incorporating the mini-implant in the palatal jack screw.

Previous studies^{11~13)} showed the increase of the nasal cavity width and volume after conventional

RPE in growing children. Likewise, MARPE not only separates the mid-palatal suture but also affects the entire midfacial structures. Song et al¹⁴⁾ reported that after MARPE, zygomaticomaxillary complex including nasal structure expanded in a pyramidal shape on coronal view. And other studies^{15~18)} reported increase of nasal cavity width and volume after MARPE. These changes were well retained and it had the potential to improve nasal airflow.

Also, there were some literatures reviewing the effect of the conventional RPE and surgically assisted rapid palatal expansion (SARPE) on the nasal septum. The effect of RPE on the nasal septum in children was controversial^{19~21)}. In adults, there was no change in the nasal septum before and after SARPE^{22~24)}.

There was no literatures studied the volume changes of the inferior nasal meatus (INM) and changes in the nasal septum after MARPE in relation to NSD. Therefore, the purpose of this study was to evaluate the effect of the MARPE on INM volume and morphological changes of NS in patients with NSD.

II. Material and Methods

1. Subjects

This retrospective study was approved by the institutional review board (IRB) of the Wonkwang University Dental Hospital (WKDIRB202109-01). Data for 17 patients (11 women, 6 men) who were treated

with MARPE to correct maxillary transverse deficiency at the Wonkwang University Dental Hospital in Iksan were used for this study. The mean age of the patients was 22.3 (range, 13-29; SD, \pm 7.9) years. The inclusion criteria were: nasal septal deviation angle 5° or higher, 25 cervical vertebrae maturation index (CVMI) stage 5 or 6²⁶⁾, without previous orthodontic treatment, successful expansion of midpalatal suture, and availability of CBCT images taken before treatment (T0), immediately after expansion (T1), more than 5 months after expansion (T2) with no invasion of palatal mini-implants on interest site. The patients who had surgical intervention on the maxilla or nasal area including Le Fort I osteotomy, septoplasty etc., and craniofacial disease or systemic disease were excluded.

In this study, MARPE was carried out by maxillary skeletal expander (MSE, BioMaterials Korea, Seoul, Korea) to all patients. The body size of the MSE is 13.5 mm x 14.5 mm and is positioned in the mid-sagittal zone of the hard palate between the maxillary first molars. There are four mini-implant insertion holes and four arms to be soldered to the maxillary first molar bands. The length of the mini-implant is 11.0 mm for bicortication (cortical bone fenestrate; palatal and nasal base) which facilitates maxillary expansion. There are 2 types of MSE with difference expansion rate per pitch (0.8 mm for 4 turns, 0.8 mm for 6 turns). Both of them were used in this study.

The protocol for activating the MSE was based on the manufacturer's instruction. When the diastema was clinically recognized, the activation protocol

was modified to one or two turns per day. The mean expansion period was 2.3 (\pm 2.1) months. The expansion amount was 3.8 mm on average based on the center of resistance of the first molar (CR). And the mean retention period (T2 - T1) was 12.1 (\pm 10.4) months.

2. Measurements of variables

Cone-beam computed tomography (CBCT)

The CBCT was taken before treatment (T0), after expansion (T1), and more than 5 months retention (T2) for all patients with Alphard-3030 (ASAHI Roentgen IND, Kyoto, Japan), which was set at 80 kVp and 7.0 mA. All patients were instructed to sit upright to make a Frankfort horizontal plane (FH plane) parallel to the floor with the head fixed by chin cup and ear rod. CBCT images (voxel size 0.39 mm) were imported as digital imaging and communication in medicine (DICOM) format on INFINITT dental PACS (INFINITT healthcare Co., Ltd, Seoul, Korea).

The CBCT images were reoriented according to FH plane using the OnDemand 3D software (Cybermed, Seoul, Korea) and superimposed based on the frontal cranial base. After that, the landmarks were traced. The landmarks and planes used in this study are summarized in Table I. Figure 1 and 2 shows the landmarks used in this study.

Inferior nasal meatus (INM) volume

The INM was defined as the region anteriorly by the plane including left and right orbitale and per-

Table I. The definition of landmarks and planes used in this study

Landmark	Definition
Nasion (N)	The most antero-superior point on the nasal bone at the middle of fronto-nasal suture
Orbitale (Or)	The most inferior point of the lower border of the bony orbit
Right porion (RPo)	The most superolateral point of the external entrance to the right auditory meatus
Anterior nasal spine (ANS)	A pointed projection at the anterior extremity of the intermaxillary suture
Posterior nasal spine (PNS)	Medial end of the posterior border of the horizontal plate of palatine bone
Basion (Ba)	Most inferior point of anterior border of foramen magnum in the middle.
Crista galli (Cg)	The most superior point on the median ridge of bone that projects upward from the cribriform plate of the ethmoid bone.
C point (C)	The junction of perpendicular plate of ethmoid bone and vomer
P point (P)	The middle point of ANS and PNS
Center of resistance (CR)	The center of resistance of the maxillary first molar
Plane	Definition
Frankfort horizontal plane (FH plane)	The plane formed by bilateral Or and RPo
Midsagittal plane	The plane perpendicular to the FH plane and passing through the N
Ba-ANS-PNS plane	The plane formed by Ba, ANS, PNS
Cg-ANS-PNS plane	The plane formed by Cg, ANS, PNS

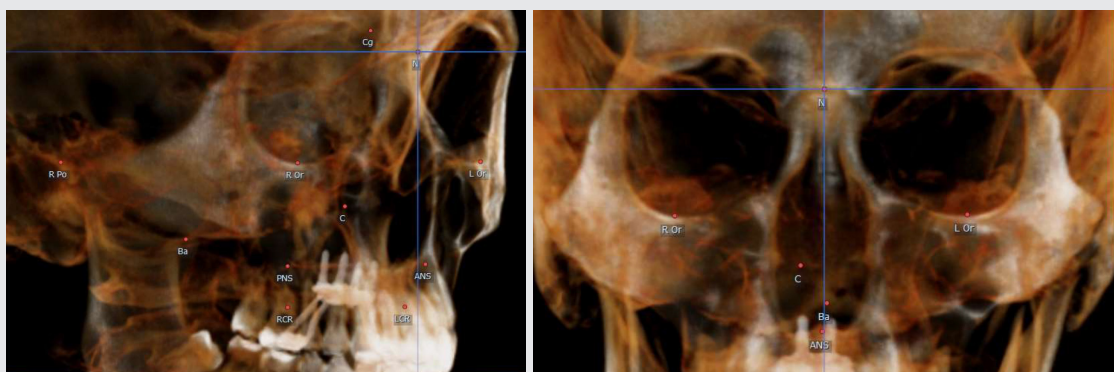


Figure 1. The landmarks used in this study.

ROr: Right orbitale, LOr: Left orbitale, RCR: Right CR, LCR: Left CR.

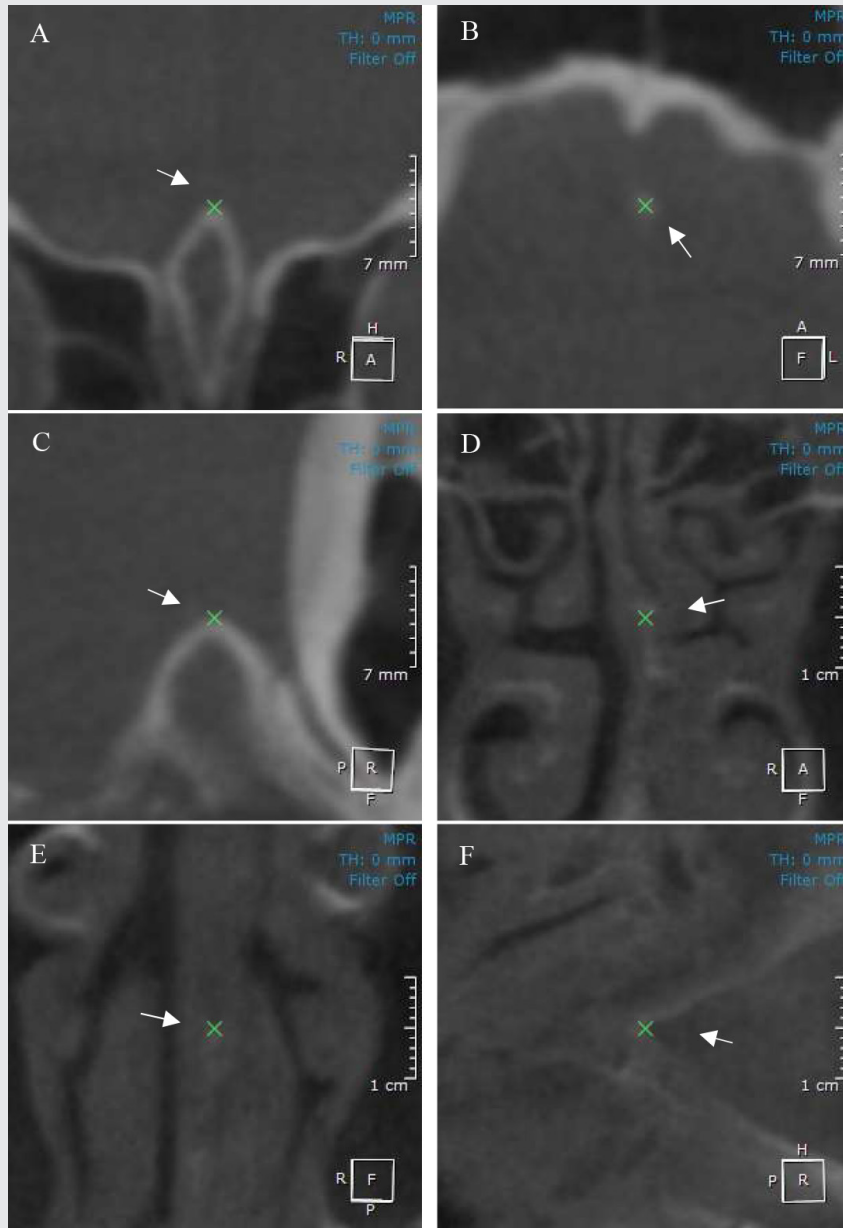


Figure 2. The coronal, axial, and sagittal views for crista galli (A, B, and C), and C point (D, E, and F). The landmarks are indicated by white arrows.

pendicular to the FH plane, posteriorly by the plane including the PNS and perpendicular to the FH plane, inferiorly by the nasal floor, superiorly by the inferior border of the bony structure of INC and medially by the center of bony structure of INC (Figure 3). Since it has a complex anatomical structure, the volume was measured using point counting method, which is based on the Cavalieri principle. Fiji, which is a distribution of the popular open-source Java-based image processing program, was used to measure the volume of the INM using the coronal view of the reconstructed CBCT images.

The interval per slice of coronal images was set to 1 mm, and a grid was formed using 'Cavalieri estimator macro' (Aleksandr Mironov, version 1.2), and the points of the INM regions were marked in each slice manually (Figure 4). The program automatically calculates the volume. The volume measurement was performed by dividing the right and left INM. Also, 2 groups were formed by direction of septal deviation by patient; group 1 was concave side of the NSD and group 2 was convex side of the NSD (Figure 4). And it was examined whether there was a difference between the groups in the volume changes.

Tortuosity ratio (TR) measurement

The tortuosity ratio (TR) was used for NSD evaluation. The TR is defined as the ratio of the actual distance between two points, including any curves encountered, divided by the distance in a straight line. Thus the formula is as follows: $TR = \text{actual length} / \text{ideal length}$. The 'Measuretool' function (Jan Neg-

gers, GitHub. Retrieved October 20, 2021.) was used in MATLAB (MathWorks R2021a, Natick, Massachusetts) for the analysis of NSD TR. Among the reconstructed coronal CBCT images, a slice including Cg and C was imported into the 'Measure tool', and the actual length and the ideal length of the nasal septum were measured to obtain TR (Figure 5).

Three dimensional (3D) nasal septum evaluation

The OnDemand 3D software was used to assess three-dimensional changes in nasal septum. The distance between C point and three vertical planes were determined. The vertical planes were the midsagittal plane, N-ANS-PNS plane and Cg-ANS-PNS plane. After expansion, ANS and PNS were spliced so T1 images were abandoned.

Linear measurement between the nasal septum (C point) and the lateral wall of nasal cavity

In the reconstructed CBCT coronal images, the linear distance between the C point and the lateral wall of the nasal cavity was measured on Ondemand 3D software. The linear measurement was performed parallel to the FH plane (Figure 6). Increase ratio was also calculated by followed formula; $\text{increase ratio} = (T1 \text{ or } T2 - T0) / T0$.

3. Statistical analysis

A power analysis using G*power (version 3.1.9.7, Franz Faul, Christian-Albrechts-Universitat, Kiel, Germany) was used to determine the sample size. The 17 subjects would be needed to provide a pow-

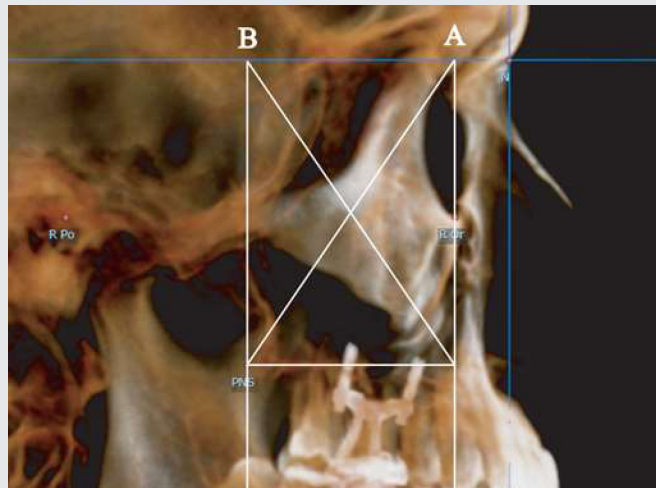


Figure 3. The anterior (A) and posterior (B) border of INM volume measurement. Measurements of the INM volume were performed in the coronal view between A and B, which is marked with an X form by white line.

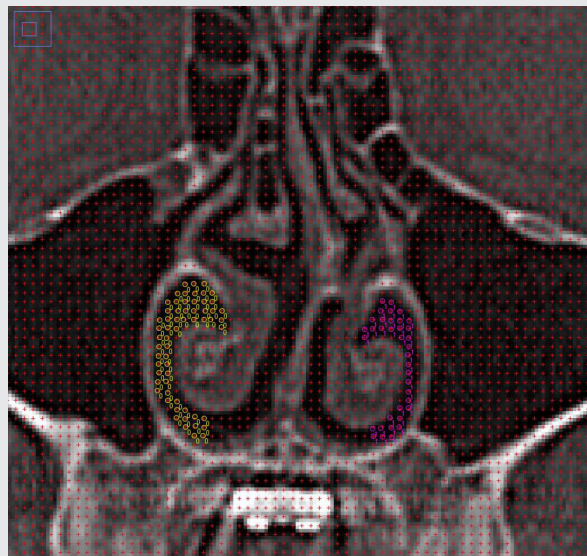


Figure 4. Point counting method for volume calculation on Cavalieri estimator macro in Fiji. The right INM was marked by yellow points. The left one was marked by purple points. In the above image, the right side was allocated to the concave group and the left side was allocated to the convex group.

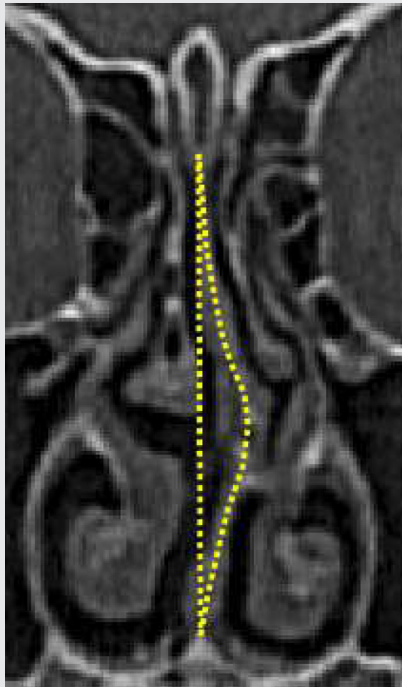


Figure 5. Measurement of tortuosity ratio in Measure tool. The thick arrow is ideal length and thin arrow is actual length.

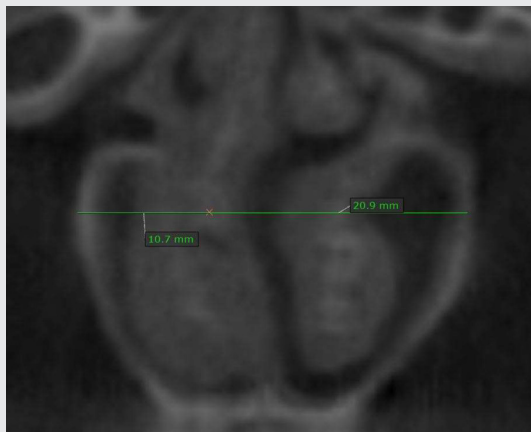


Figure 6. Linear measurement between the C point and the lateral wall of nasal cavity. C point is marked by white point.

er of 0.82 and 2-tailed α value of 0.05.

Statistical analysis were performed using SPSS version 25 (SPSS Inc., Chicago, IL, USA). All measurements, including the INM volume, TR, 3D NS evaluation, linear measurement between C point and lateral wall of nasal cavity were taken by 1 examiner (S.H.Y.). To evaluate the intraclass reliability, 6 randomly selected CBCT images were measured again after 3 weeks. The intraclass correlation coefficient was between 0.876 and 0.999, which was considered to be excellent.

To verify the normality of the data, Shapiro-Wilk test was performed. The total volume, tortuosity ratio and distance between C and vertical plane were showed normal distribution. The other variables had no normal distribution. Therefore, the non-parametric tests were mixed. The paired t test and Wilcoxon signed rank test was used to compare the changes from T0 to T1, T1 to T2, and T0 to T2. The independent t-test and the Mann-Whitney test were used for group comparison. The analysis of variance (ANOVA) was used to compare mean value of TR in coronal view of CBCT images at different time. Significance of the results were evaluated at the level of $p < 0.05$.

III. Results

The volume changes of the inferior nasal meatus between each time interval

Table II shows the means and standards deviation of total volume of INM in T0 and changes in the

volume between T0 to T1, T1 to T2, and T0 to T2. There was a significant increase in volume between T0 and T1 ($p < 0.001$), and T0 and T2 ($p < 0.001$). There was no significant difference between T1 and T2. This indicates that the volume increase has been well retained.

The intra- and intergroup comparison is summarized in Table III. Group 1 shows the significant increased in volume after MARPE (T0 to T1, $p < 0.001$; T0 to T2, $p < 0.05$). Group 2 show the significant increase in volume only in T0 to T2 ($p < 0.01$).

Tortuosity ratio (TR) changes on coronal view of CBCT images

The TR did not show a significant difference between all time intervals, so there was almost no morphological changes of the nasal septum after MARPE.

Distance changes between C point and vertical plane from T0 to T2

Table IV shows the mean distance between the three vertical planes and the C point at T0 and T2. There was no significant difference in distance in the midsagittal plane. However, a significant changes were observed in the other two planes ($p < 0.05$). This means that the C point moved toward the curved direction.

Linear measurement between the nasal septum (C point) and the lateral wall of nasal cavity

Linear measurement between C point and the lateral wall of the nasal cavity was performed for each

Table II. Changes in the volume of INM before (T0), immediately after (T1), and after more than 5 months retention (T2) of MARPE

n=17	T0	△T1-T0	△T2-T1	△T2-T0
Mean volume (mm ³)	1071.78	436.01	7.57	443.58
Standard deviation (SD)	±372.32	±352.54	±450.54	±293.36
p-value		0.000***	0.946	0.000***

The means and standard deviations of each value are presented.

Paired t-test was performed to compare the changes from T0 to T1, T1 to T2, T0 to T2.

*** $p < 0.001$.

Table III. Intra and inter group comparison of INM volume

Group	INM volume (mm ³)			p-value		
	T0	T1	T2	△T1-T0	△T2-T1	△T2-T0
1	582.55	875.25	842.12	0.000***	0.777	0.011*
	±298.78	±347.32	±420.59			
2	489.23	632.55	673.24	0.062 †	0.868 †	0.004** †
	±203.45	±245.32	±263.00			
p-value	0.052	0.06 †	0.174 †			

The means and standard deviation were presented.

Independent t-test and Mann-Whitney test † were performed for group comparison at each time.

Paired t test and Wilcoxon signed rank test † were performed to compare the changes from T0 to T1, T1 to T2, T0 to T2.

Group 1: concave side; Group 2: convex side.

* $p < 0.05$, ** $p < 0.01$, *** $p < 0.001$.

Table IV. The distance (mm) between the three vertical planes and C point at T0 and T2

Plane	T0	T2	△T2-T0	p-value
Midsagittal	2.44±1.56	2.67±1.58	0.23±0.47	0.056
Cg-ANS-PNS	2.28±1.64	2.50±1.70	0.21±0.28	0.006**
N-ANS-PNS	2.40±1.56	2.64±1.63	0.23±0.26	0.002**

The distances were measured in mm.

The means and standard deviations were presented.

Paired t-test was performed for comparison of the distance value between T2 and T0.

** $p < 0.01$.

group (Table V). The distance increased significantly after MARPE (T0-T1, T0-T2, $p < 0.001$), and Group 1 increased significantly more than group 2 ($p < 0.001$). However, when the increase ratio was compared, there was no significant difference between the groups (Table VI).

IV. Discussion

In this study, we investigated the change of the INM volume and the nasal septal deviation after MARPE in a patient with a deviated nasal septum. In the coronal view of the reorientated CBCT images, the nasal septal deviation angle (between the midsagittal plane and the line connecting the most superior point of the nasal septum and the most prominent point of the nasal septum) was more than 5 degrees for inclusion criteria. This angle was determined by Periyasamy et al²⁵. It is the minimum value (mild) in which nasal septal deviation exists. Classification based on the severity of the septal deviation was not performed due to a lack of samples, which is one of the limitations of this study. Further study is needed to compare the changes according to the severity of NSD.

Park & Yu²⁶ suggested that the growth of the length of the maxilla and length of the nasal cavity floor increased up to CVMI 2 in boy and up to CVMI 4 in girl. So, in this study, patients sample was limited to CVMI 5 or 6.

In the literatures which is studied the structure of the inferior nasal concha (INC) in a deviated nasal

septum, it was reported that the mucous membrane and the bony structure of the inferior nasal concha were larger on the concave side (opposite to deviation). Orhan et al⁸. reported that in the patients with NSD, the compensatory hypertrophy of INC in concave side is caused by both hypertrophy of mucous membrane and INC bone. Shetty et al²⁷. also suggested that INC width was larger in the concave side. This may lead to nasal obstruction.

The conservative treatments had been used to treat the nasal obstruction caused by NSD, including intranasal sprays, antihistamines, and mast cell stabilizers. However, these conservative treatments are limited in reducing the volume of the nasal concha, and generally result in a slight improvement, and the treatment often fails, which requires surgical intervention like septoplasty, turbinoplasty⁸. Kim et al²⁸. reported that the nasal cavity volume was increased from 17.48 cm³ to 24.08 cm³ measured by acoustic rhinometry after septoplasty and turbinoplasty. This represents a volume increase approximately 37.75%.

The total volume of the left and right INM showed a significant increase after MARPE, and the increased volume was also well retained (Table II). Skeletal expansion by MARPE appeared in a pyramidal shape, and the amount of expansion decreased as it moves away from the palate^{14,15}. In the nasal structure, the INM is located inferior and largest structure, it can be said that it mainly contributes to the increase of nasal volume. The INM volume increased by 41.47% (T2-T0) in this study. The MARPE, like surgical intervention, showed an increase in INM volume.

This expansion on the nasal cavity is also known

Table V. The distance between C point and lateral wall of nasal cavity

Group	Distance (mm)			p-value		
	T0	T1	T2	$\Delta T1-T0$	$\Delta T2-T1$	$\Delta T2-T0$
1	15.62±3.05	16.71±3.13	16.79±3.17	0.000***	0.905‡	0.000***‡
2	12.24±2.10	12.97±2.22	13.02±2.33	0.000***‡	0.672‡	0.000***
p-value	0.000***	0.000***	0.000***			

The means and standard deviation were presented.

The Mann-Whitney test was performed for group comparison at each time.

The Paired t test and Wilcoxon signed rank test ‡ were performed to compare the changes from T0 to T1, T1 to T2, T0 to T2.

Group 1: concave side ; Group 2: convex side.

*** $p < 0.001$.

Table VI. The increase ratio of distance between C point and lateral wall of nasal cavity

Group	Increase ratio (%)	
	T0-T1	T0-T2
1	7.34±3.91	7.73±4.35
2	6.05±3.62	6.32±3.54
p-value	0.908	0.413

The means and standard deviations were presented.

The independent t-test and Mann-Whitney test were performed for group comparison.

Group 1: concave side ; Group 2: convex side.

in several other literatures. Kim et al¹⁷⁾. reported that nasal volume and cross-sectional area increased after MARPE treatment and maintained after 1 year. Shivam et al¹⁸⁾. also reported an increase in nasal volume after MARPE. However, there was no literature comparing the volume changes of the each side of the nasal cavity. In this study, groups were divided according to the NSD by patients. The INM volume shows significant increase in both groups, but there is no significant difference between groups. This may be due to a lack of samples for each group, but a more probable reason was the fluidity of the na-

sal mucosa called the 'Nasal cycle'. The nasal cycle is the spontaneous congestion and decongestion of the left and right nasal mucosa during the day. When the congestion occurs on the one side than the decongestion occurs on the other side, but the total volume of the nasal cavity is constant²⁹⁾. Therefore, one of the limitations of this study is that there was no control for nasal mucosa when taking the CBCT. Further study with intervention in the nasal mucosa is needed for accurate intergroup comparison.

To the best of our knowledge, this study is the first study to examine the effect of MARPE on the

nasal septum. There was a literature reviewing the effect of conventional RPE and SARPE on the nasal septum. About SARPE, Jensen & Rodrigo-Domingo²²⁾ showed that there was no difference in the nasal septum measured by septal deviation angle between the group with and without releasing the septum. Reinbacher et al²³⁾ showed that there was no change in the nasal septum before and after expansion in the same way. Dias et al²⁴⁾ performed linear measurements from the zygomatic arch to the nasal septum, and showed no change in septum and bilateral symmetry. However, the patients in these literatures did not had a NSD, so the results of these studies may differ from ours.

About RPE, the results of the literature were controversial. Aziz et al¹⁹⁾ used CBCT images and tortuosity ratio for NSD evaluation after maxillary expansion in adolescent patients. They said that there was no effect on NSD after RPE treatment. Gokce et al²⁰⁾ also used CBCT images and tortuosity ratio for evaluation of RPE effect on NSD. They said that there was a significant difference in TR value after expansion. Maspero et al²¹⁾ said that RME treatment made nasal septum length increased and reduced septum deviation, so RME had a potentially positive effect on the nasal septum deviation during childhood.

We also used TR to determine whether there was a morphological change in the nasal septum itself. The actual length and ideal length were therefore measured from each nasal septum rather than from the plane or reference line. TR showed no significant change before treatment, after expansion, and

after more than 5 months of retention. This is consistent with Aziz et al¹⁹⁾. However, we found that the C point, which is one point of the nasal septum, moved significantly toward the curved side of nasal septum from the vertical planes (Table IV). But the amount of displacement was very small with an average of 0.2 mm, and the increase ratio in the distance between C point and the lateral wall of nasal cavity did not show a significant difference between groups (Table VI), this change may not be clinically significant.

The reason for this change can be found in the literature that studied correlation between the deviation of the nasal septum and the shape of the nasal floor. Koo et al³⁰⁾ reported that nasal floor deviation was more prominent in the group with NSD than in the group without NSD (Figure 7). Because of this, it can be assumed that the base of the septum is closer to the deviated side, so the base moves to the deviated side as the midpalatal suture widens during MARPE. However, since the change was observed only at one point of the nasal septum, additional study is needed to investigate the three-dimensional change.

Although this study focuses on the skeletal effect of MARPE in the nasal cavity, the skeletal changes in the nasal area also affect on soft tissue. Lee et al³¹⁾ measured the changes in nasal soft tissue before and after MARPE through a facial scan. It showed that the nose was widened and changed forward and downward. Sara et al³²⁾ showed that soft tissue changes were maintained even after expansion. Since these soft tissue changes can be unfavorable

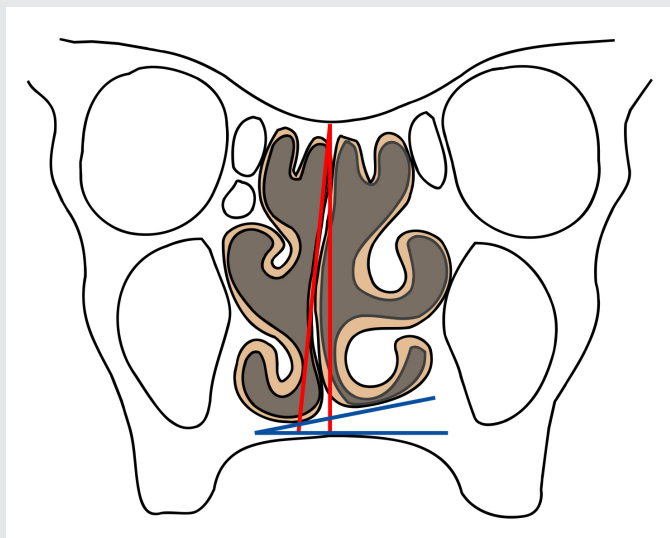


Figure 7. Illustration of nasal septal deviation and nasal floor deviation. Nasal septal deviation angle was formed by red lines, nasal floor angle was formed by blue lines.

for some patients, it will be necessary to consider it before MARPE.

V. Conclusions

In this study, we investigated the effect of MARPE on the inferior nasal meatus and nasal septum in nasal septal deviation. After MARPE, the inferior nasal meatus was significantly increased and this increase was retained well. The nasal septum was more displaced to the deviated side without a signif-

icant morphological change measured by tortuosity ratio. However, this displacement is not clinically significant because the amount of displacement was very small and there was no significant difference in the increase ratio in the distance between the lateral wall of the nasal cavity and the nasal septum. So, MARPE effectively increases the volume of the inferior nasal meatus without significantly affecting the deviated nasal septum.

참고 문헌

1. Han SJ, Oh H, Park YK, Min SG, Shin JH, Lee WW, Kim HJ. Should the High Septal Deviation be Corrected to Improve Nasal Obstruction During Septal Surgery? *Journal of Rhinology* 2016;23(2):85.
2. Mladina R, Cujic E, Subaric M, Vukovic K. Nasal septal deformities in ear, nose, and throat patients: an international study. *American Journal Otolaryngology* 2008;29(2):75-82.
3. Min YG, Jung HW, Kim CS. Prevalence study of nasal septal deformities in Korea: results of a nation-wide survey. *Rhinology* 1995;33(2):61-5.
4. Haight JS, Cole P. The site and function of the nasal valve. *Laryngoscope* 1983;93(01):49-55.
5. Lai WW, Corey JP. The objective assessment of nasal patency. *Ear Nose Throat Journal* 1993;72(06):395-396, 399-400.
6. Berger G, Hammel I, Berger R. Histopathology of the turbinate with compensatory hypertrophy in patients with deviated nasal septum. *Laryngoscope* 2000;110:2100-2105.
7. Mrig S, Agarwal AK, Passey JC. Preoperative Computed Tomographic Evaluation of Inferior Nasal Concha Hypertrophy and its Role in Deciding Surgical Treatment Modality in Patients with Deviated Nasal Septum. *International Journal of Morphology* 2009;27(2):503-506.
8. Orhan I, Aydin S, Ormeci T, Yilmaz F. A Radiological Analysis of Inferior Turbinate in Patients with Deviated Nasal Septum by Using Computed Tomography. *American Journal of Rhinology & Allergy* 2014;28(1):e68-e72.
9. Lee KJ, Park YC, Park JY, Hwang WS. Miniscrew-assisted nonsurgical palatal expansion before orthognathic surgery for a patient with severe mandibular prognathism. *American Journal of Orthodontics and Dentofacial Orthopedics* 2010;137(6):830-839.
10. Moon W, Machado A. Interview with Won Moon. *Dental Press Journal of Orthodontics* 2013;18(3):12-28.
11. Matsumoto MAN, Itikawa CE, Pereira Valera FC, Faria G, AnselmoLima WT. Long-Term Effects of Rapid Maxillary Expansion on Nasal Area and Nasal Airway Resistance. *American Journal of Rhinology & Allergy* 2010;24(2): 161-165.
12. Christie KF, Boucher N, Chung CH. Effects of bonded rapid palatal expansion on the transverse dimensions of the maxilla: A cone-beam computed tomography study. *American Journal of Orthodontics and Dentofacial Orthopedics* 2010;137(4):S79-S85.
13. Palaisa J, Ngan P, Martin C, Razmus T. Use of conventional tomography to evaluate changes in the nasal cavity with rapid palatal expansion. *American Journal of Orthodontics and Dentofacial Orthopedics* 2007;132(4):458-466.
14. Song KT, Park JH, Moon W, Chae JM, Kang KH. Three-dimensional changes of the zygomaticomaxillary complex after mini-implant assisted rapid maxillary expansion. *American Journal of Orthodontics and Dentofacial Orthopedics* 2019;156(5):653-662.
15. Jesus AS, Oliveira CB, Murata WH, Gonçalves ES, Pereira-Filho VA, SantosPinto A, Nasomaxillary effects of miniscrew-assisted rapid palatal expansion and two surgically assisted rapid palatal expansion approaches. *International Journal of Oral & Maxillofacial Surgery* 2021;50(8):1059-1068.
16. Lim HM, Park YC, Lee KJ, Kim KH, Choi YJ. Stability of dental, alveolar, and skeletal changes after miniscrew-assisted rapid palatal expansion. *The Korean Journal of Orthodontics* 2017;47(5):313-322.
17. Kim SY, Park YC, Lee KJ, Lintermann A, Han SS, Yu HS, Choi YJ. Assessment of changes in the nasal airway after nonsurgical miniscrew-assisted rapid maxillary expansion in young adults. *The Angle Orthodontist* 2018;88(4):435-441.
18. Shivam Mehta, Dennis Wang, Chia-Ling Kuo, JinjianMu, Manuel LagravereVich, Veerasathpurush Allareddy, Aditya Tadina, Sumit Yadav. Long-term effects of mini-screw-assisted rapid palatal expansion on airway: A three-dimensional cone-beam computed tomography study. *The Angle Orthodontist* 2021;91(2):195-205.
19. Aziz T, Wheatley FC, Ansari K, Lagravere M, Major M, FloresMir C. Nasal septum changes in adolescent patients treated with rapid maxillary expansion. *Dental Press Journal of Orthodontics* 2016;21(1):47-53.
20. Gokce G, Veli I, Yuce YK, Isler Y. Efficiency Evaluation of Rapid Maxillary Expansion Treatment on Nasal Septal Deviation using Tortuosity Ratio from Cone-Beam Computer Tomography Images. *Computer Methods and Programs in Biomedicine* 2020;188:105260.
21. Maspero C, Galbiati G, Del Rosso E, Farronato M, Giannini L. RME: effects on the nasal septum. A CBCT evaluation. *European Journal of Paediatric Dentistry* 2019;20(2):123-126.
22. Jensen T, Rodrigo-Domingo M. Surgically assisted rapid maxillary expansion (SARME) with or without intraoperative releasing of the nasal septum. *Oral Surgery, Oral Medicine, Oral Pathology and Oral Radiology* 2017;123(3): e85-e90.
23. Reinbacher KE, Wallner J, Pau M, Feichtinger M, Kärcher H, Quehenberger F, Zemmann W. Surgically assisted rapid maxillary expansion: feasibility of not releasing the nasal septum. *International Journal of Oral and Maxillofacial Surgery*

참고 문헌

- 2013;42(3):321-325.
24. Dias RR, Takeshita WM, Sverzut AT, Trivellato AE, Sverzut CE. Linear analysis of the nasal septum in patients treated with surgically assisted rapid maxillary expansion. *American Journal of Orthodontics and Dentofacial Orthopedics* 2021;159(1):71-80.
25. Periyasamy V, Bhat S, Sree Ram MN. Classification of Naso Septal Deviation Angle and its Clinical Implications: A CT Scan Imaging Study of Palakkad Population, India. *Indian Journal of Otolaryngology Head & Neck Surgery* 2019; Nov:71(Suppl 3):2004-2010.
26. Park SH, Yu HS. A comparison study of the effects of hypertrophied adenoid tissue on craniofacial morphology. *Korean Journal of Orthodontics* 2002;32(1): 19-31.
27. Shetty SR, Al Bayatti SW, AlRawi NH, Marei H, Reddy S, Abdelmagyd HA, Mathew A. Analysis of inferior nasal turbinate width and concha bullosa in subjects with nasal septum deviation: a cone beam tomography study. *BMC Oral Health* 2021;21(1):206.
28. Kim YD, Suh BS, Song SY, Treatment Outcomes of Septoplasty with Turbinate Surgery in Septal Deviation with Chronic Hypertrophic Rhinitis. *Yeungnam University Journal of Medicine* 2001;8(2):199-207.
29. Pendolino AL, Scarpa B, Ottaviano G. Relationship Between Nasal Cycle, Nasal Symptoms and Nasal Cytology. *American Journal of Rhinology & Allergy* 2019;33(6):644-649.
30. Koo SK, Park GH, Koh TK, Lee HB, Ji CL. Relationships of Direction and Degree of Nasal Septum Deviation with Nasal Floor Morphology. *Journal of Clinical Otolaryngology Head & Neck Surgery* 2020;31(2):181-187.
31. Lee SR, Lee JW, Chung DH, Lee SM. Short-term impact of microimplant-assisted rapid palatal expansion on the nasal soft tissues in adults: A three-dimensional stereophotogrammetry study. *Korean Journal of Orthodontics* 2020 Mar;50(2):75-85.
32. Abedini S, Elkenawy I, Kim E, Moon W. Three-dimensional soft tissue analysis of the face following micro-implant-supported maxillary skeletal expansion. *Progress in Orthodontics* 2018 Nov 19;19(1):46.