

CASE REPORT

<https://doi.org/10.22974/jkda.2023.61.6.001>

투고일 : 2023. 1. 26

심사일 : 2023. 1. 31

게재확정일 : 2023. 4. 4

1

Case report of peritonsillar space abscess misdiagnosed as parapharyngeal space abscess

최문기

원광대학교 치과대학 구강악안면외과학교실

ORCID ID

Moon Gi Choi,  <https://orcid.org/0000-0003-3502-7652>

ABSTRACT

Case report of peritonsillar space abscess misdiagnosed as parapharyngeal space abscess

Moon Gi Choi

Department of Oral and Maxillofacial Surgery, College of Dentistry, Wonkwang University

Peritonsillar abscess, the most commonly occurring deep infection of the neck, involves formation of pus in the peritonsillar space.

Although abscess of the peritonsillar space and abscess of the parapharyngeal space occur in different anatomical spaces, the clinical symptoms are similar, making it difficult to distinguish between the two diseases. Delay of treatment can result in transfer of infection from one space to another.

Improper treatment or delayed treatment of a peritonsillar abscess can lead to serious complications such as an abscess of the parapharyngeal space, necrotizing fasciitis, internal jugular vein thrombosis, and descending mediastinitis. These conditions can be life-threatening due to airway obstruction or sepsis.

Drainage, fluid therapy, and antibiotic therapy provide the basis for treatment of peritonsillar abscess. Airway management is the most urgent priority. Airway obstruction can occur immediately during a deep infection of the neck space and is a common cause of death rather than sepsis. Immediate airway management is required in cases where there is evidence that airway obstruction is imminent. Transoral incision and drainage is the most commonly used method for drainage of peritonsillar abscesses. However, transoral incision and drainage may not be sufficient and use of a transcervical approach may be necessary.

The author reports on a case of an abscess of the peritonsillar space misdiagnosed as an abscess of the parapharyngeal space and on issues that should be considered with regard to abscess of the peritonsillar space.

Key words : Peritonsillar space abscess, parapharyngeal space abscess, deep neck infection.

Corresponding Author

Moon Gi Choi, DDS, MS, PhD, Professor
Department of Oral and Maxillofacial Surgery, College of Dentistry, Wonkwang University,
460 Iksan-daero, Iksan 54538, Korea
TEL : +82-63-850-6642 / FAX : +82-63-859-4002 / E-mail : omschoi@wku.ac.kr

ACKNOWLEDGEMENT This paper was supported by Wonkwang University in 2021.

I. Introduction

An abscess of the peritonsillar space, the most commonly occurring deep infection of the neck, involves formation of pus in the peritonsillar space^{1,2,3}. It occurs in approximately one in every 6,000 to 10,000 people each year⁴. It occurs as a result of purulent complications of tonsillitis^{2,3,5}.

The symptoms of an abscess of the peritonsillar space and an abscess of the parapharyngeal space are similar, thus distinguishing them according to symptoms alone is difficult. These two diseases occur in different anatomical spaces. Delay of treatment can result in transfer of the infection from one space to another.

The parapharyngeal space is a cone-shaped space located in the lateral cervical region. The upper boundary is the base of the skull, and the lower boundary is the hyoid bone; the anterior boundary is the pterygomandibular raphe, the posterior boundary is the prevertebral fascia, and the medial boundary is the superficial layer of the deep cervical fascia over the medial pterygoid muscle, and the lateral boundary is the deep cervical fascia lateral to the superior pharyngeal constrictor muscle and the deep boundary is the deep surface of the parotid gland and the mandible^{6,7}.

The peritonsillar space, a potential space filled with loose connective tissue, is located between the palatine tonsil and the superior constrictor muscle. The anterior boundary is the anterior tonsillar pillar, and the posterior boundary is the posterior tonsillar pillar. The superior boundary is the torus tubers and

the inferior boundary is the pyriform sinus^{6,7,8}.

Improper treatment or delayed treatment of an abscess of the peritonsillar space can lead to severe complications⁵. Serious complications include abscess of the parapharyngeal space, necrotizing fasciitis, internal jugular thrombosis, and descending mediastinitis⁵. Airway obstruction and mediastinitis can lead to death in patients with these complications^{1,3}. An overall mortality rate for abscess of the peritonsillar space as high as 10% has been reported⁹.

An abscess of the peritonsillar space spreads through the bloodstream, lymphatic flow, and by direct propagation into the parapharyngeal space^{6,7}. Direct propagation occurs through the superior pharyngeal constrictor muscle¹⁰. Spread of abscesses from the tonsils to the lateral pharyngeal space can lead to fatal complications. These include severe toxicity, severe trismus, and upper pharyngeal edema⁹. In addition to an abscess of the parapharyngeal space, development into an abscess of the retropharyngeal space, buccal space, masticatory spaces, danger space, prevertebral space, and carotid space can also occur¹¹.

II. Case Report

On 24, July 2022, a 54-year-old male patient presented to the emergency room of Wonkwang University hospital complaining of a sore throat on the left side of his neck. The pain worsened when his mouth was opened. The patient said that he had ex-

CASE REPORT

perceived a toothache in his molars a few days ago and developed a sore throat after that. He received a prescription for medication from a private otolaryngologist, however, the symptoms did not improve. The patient was referred to the department of oral and maxillofacial surgery for a suspected dental infection. His vital signs were as follows: body temperature was 38.2°C, respiratory rate was 16 beats/min, heart rate was 96 beats/min, and blood pressure was 120/80 mmHg. Physical examination detected a slight trismus, severe cervical lymphadenopathy on the left side of the neck, no edema of the soft palate, and displacement of the uvula to the right side. No cough or sputum was detected, however, the patient showed dysphagia.

No dental caries or periodontal disease was observed in the left mandibular molars, however,

sensitivity to percussion was detected on the left mandibular first molar. The patient had no remarkable medical history other than frequent tonsillitis. Since childhood, he has often received treatment for tonsillitis by an otolaryngologist. The results of laboratory studies showed a normal hemoglobin level of 14.6 g/dL, an elevated white blood cell count of 17.42×10^9 /L, an elevated neutrophil count of 12.08×10^9 /L, an elevated neutrophil % of 69.3%, an elevated erythrocyte sedimentation rate (ESR) of 28mm/Hr., and an elevated C reactive protein (CRP) level of 27.98 mg/L.

An abscess cavity located in the left pharynx and a slight cellulitic change of fat in the left parapharyngeal space were observed on a CT of the neck taken in the emergency room. It was diagnosed as an abscess of the pharyngeal space (Fig. 1).

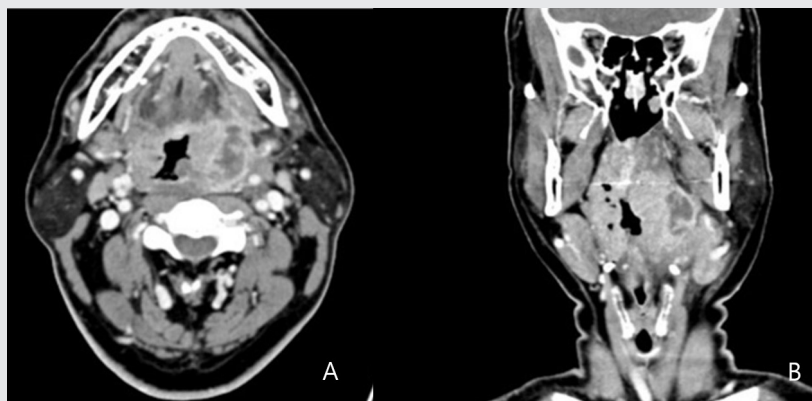


Fig. 1 A. Axial view of CT. An edema is observed in the left pharynx. The central part of the edema shows low density, and the peripheral part shows peripheral enhancement, which is considered an abscess. B. Coronal view of CT. A slight cellulitic change of fat in the parapharyngeal space is observed.

CASE REPORT

Intravenous sultamox (1,500mg three times per day), full gram (1,200mg two times per day), and amikacin (1,000mg two times per day) was administered as an empirical antibiotic.

I&D was performed on the left parapharyngeal space under general anesthesia on 25, July 2022. A submandibular approach was used for the approach to the parapharyngeal space. Contrary to expectations, the pus had not drained. The decision was made to insert a drainage tube and observe the change in symptoms. Endotracheal tubes were not extubated in order to prevent airway obstruction. The results of laboratory studies showed an elevated white blood cell count of $17.48 \times 10^9 /L$, an elevated neutrophil count of $14.65 \times 10^9 /L$, an elevated neu-

trophil % of 81.8%, an elevated erythrocyte sedimentation rate (ESR) of 47mm/Hr., and an elevated level of C reactive protein (CRP) of 76.29 mg/L. The patient's condition did not show improvement. An emergency CT of the neck was taken that afternoon. On the CT, the drainage tube was not able to enter the abscess cavity and was located in the parapharyngeal space. The abscess cavity located in the pharynx had increased further. No collection of pus was observed in the parapharyngeal space (Fig. 2).

The diagnosis was changed to an abscess of the peritonsillar space by referring to the initial CT, postoperative CT, and surgical findings. It was determined that the location where the abscess cavity had formed on CT was peritonsillar space, not para-

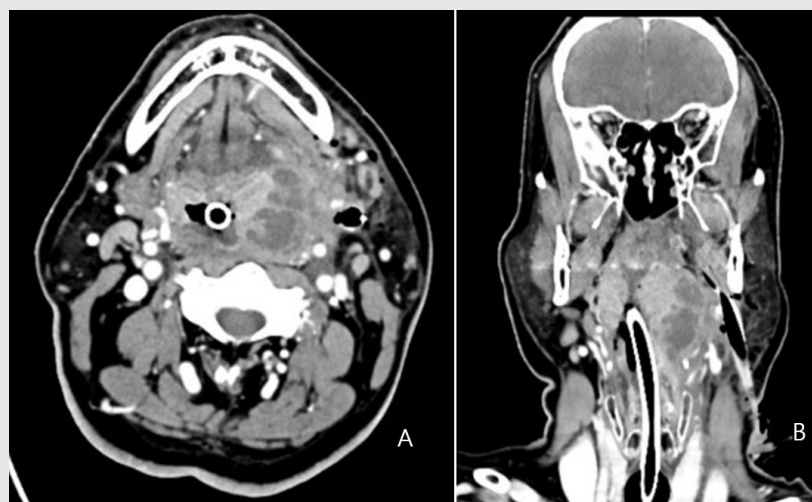


Fig. 2 A. Axial view of CT. An increased edema and abscess cavity in the left pharynx. The drainage tube does not enter the abscess cavity. B. Coronal view of CT. The drainage tube only enters the parapharyngeal space and there is no pus collection in the parapharyngeal space.

CASE REPORT

pharyngeal space.

An emergency incision and drainage of the abscess of the peritonsillar space was performed again under general anesthesia on the afternoon of 25, July 2022. The approach to the peritonsillar space was similar to the approach used for the parapharyngeal space. Because the author lacked experience with abscess of the peritonsillar space and the surgical field was narrow, the submandibular gland was removed in order to widen the surgical field. Using the space occupied by the submandibular gland, an approach was made to the superior pharyngeal constrictor muscle. After the superior pharyngeal constrictor muscle had been met, blunt dissection proceeded toward the tonsils by tearing the superior

pharyngeal constrictor muscle with a finger. Opening of the superior pharyngeal constrictor muscle resulted in discharge of a large amount of pus. A pus culture and antibiotic sensitivity testing were performed. Drainage tubes were inserted into the parapharyngeal space and the peritonsillar space at the same time. The endotracheal tube was not extubated in order to prevent airway obstruction. The patient was able to breathe comfortably through the endotracheal tube and the symptoms improved.

On 26, July 2022, the drainage tubes were well inserted into the parapharyngeal space and the peritonsillar space, however, the airway was almost obstructed due to edema and tonsillitis on both sides on CT (Fig. 3).

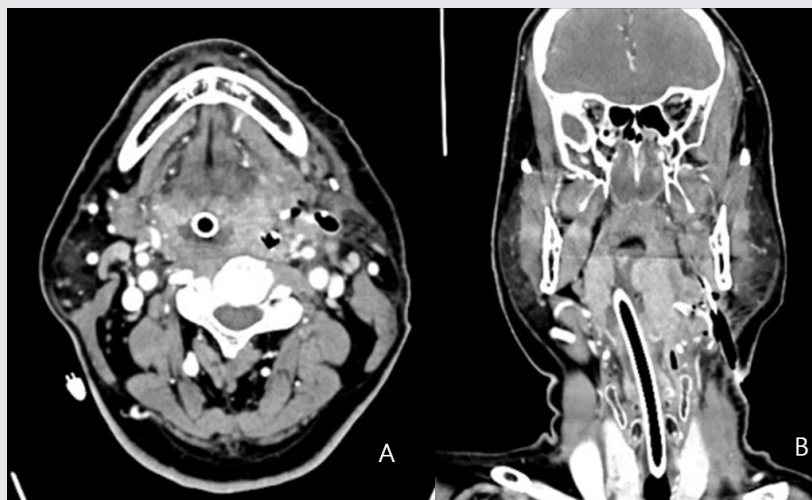


Fig. 3 A. Axial view of CT, B. Coronal view of CT. CT shows that the drainage tubes are well inserted into the parapharyngeal space and peritonsillar space. The amount of peritonsillar abscess has decreased. Persistent tonsillitis is apparent on both sides. The airway of the oropharynx has almost disappeared due to edema.

CASE REPORT

In the late afternoon, the patient suddenly complained of dyspnea. The patient was not able to manage the oropharyngeal stagnant secretion and it was determined that the endotracheal tube was being blocked by secretion. Performance of tube suction and oropharyngeal suction resulted in temporary improvement of breathing, and the patient wanted to suction frequently. The patient expressed a sense of urgency that he could die of suffocation. The patient was in severe distress with a cold sweat. Heart rate increased to 86 beats per minute and the oxygen saturation decreased by 93%.

The cuff was released in order to help the patient breathe, however, the effect was maintained for less than 10 minutes. The decision was made to perform a tracheotomy in order to prepare for the

worst situation where the airway could no longer be maintained using the tube, and the airway would be closed upon extubation. With assistance from an otolaryngologist, a tracheostomy was performed immediately under local anesthesia. After performance of the tracheostomy, the heart rate dropped to 66 beats per minute and oxygen saturation increased to 98% and the patient regained stability.

On 31, July 2022, the result of a pus culture indicated detection of beta-hemolytic streptococcus (*Streptococcus constellatus*), and the results of antibiotic sensitivity testing showed that penicillin, cefotaxime, ceftriaxone, and vancomycin were sensitive. The patient complained about receiving multiple antibiotic injections, therefore, the antibiotics were replaced with prepenem (500mg two times per day).

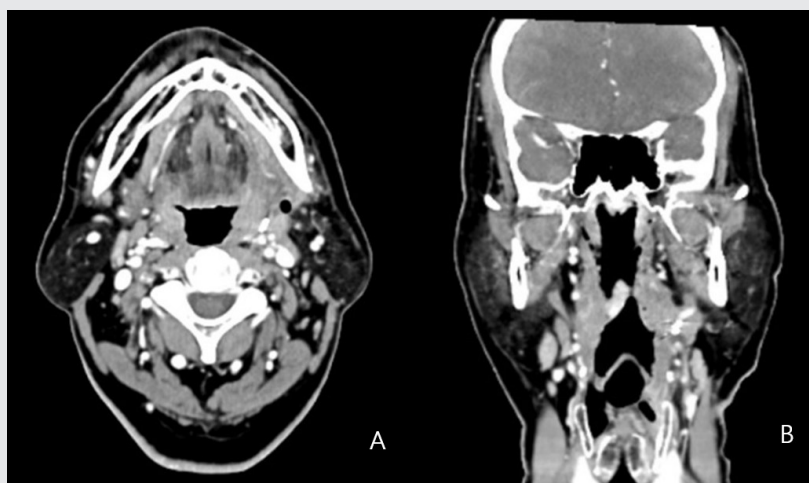


Fig. 4 A. Axial view of CT, B. Coronal view of CT. The peritonsillar abscess and tonsillitis on both sides are resolved and the airway is well maintained.

Although the patient was doing well, an unexpected fever developed on August 3, 2022. His vital signs were as follows: body temperature was 39°C, respiratory rate was 18 beats/min, heart rate was 86 beats/min, and blood pressure was 130/80 mmHg. The results of laboratory studies showed a hemoglobin level of 13.5 g/dL, a white blood cell count of 6.13×10^9 /L, an erythrocyte sedimentation rate (ESR) of 50mm/Hr., and a C reactive protein (CRP) level of 12.33mg/L. On 4 August 2022, infection with COVID-19 was confirmed and the patient was quarantined. Except fever, there were no specific findings based on the patient's symptoms. Injection of Remdesivir (100mg one time per day), an antiviral drug, was administered for five days. The patient was released from quarantine on 11 August 2022. At that time, the patient's body temperature had normalized at 37.3 °C. The antibiotic was replaced with Rukasyn (1g four times per day) on 9 August 2022.

The tracheostomy tube was removed on 11 August 2022. The airway was well maintained and swelling of the pharynx had disappeared on CT (Fig. 4).

The patient was discharged from the hospital on August 12, 2022, the day after the quarantine was lifted. Laboratory studies performed at the time of discharge showed a white blood cell count of 3.70×10^9 /L, a neutrophil count of 1.34×10^9 /L, a neutrophil % of 36.2%, an erythrocyte sedimentation rate (ESR) of 40mm/Hr., and the level of C reactive protein (CRP) was 2.43 mg/L. Normalizing of all test numbers was observed.

III. Discussion

An abscess of the peritonsillar space is associated with tonsillitis and may be a suppurative complication of tonsillitis^{1,2,3,5}. Tonsillitis can result from infection by viruses and bacteria. EBV (Epstein-Barr virus), Adenovirus, Enteroviruses, Parainfluenza virus, influenza virus in viruses, and Group A beta-hemolytic streptococci in bacteria are the most common agents. It involves erythema of the tonsil, exudates from the tonsil, edema of the uvula, and cervical lymphadenopathy in the acute phase. Symptoms of tonsillitis include sore throat, fever, fatigue, neck pain, voice change, and dysphagia¹¹. Tonsillitis is generally not a cause of trismus, however, in cases of progression to a deep infection, such as peritonsillar abscess and abscess of the parapharyngeal space, severe trismus can occur¹¹. Trismus in peritonsillar abscesses and parapharyngeal space abscesses is caused by inflammatory irritation of the superior pharyngeal constrictor muscle or pterygoid muscles¹. If complications of tonsillitis are not confirmed, it could result in serious sequelae including peritonsillar abscess¹¹. The symptoms of peritonsillar abscess include sore throat, dysphagia, odynophagia, malaise, trismus, fever, hot-potato voice, and cervical lymphadenopathy. Bulging of the soft palate and superior tonsillar pole and deviation of the uvula can be observed¹. Serious symptoms can occur when the peritonsillar abscess reaches the parapharyngeal space. These include severe toxicity, severe trismus, and upper pharyngeal edema⁶.

CT with contrast medium should be taken when

CASE REPORT

performance of a physical examination is difficult due to trismus or when progression of a peritonsillar abscess to an abscess of deep neck space is suspected^{12,13}. Performance of a CT enables easy interpretation and appropriate treatment planning. Performance of a CT without contrast medium can result in administration of inappropriate treatment due to inaccurate interpretation. This situation can result in death for patients¹⁰. Observation of a homogeneous soft tissue swelling, but no clear abscess cavity in the peritonsillar space on CT can lead to a diagnosis of tonsillitis¹². Observation of a contrast enhancement of the surrounding peritonsillar space can result in a diagnosis of an abscess of the peritonsillar space¹³. Observation of extension of a peritonsillar abscess into an abscess of the parapharyngeal space is a peripheral enhancement outside the superior pharyngeal constrictor muscle². When an abscess of the peritonsillar space invades the parapharyngeal space, the fat-filled parapharyngeal space may disappear and/or show lateral displacement on CT¹⁴.

Basic treatment for a peritonsillar abscess includes fluid therapy, antibiotic therapy, and incision and drainage¹. However, airway management is the most urgent priority. Airway obstruction can occur immediately in an infection of the deep neck space, and is a common cause of death rather than sepsis. Airway management should be applied immediately if there is any evidence that airway obstruction is imminent¹⁵.

Methods of securing the airway include observation, endotracheal intubation, and tracheostomy¹⁵.

The problem with observation is that predicting the timing of airway obstruction is difficult, and it is not recommended under suspicious circumstances. Use of endotracheal intubation provides the advantage of avoiding complications from surgery and airways can be rapidly secured using a non-surgical method. However, endotracheal intubation may not be possible in cases involving severe edema of the upper airway, airway displacement, subglottic stenosis, or severe trismus. Endotracheal intubation requires mechanical ventilation, sedation therapy, and restraint of a patient. Mechanical ventilation is required for prevention of clogging of the inner surface of the endotracheal tube and sedation therapy is necessary to provide comfort to the patient. Sedation and restraint of the patient are necessary for prevention of self-extubation. The risks of sedation therapy should be considered. The expectation that maintaining an endotracheal tube in cases of airway obstruction will lead to opening of the airway in a few days is unrealistic. Conversely, tracheostomy is a reliable technique for securing the airway, which enables bypass of upper airway obstruction without sedation or mechanical ventilation. However, inherent complications of tracheostomy include bleeding, scarring, pneumothorax, and tracheal stenosis^{10,15}. It is important to remember that performance of tracheostomy in an infection of the deep neck space is difficult due to edema of the neck and deformation of anatomical structures¹⁵.

Deciding between intubation or performance of a tracheostomy is required for management of the airway after surgery¹⁶. Even in cases where there is

CASE REPORT

not enough edema to cause obstruction of the airway prior to performance of incision and drainage, closure of the airway may occur due to a substantial amount of edema after incision and drainage.

In this case, the lumen of the endotracheal tube was partially blocked by secretions and the patient was unable to manage the oropharyngeal secretion, indicating that the airway obstruction was in progress. In this situation, release of a cuff of the endotracheal tube and repeated oropharyngeal suction may alleviate airway obstruction. Removing the tube with the expectation of opening the airway due to the space occupied by the tube will result in death of the patient. This phenomenon is a result of post-extubation laryngeal edema. Therefore, cautious consideration of extubation is required¹⁵⁾. Reintubation in cases of severe airway edema is almost impossible, thus emergency tracheostomy is required, and if delayed, the patient will die. In the author's view, performance of a tracheostomy and surgical drainage under general anesthesia at the same time is recommended in patients with impending airway obstruction.

Medical treatment consists of fluid therapy and antibiotic therapy. Administration of empirical antibiotics is started immediately, and replacement of antibiotics is based on the results of the antibiotic sensitivity test. A penicillin derivative is an empirical antibiotic commonly used in treatment of deep infections of the neck. Clindamycin, cephalosporin, and metronidazole can be mixed with penicillin. Piperacillin/tazobactam or imipenem can be used alone in cases where polymicrobial infections are

suspected¹⁰⁾. Several studies, have reported that certain bacteria, including Staphylococcus and Streptococcus, have shown resistance to penicillin and that penicillin has not always been effective against anaerobic strains¹⁷⁾. Therefore, in selection of empirical antibiotics, broad-spectrum antibiotics such as amoxicillin clavulanic acid are recommended, and addition of metronidazole or clindamycin would be effective in counteracting anaerobic bacteria¹⁷⁾.

Surgical treatments for abscess of the peritonsillar space include needle aspiration, incision and drainage, and tonsillectomy⁵⁾. Needle aspiration can be performed without use of special equipment and with better tolerance compared with other treatments¹⁾. Aspiration can be performed with trismus, which is less painful, and can be performed repeatedly in several sites¹⁸⁾. However, drainage of pus may not be sufficient or failure might occur⁵⁾. Incision and drainage is recommended in cases where aspiration is not effective⁵⁾. There is no consensus regarding the optimal method of incision and drainage, however, intraoral performance is recommended¹⁸⁾. Drainage of the abscess was traditionally performed by application of a curved incision lateral to the superior tonsillar pole and then performing blunt dissection¹⁸⁾. Use of the transoral approach may be limited due to trismus, and insufficient drainage can lead to recurrence of the abscess of the peritonsillar space⁵⁾. Tonsillectomy can be used as a method of treatment for peritonsillar abscess. Transoral incision and drainage was performed as an initial treatment in 9.8% of patients, however, drainage of pus was insufficient, thus tonsillectomy was performed

CASE REPORT

later, and perfect drainage of pus was achieved in all cases of tonsillectomy⁵). Even though tonsillectomy is not the method used for initial treatment, consultation with the patient about tonsillectomy is necessary⁵). Tonsillectomy is highly recommended in the case of a recurrence of an abscess of the peritonsillar space, or when the abscess has not otherwise been resolved¹. However, considering the low recurrence rate of abscess of the peritonsillar space, tonsillectomy is not well indicated¹. There is a tendency to avoid tonsillectomy due to the risk of postoperative bleeding problems⁵). According to an anonymous postal survey, tonsillectomy was performed in only 1% of cases of abscess of the peritonsillar space⁵). Findings from a recent study support the effectiveness of needle aspiration and transoral incision and drainage as initial treatments and do not support routine tonsillectomy³).

Intraoral incision and drainage may be insufficient for drainage of pus, and transcervical incision and drainage may be required⁵). Transcervical approaches to an abscess of the peritonsillar space are similar to approaches to an abscess of the parapharyngeal space. Transcervical approaches include the submandibular approach and the anterior sternocleidomastoid (SCM) approach¹⁰). When using the submandibular approach, a skin incision of several centimeters parallel to the mandible is made^{3~4}) centimeters below the inferior border of the mandible. After passing through the skin, subcutaneous tissue, and platysma muscles, an incision of the superficial layer of deep fascia is made parallel to the inferior border of the mandible. Dissection is applied up-

ward and inward to reach the angle of the mandible and into the parapharyngeal space. This approach mainly involves use of a horizontal incision in the submandibular area and is mainly used when access to the carotid artery and jugular vein is not required. By contrast, the anterior SCM approach is used when access to the carotid artery and jugular vein is required. After application of a vertical incision to the front of the anterior border of the SCM at the required level between the hyoid bone and the sternum, dissection of the superficial cervical fascia is performed, and an approach to the carotid sheath is made. When access to the carotid artery and jugular vein is required, the carotid sheath is opened. Because the carotid sheath disappears in the upper part of the hyoid bone, the parapharyngeal space can be reached along the internal jugular vein without opening the carotid sheath. At this time, the surgeon can easily enter the parapharyngeal space by following the outer surface of the medial pterygoid muscle.

Deep infections of the neck caused by tonsillitis have decreased since development of antibiotics, however, those caused by dental infections are still increasing. Therefore, when evaluating patients, thorough examination for the presence of a source of dental infection is necessary¹¹). In this case, it was thought that the source of the infection was of dental origin and the patient was referred to the department of oral and maxillofacial surgery. However, the infection did not result from a dental origin but rather was a complication of tonsillitis. The patient has frequently suffered from tonsillitis since child-

CASE REPORT

hood, which might have been a cause of the abscess of the peritonsillar space.

Distinguishing between an abscess of the peritonsillar space and an abscess of the parapharyngeal space based only on clinical findings is not always possible. CT of the neck with contrast medium is an important tool for differential diagnosis, and accurate interpretation of CT is required.

The author mistook the abscess of the periton-

sillar space for an abscess of the parapharyngeal space and inappropriate surgery was performed. If proper incision and drainage and airway management had been performed, the patient would have recovered without having to experience a complicated process. A thorough analysis of CT and use of an appropriate surgical approach is required for diagnosis of a deep infection of the neck.

참고 문헌

1. Herzon FS, Martin AD. Medical and surgical treatment of peritonsillar, retropharyngeal, and parapharyngeal abscesses. *Curr Infect Dis Rep* 2006; 8:196-202.
2. Rana RS, Moonis G. Head and neck infection and inflammation. *Radiol Clin North Am* 2011; 49:165-82.
3. Johnson RF, Stewart MG, Wright CC. An evidence-based review of the treatment of peritonsillar abscess. *Otolaryngol Head Neck Surg* 2003;128: 332-343.
4. Hanna BC, McMullan, R, Gallagher, G, Hedderwick S. The epidemiology of peritonsillar abscess disease in Northern Ireland. *J Infect* 2006; 52: 247-53.
5. Hahn J, Barth I, Wigand MC, Mayer B, Hoffmann TK, Greve J. The Surgical Treatment of Peritonsillar Abscess: A Retrospective Analysis in 584 Patients. *Laryngoscope* 2021; 131:2706-2712.
6. Levitt GW. Cervical fascia and deep neck infections. *Laryngoscope* 1970; 80:409-35.
7. Schlossberg D. *Infections of the Head and Neck*. 1st ed. New York: Springer Publishing; 1987.
8. Guidera AK, Dawes PJ, Fong A, Stringer MD. Head and neck fascia and compartments: no space for spaces. *Head & Neck* 2014; 36:1058-1068.
9. Klug TE, Greve T, Hentze M. Complications of peritonsillar abscess. *Ann Clin Microbiol Antimicrob* 2020;30:19-32.
10. Osborn TM, Assael LA, Bell RB. Deep Space Neck Infection: Principles of Surgical Management. *Oral and Maxillofacial Surgery Clinics of North America* 2008;20: 353-365.
11. James RH, Elie MF. *Head, neck, and orofacial infections: An interdisciplinary approach*. 1st ed. St. Louis, Elsevier Publishing;2016.
12. Song K, Lee J, Choi SY, Choi MS. Diagnosis and Treatment of Peritonsillar Abscess with Single Enhanced Computed Tomography. *Korean J Otorhinolaryngol-Head Neck Surg* 2018; 61:99-102.
13. Capps EF, Kinsella JJ, Gupta M, Bhatki AM, Opatowsky MJ. Emergency imaging assessment of acute, nontraumatic conditions of the head and neck. *Radiographics* 2010; 30:1335-52.
14. Kimura Y, Okano T. The pharyngeal mucosal, parapharyngeal, and retropharyngeal spaces. *Oral Radiol* 2003; 19: 106-118.
15. Potter JK, Herford AS, Ellis E III. Tracheotomy versus endotracheal intubation for airway management in deep neck space infections. *J Oral Maxillofac Surg* 2002; 60:349-54.
16. Yellon RF. Infections of the fascial spaces of the head and neck in children. *Seminars in Pediatric Infectious Diseases* 1998;9:60-69.
17. Kang SH, Kim MK. Antibiotic sensitivity and resistance of bacteria from odontogenic maxillofacial abscesses. *J Korean Assoc Oral Maxillofac Surg* 2019; 45:324-331.
18. Spiers JR, Owens JJ, Woodson GE, Miller RH. Treatment of peritonsillar abscess. A prospective study of aspiration vs incision and drainage. *Arch Otolaryngol Head Neck Surg* 1987; 113:984-986.